

Epidermodysplasia verruciformis: combined treatment with acitretin and interferon alpha-2a

*Epidermodisplasia verruciforme: tratamento combinado com acitretina e interferon alfa-2a**

Cristiana Silveira Silva¹
Mario Cezar Pires³

Rodrigo de Oliveira Ramos²
José Alexandre S. Sittart⁴

Abstract: We report the result of a treatment with acitretin and alpha-2a interferon in a 16-year-old boy with epidermodysplasia verruciformis. Diagnosis was based on clinical features, histopathological examination and positivity for in situ HPV. The affection was extensive and resistant to other treatment modalities, with a high risk of development of neoplasias. Treatment with oral acitretin associated with subcutaneous recombinant interferon alpha-2a three times per week induced improvement, which was sustained for 16 months of follow-up.

Keywords: Acitretin; Epidermodysplasia verruciformis; Interferon alpha-2a

Resumo: *Comunica-se o resultado do tratamento com acitretina e interferon alfa-2a em doente de 16 anos de idade com epidermodisplasia verruciforme. O diagnóstico foi realizado mediante os achados clínico-histopatológicos e pesquisa in situ positiva para papiloma vírus humano. O quadro clínico era extenso e resistente a outros tratamentos, com risco de desenvolvimento de neoplasias. Houve melhora clínica 30 dias após o início do tratamento, mantida durante os 16 meses de seguimento.*

Palavras-chave: *Acitretina; Epidermodisplasia verruciforme; Interferon alfa-2a*

Epidermodysplasia verruciformis (EV) is a rare genodermatosis of universal distribution,¹ characterized by cutaneous infection by certain types of human papilloma virus (HPV) in particularly susceptible individuals.² Inheritance pattern is autosomal recessive, even though there are described cases of X-linked inheritance.¹ Lesions are similar to plane warts or pityriasis versicolor.^{3,5} Histopathological examination shows keratinocytes with wide and grayish cytoplasm, and picnotic nuclei.¹ There is an abnormal susceptibility to infection by various strains of HPV (5, 8, 9,

12, 14, 15, 17, 19, 20-25, 36, 47, 50), which is usually not observed in immunocompetent subjects.^{1,2} This is believed to be due to a selective inhibition of T-lymphocyte immune response when faced with HOV infection, probably because of a defect in viral antigen presentation on the surface of keratinocytes.¹

Ultraviolet light is currently considered to be the most important risk factor in the genesis of non-melanoma skin cancer,^{4,5} but HPV infection also plays a significant role in the development of these neoplasms, especially squamous cell carcinoma.^{4,7} Other

Received on Dec. 05 of 2003

Approved by the Consultative Council and accepted for publication on Dec. 01 of 2006.

* Work done at São Paulo Public Employees' State Hospital - São Paulo (SP), Brazil.

Conflict of interests: None

¹ Resident doctor at the Department of Dermatology at the São Paulo Public Employees' State Hospital - São Paulo (SP), Brazil.

² Resident doctor at the Department of Dermatology at the São Paulo Public Employees' State Hospital - São Paulo (SP), Brazil.

³ Head physician of the Sector of Diagnosis and Therapy at the Department of Dermatology at the São Paulo Public Employees' State Hospital and head of the Department of Dermatology at Padre Bento Hospital Complex at Guarulhos - São Paulo (SP), Brazil.

⁴ Head of the Department of Dermatology at the São Paulo Public Employees' State Hospital - São Paulo (SP), Brazil.

factors, such as smoking, immunosuppression and specific genetic alterations, such as in EV, potentiate HPV's oncogenic effect.⁷ Cutaneous alterations in EV have their onset during childhood,^{4,5} malignant transformation ensuing in 30% of the cases around the third and fourth decades of life, mainly in sun-exposed areas.¹ Most common tumors are squamous cell carcinomas, and less often, base cell carcinomas.^{4,5,7} These tumors tend to behave aggressively, thus surgical treatment with wide resection margins are recommended.⁷

Several therapeutic modalities have been attempted, by means of both surgical excision and chemo-cauterization,^{2,4,5} with unsatisfactory results, and oral cimetidine in the dose of 40mg/kg/dia,⁵ cidofovir (bad results)⁵ and photodynamic therapy.⁵ Photoprotection should be recommended ever since childhood, given that malignant lesions predominate in sun-exposed areas.¹

Recently, novel therapies with oral retinoids,⁸ interferons⁹ or the association of both¹⁰ have been employed with variable results. Systemic or intralesional interferon alpha-2a, in various doses (1-9 million units/day), leads to disappearing of the histological alterations found in EV, through immunomodulating, anti-viral and anti-proliferative actions.^{1,9} Most frequent side effects are low fever (78%), weakness (78%) and myalgias (65%), which disappear 12 hours after administration of the drugs. Other less frequent side effects are bone marrow suppression, neurotoxicity, alopecia, proteinuria, azotemia, cardiovascular effects, elevation of seric triglycerides and hepatic enzymes.^{9,10}

The present case is of a white 16-year-old male, with lesions on the face ever since 7 years of age, with progressive dissemination. He presented isolated or confluent keratotic papules on the trunk and limbs (Figure 1), associated with lenticular hyperchromic maculae on the face. PPD, levedurin and trichophytin tests were negatives and there were no other laboratorial alterations. His parents were first-degree cousins and there were no other cases in the family. Histopathological examination revealed blotchy hyperkeratosis, epidermal acanthosis and keratinocytes with wide, grayish nuclei and picnotic nuclei (Figure 2). Another biopsy also revealed areas of bowenoid atypia. Testing for the presence of HPV by means of in situ hybridization revealed: 1) positive wide spectrum HPV probe for types 6, 11, 16, 18, 30, 31, 33, 35, 45, 50, 51 e 52; 2) negative HPV6-11, HPV16-18 e HPV31-33 probes.

After the diagnosis of epidermodysplasia verruciformis, treatment was initiated with salicylic acid, retinoic acid, photoprotection, levamisol and Thuya CH30, with no improvement. Because of the exten-

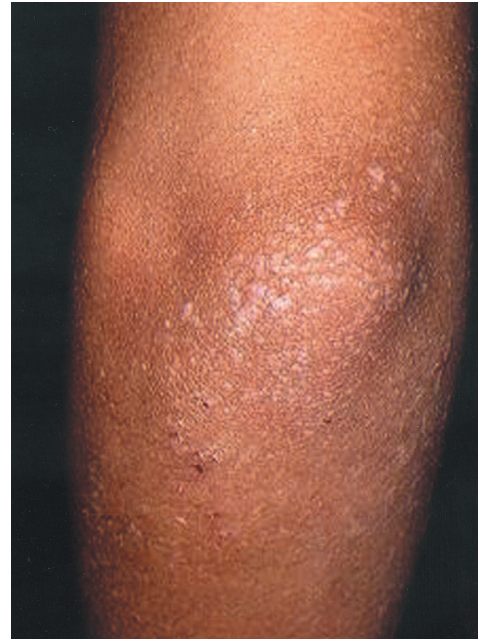

FIGURE 1: Keratotic papules on elbow

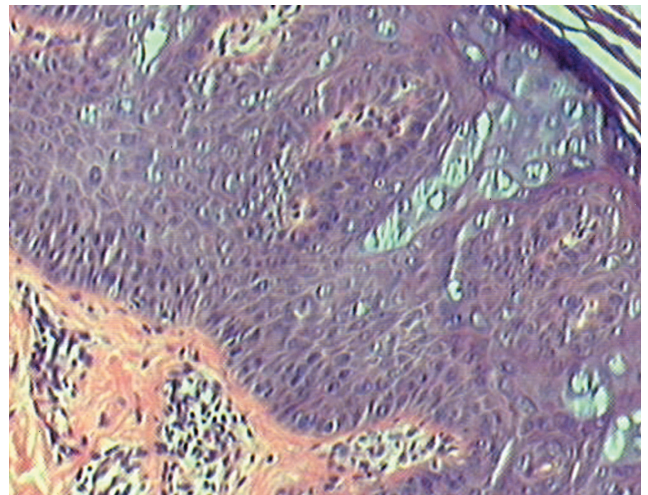


FIGURE 2: Blotchy hyperkeratosis and acanthosis, with keratinocytes with wide, grayish cytoplasm and picnotic nuclei (HE; 200x)

sion of the lesions, besides the risk of developing neoplasms, we opted for oral acitretin at 0.75mg/kg/day and interferon alpha-2a, 3,000,000IU subcutaneously, three times a week. After 30 days, over 50% of the lesions had disappeared, especially on the trunk, and of the remnant, approximately 40% diminished in thickness, with good tolerance. After six months, we observed almost full regression, thus suspended interferon alpha-2a and reduced acitretin to 0.5mg/kg/day, which is still maintained.

This patient presented all diagnostic parameters of epidermodysplasia verruciformis, and responded satisfactorily to the association of acitretin and interferon. □

REFERÊNCIAS

1. Fazel N, Wilczynski S, Lowe L, Su LD. Clinical, histopathologic and molecular aspects of cutaneous human papillomavirus infection. *Dermatol Clin.* 1999;17:521-36.
2. Brentjens M, Yeung-Yue K, Lee P, Tying S. Human papillomavirus: a review. *Dermatol Clin.* 2002;315-31.
3. Ramoz N, Rueda LA, Bouadjar B, Favre M, Orth G. A susceptibility locus for epidermodysplasia verruciformis, an abnormal predisposition to infection with the oncogenic human papillomavirus type 5, maps to chromosome 17qter in a region containing a psoriasis locus. *J Invest Dermatol.* 1999;112:259-63.
4. Sampaio SAP, Rivitti EA. Dermatoses por vírus In: Sampaio SAP, Rivitti EA. *Dermatologia.* São Paulo: Editoras Artes Médicas; 2000. p.409-30.
5. Valente NYS. Tumores malignos da pele. In: Sittart JAS, Pires MC. *Dermatologia para o clínico.* São Paulo: Lemos editorial; 1998. p.291-302.
6. Harwood CA, Proby CM. Human papillomaviruses and non-melanoma skin cancer. *Curr Opin Infect Dis.* 2002;15:101-14.
7. Lutzner MA, Blanchet-Bardon C, Orth G. Clinical observations, virologic studies, and treatment trials in patients with epidermodysplasia verruciformis, a disease induced by specific human papillomaviruses. *J Invest Dermatol.* 1984;83(Suppl):S18-25.
8. Kanerva LO, Johansson E, Niemi KM, Lauharanta J, Salo OP. Epidermodysplasia verruciformis: clinical and light- and electron-microscopic observations during etretinate therapy. *Arch Dermatol.* 1985;278:153-60.
9. Androphy EJ, Dvoretzky I, Maluish AE, Wallace HJ, Lowy DR. Response of warts in epidermodysplasia verruciformis to treatment with systemic and intralesional alpha interferon. *J Am Acad Dermatol.* 1984;11:197-202.
10. Anadolu R, Oskay T, Erdem C, Boyvat A, Terzi E, Gürgey E. Treatment of epidermodysplasia verruciformis with a combination of acitretin and interferon alfa -2a. *J Am Acad Dermatol.* 2001;45:296-9.

MAILING ADDRESS:

Dr. Mario Cezar Pires

Rua Ezequiel Freire, 35 1º andar – sala 11 –
Santana

02034-000 São Paulo – SP

E-mail: mapires@webcable.com.br