

## Small vessel vasculitis as first manifestation of paracoccidioidomycosis - Case report \*

### Vasculite de pequenos vasos como primeira manifestação clínica de paracoccidioidomicose - Relato de caso

Alessandra Cristiana de Barros Figueiredo Caldeira<sup>1</sup>  
 Taili Pedroso Lemes Pinto<sup>3</sup>  
 Cacinele Pés<sup>5</sup>

Kelly da Cas<sup>2</sup>  
 Camila Machado Zômpero<sup>4</sup>  
 Cristian Eduardo Guolo<sup>6</sup>

**Abstract:** Paracoccidioidomycosis is a systemic disease caused by inhalation of conidia of *Paracoccidioides brasiliensis*, a dimorphic fungus that initially affects the airway, spreading by lymphatic and hematogenous routes to various organs and systems, and that can be fatal if the diagnosis and treatment are not correct. The authors describe a patient who presents small vessel vasculitis as an initial manifestation of the disease, which is an atypical clinical form with a single description in the literature.

**Keywords:** Blood vessels; Paracoccidioidomycosis; Purpura; Vasculitis

**Resumo:** A paracoccidioidomicose é uma doença sistêmica causada pela inalação de conídios do *Paracoccidioides brasiliensis*, um fungo dimórfico que acomete, inicialmente, a via respiratória, disseminando-se, principalmente por vias linfáticas e hematogênicas, para diversos órgãos e sistemas, podendo ser fatal na ausência de diagnóstico e tratamento adequados. Os autores têm por objetivo relatar um caso de paciente que apresentou, como manifestação inicial da doença, uma vasculite de pequenos vasos, sendo esta uma forma clínica atípica, com uma única descrição na literatura.

**Palavras-chave:** Paracoccidioidomicose; Púrpura; Vasculite; Vasos sanguíneos

#### INTRODUCTION

Paracoccidioidomycosis, also known as South-American blastomycosis and Lutz-Splendore-Almeida disease, is a systemic infection caused by *Paracoccidioides brasiliensis*, a dimorphic fungus that especially affects men, rural workers in the 30 - 60 years of age group, with greater prevalence in Latin America. Its main source of infection is inhalation, with subsequent development of primary focus and pulmonary complex. Depending on several factors, it may disseminate to different organs and systems.<sup>1,2,3</sup>

The report below described has the objective of

demonstrating an atypical case of the disease with vasculitis of small vessels as its initial manifestation, a rare situation which has been described only once in the literature.

Vasculitis may be defined as a process of vascular inflammation immunologically mediated, that leads to functional and structural damage of the affected vessels, which may be small, medium or large. In the case of small-vessel vasculitis, there are innumerable precipitating agents, divided into infectious, food allergens, drugs and chemical products. Among the

Received on 28.07.2010.

Approved by the Advisory Board and accepted for publication on 15.09.2010.

\* Study carried out at the General University Hospital, Cuiabá University (Hospital Geral Universitário – Universidade de Cuiabá - HGU – UNIC) – Cuiabá (MT), Brazil.

Conflict of interest: None / *Conflito de interesse: Nenhum*

Financial funding: None / *Suporte financeiro: Nenhum*

<sup>1</sup> Professor at the Dermatology Outpatient Clinic of the General University Hospital, Cuiabá University (Hospital Geral Universitário – Universidade de Cuiabá - HGU – UNIC) – Cuiabá (MT), Brazil.

<sup>2</sup> Physician of the Family Health Unit of the city of Curvelândia – Curvelândia (MT), Brazil.

<sup>3</sup> Medical student of the Medical School of Cuiabá University (Faculdade de Medicina da Universidade de Cuiabá - UNIC) – Cuiabá (MT), Brazil.

<sup>4</sup> Physician at Outpatient Medical Care – Pediatrics of Santa Marcelina Hospital (Assistência Médica Ambulatorial – A.M.A, Pediatria do Hospital Santa Marcelina – São Paulo (SP), Brazil

<sup>5</sup> Physician rendering services to Brasil Foods and Serviço Social da Indústria (SESI) – Cuiabá (MT), Brazil.

<sup>6</sup> Physician - General practitioner at the State Hospital of Sapopemba (Hospital Estadual Sapopemba - HESAP) – São Paulo (SP), Brazil.

infectious agents, the *Paracoccidioides brasiliensis* is not usually mentioned in the usual literature and it is necessary to be aware of this correlation for adequate diagnosis and treatment.<sup>4</sup>

### CASE REPORT

An 82-year-old male patient, white, born in Uberaba-MG, coming from Cuiabá-MT, rural worker, with systemic hypertension for many years and chronic smoking habit (70 packs/year). His monitoring at the dermatology outpatient clinic had begun two years and six months before and he complained that one year ago there was onset of erythematous desquamative plaques on both legs, which progressed after one month to erythematous-infiltrative plaques with hypochromic center, well-marked borders and a geographical aspect. The lesions became purpuric and painful, spreading to the entire extension of the lower limbs. During the evaluation of body systems the patient confirmed history of weight loss of seven kilograms in the last six months, without other complaints, such as cough, dyspnea, chest and/or abdominal pain.

The dermatological examination showed purpuric lesions on the entire extension of lower limbs, in addition to erythematous desquamative plaque on the right buttock and an ulcer of 7cm diameter and granulomatous base on the dorsum of left foot, surrounded by edema. The physical examination of other systems did not show alterations.

The laboratory tests requested revealed moderate leukocytosis (13800/mm<sup>3</sup>), 690 rods/mm<sup>3</sup> and 1104 eosinophiles/mm<sup>3</sup>, as well as thrombocytosis (621000 platelets/mm<sup>3</sup>) and ESR (erythrocyte sedimentation rate) of 84mm/h, without alteration of other parameters.

A biopsy of the lesion was requested, which revealed fungal structures typical of *Paracoccidioides brasiliensis*, well-defined in PAS staining with amylase and Methanamine-Silver (Figure 1). It also revealed epidermal necrosis with ulcerations, necrotizing granulomatous arteritis, characteristics that should be related to vasculitis resulting from Paracoccidioidomycosis. Hematoxylin-eosin staining showed a chronic, granulomatous perivascular inflammatory process with vasculitis, in addition to thrombosed arteriole with image suggestive of *paracoccidioides brasiliensis* in its interior (Figures 2 and 3).

After histopathological diagnosis, the patient was referred to the infectology service where chest X-ray and spirometry were carried out to investigate possible pulmonary involvement. Spirometry presented marked obstructive ventilatory disorder with reduction of vital capacity, while the X-ray revealed presence of bilateral and symmetrical perihilar inters-

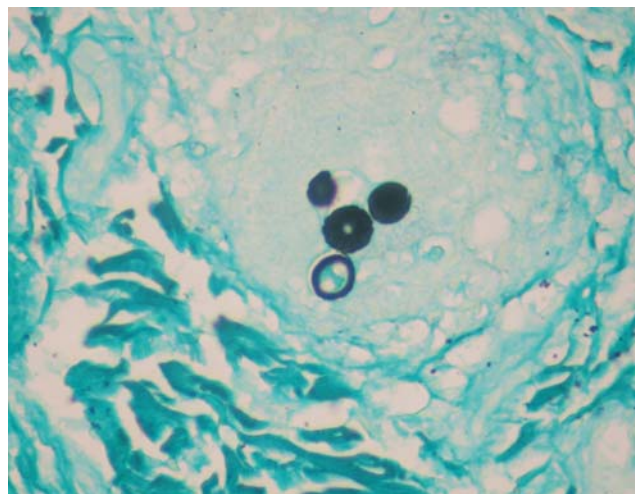


FIGURE 1: Histopathological finding in affected area of left leg (PAS with amylase and Methanamine-Silver) – Epidermal necrosis with ulceration, necrotizing and granulomatous arteritis

titial infiltrate (with aspect of “butterfly wings”), both compatible with progression of the diagnosis described above. In order to evaluate other organs, computerized tomographies of the abdomen and head were performed, both with results within normal limits. According to information received from the service, no serological tests were carried out.

Treatment with itraconazole (200mg/day) was prescribed and in the two weeks following the start of medication use the patient presented ulceration of purpuric lesions, which progressed to necrosis of the first three left toes (Figure 4). Our option then was to start systemic corticosteroid therapy to resolve the ulcers and proceed with amputation of the affected foot. The patient continued the treatment with anti-fungal for 24 months, maintaining the initial dose, and had complete improvement of the clinical picture. Postinflammatory hyperpigmentation was the only symptom remaining at the lesion sites, without alterations in laboratory or image exams (Figure 5).

### DISCUSSION

Paracoccidioidomycosis, a systemic mycosis caused by the dimorphic fungus *Paracoccidioides brasiliensis*, is considered one of the main fungal infections of Latin America, with Brazil as an endemic disease center with greater prevalence in the southeast, center-west and south regions.<sup>1,2,3</sup>

It is also known as South-American blastomycosis or Lutz-Splendore-Almeida disease<sup>3</sup>, having received the name of paracoccidioidomycosis in 1971 at the meeting of mycologists of the Americas in Medellin (Colombia), which was officialized by the World Health Organization.<sup>1,2,3</sup>

The infection seems to affect a great part of the

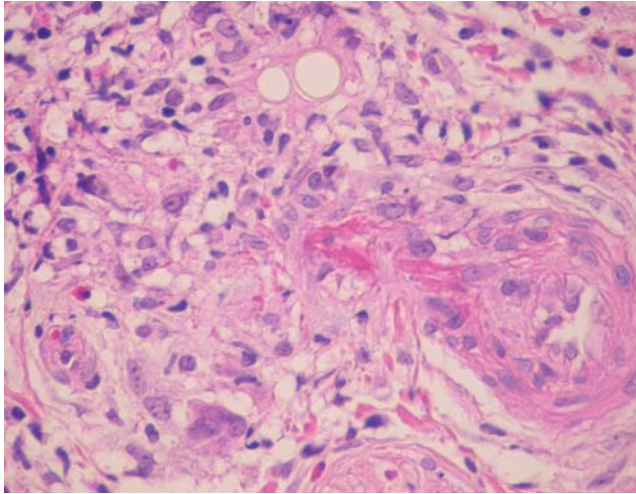


FIGURE 2: H-E: Chronic inflammatory and granulomatous perivascular process with vasculitis

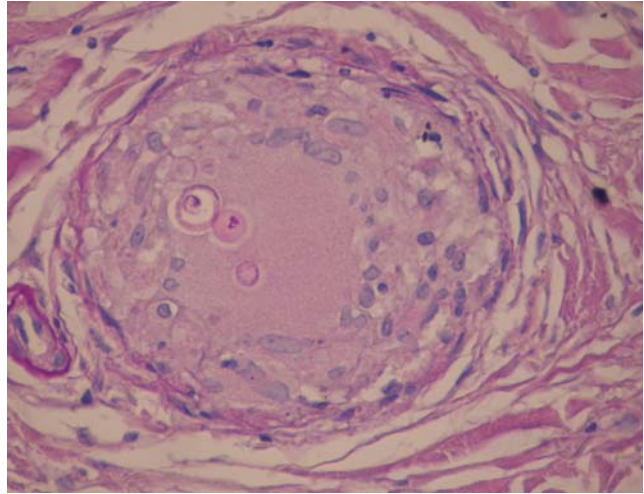


FIGURE 3: H-E: Thrombosed arteriole with image suggestive of *paracoccidioides brasiliensis* in its interior

Brazilian population between 10 and 20 years of age, although it is manifested as disease in a small number, especially men, rural workers, making use of alcohol and tobacco, in the 30 to 60-year-old age range.<sup>2,3</sup>

The transmission happens by inhalation of *Paracoccidioides brasiliensis* conidia, which reach the pulmonary alveoli and are transformed into yeast-like cells<sup>3</sup>. There are reports of infection through intradermal, mucosae or via gastrointestinal tract inoculation, although they seem to be self-resolving, as the fungus does not complete the pulmonary cycle. When it reaches the pulmonary tissue there is focus and primary complex formation, from which the following progressions may occur: (1) development of competent cellular immunity and resolution of the primary complex; (2) transitory lymph-hematogenic dissemination, with the onset of new foci in several organs, that undergo resolution; and, (3) acute evolution to disease. Among the mentioned forms, the most common is for the primary complex to be installed in asymptomatic or oligosymptomatic form.<sup>1</sup>

In case of reactivation of the initial focus, whether by unbalance of the relationship between agent and host (endogenous reinfection) or reexposure to the source of contagion (exogenous reinfection), the clinically manifested disease is installed.<sup>1</sup>

Of the manifestations mentioned above, the chronic form is the most prevalent, affecting around 85.1% of the patients with paracoccidioidomycosis disease. It is called unifocal when it predominates a single organ, with the isolated lung disease as the most common. It may also be isolated cutaneous, with the onset of sarcoid or of hansenoid-like lesions, or isolated to the CNS, manifesting as center encephalic or bone marrow processes. As regards the multifocal chronic form, there is joint affection of several organs

and systems, among them lungs, lymph nodes, skin, mucosae, upper respiratory tract, adrenal glands, bones and CNS. Paracoccidioidomycotic granulomas may be seen also in the liver, spleen, bowels, eyes, peritoneum, pancreas, ovaries, uterus and thyroid, among others. Sites that are less commonly described, but also affected, are large, medium and small blood vessels.

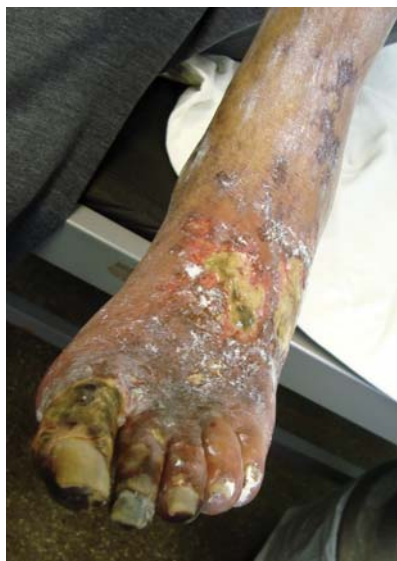In 1940, in Venezuela, Guerra reported the first case of arterial lesion affecting the aorta and superior mesenteric.<sup>5</sup> Ângulo-Ortega, in 1948; Benaim Pinto, in 1950; Brass, in 1969; Robledo, in 1972 and 1975; and Gonçalves, in 1977, are other authors that reported new cases of blastomycotic aortitis.<sup>6-10</sup>

Mendes and cols., in 1980, reported a case of patient with paracoccidioidomycosis who died as a result of acute renal insufficiency. The autopsy revealed renal vascular disease by polyarteritis nodosa, a vasculitis of medium vessels, suggesting its possible correlation with the basic disease, although without confirmation.<sup>11</sup>

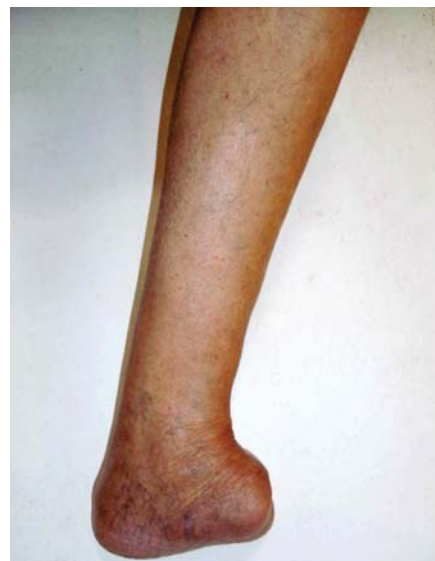In 1985, Martinez and cols. Reported the first case of arterial lesion in small vessels by *Paracoccidioides brasiliensis*.<sup>5</sup>

The illness diagnosis may be made with detection of the etiological agent through fresh material, biopsy or histopathological exams; isolation and culture of material; and serological techniques, more utilized in therapeutic and post-therapeutic follow-up. Concerning the treatment, it is divided into one attack phase and one maintenance phase; the most effective drugs are amphotericin B, sulfadiazine and other sulfanilamide compounds, as well as the azole derivatives, with greater emphasis on ketoconazol, fluconazole and itraconazole.<sup>2</sup>

In the case reported, the authors describe a rare



**FIGURE 4:** Presence of vasculitis in left leg of patient associated with ulceration on the dorsum of foot and necrosis on the three first left toes



**FIGURE 5:** Image of left leg and foot of patient after amputation and treatment of paracoccidioidomycosis

and little known manifestation of paracoccidioidomycosis, a vasculitis of small vessels; as already mentioned it is an immunologically mediated inflammation of blood vessels.<sup>4</sup> It may be primary (idiopathic), or, as commonly observed in medical practice, secondary to several systemic pathologies, such as infections, collagenoses, hypersensitivity to drugs and neoplasias. When it is vasculitis of small vessels, despite the several associated and/or triggering factors already described, the etiology remains unknown in around 60% of patients.<sup>11</sup>

The patient presents characteristics of both illnesses; the *Paracoccidioides brasiliensis* infection was not researched at first because there is little infor-

mation on this association, which was only investigated after biopsy of skin lesion compromised by vasculitis detected the fungus. It should be emphasized that the manifestation described may be the reactivation of a latent focus or even a reinfection, as the fact that the first presentation of the disease occurred at 82 years of age is uncommon.

It is evident, therefore, the relevance of reporting the second case of paracoccidioidomycosis manifested as small vessel vasculitis described in the literature, a fact that should be remembered not only in the clinical investigation of the disease, but also in the research of possible causes for a vasculitis, a pathology of usually obscure etiology. □

## REFERENCES

1. Marques SA. Paracoccidioidomycose. An Bras Dermatol. 1998;73:455-69.
2. Palmeiro M, Cherubini K, Yurgel LS. Paracoccidioidomycose - Revisão de literatura. Scientia Medica. Porto Alegre. 2005;15:274-8.
3. Martinez R, Ferreira MS, Filho FQT, Mendes RP, Borges AS, Negro GBD, et al. Paracoccidioidomycose (Blastomycose Sul-Americana). In: Veronesi R, Focaccia R, editores. Tratado de infectologia. 3 ed., 2 v. São Paulo: Atheneu; 2005. p. 1371-401.
4. Brandt HRC, Arnone M, Valente NYS, Criado PR, Sotto MN. Vasculite cutânea de pequenos vasos: etiologia, patogênese, classificação e critérios diagnósticos- Parte I. An Bras Dermatol. 2007;82:387-406.
5. Martinez JE, Atra E, Cunha MFL, Pereira CAP, Sato EI. Blastomycose sul-americana com vasculite: relato de caso. Rev Bras de Reumatol. 1985;25: 211-3.
6. Angulo-Ortega A. La Paracoccidioidomycosis en el Servicio de Anatomia Patológica del Hospital Vargas de Peracas. Revista Sudamer. 1948;6:145-55.
7. Pinto HB. Contribucion al estudio de la paracoccidioidomycosis em Venezuela. Notas clinicas y terapeuticas con presentacion de 7 casos. Arch Venez Patol Trop. 1950;2:183-222.
8. Brass K. Observaciones sobre la anatomia patológica, patogênese y evolucion de paracoccidioidomycosis. Mycopathologia. 1969;37:117-138.
9. Robledo VM. Disseminated paracoccidioidomycosis with arteritis. In: Pan-American Symposium on Paracoccidioidomycosis, I, Medellin, 1971. Proceedings, Washington, PAHO, 1972. Scient Publ. n 254.
10. Gonçalves AJR. Aneurisma blastomicótico da aorta abdominal: relato de um caso e revisão de literatura. Rev Med Hosp Serv Est. 1977; 29:167-72.
11. Mendes VLN, Cordeiro SL, Filho AA, Campos EP, Franco MF. Poliarterite nodosa com insuficiência renal crônica em paciente com paracoccidioidomycose. Rev Hosp Clin Fac Med S Paulo. 1980;35:35-9.

---

**MAILING ADDRESS / ENDEREÇO PARA CORRESPONDÊNCIA:**

**Alessandra Cristiana de Barros Figueiredo  
Caldeira**

**Rua das Imbuías, 322. Alphaville**

**Cep: 78061-314 - Cuiabá - MT, Brazil**

**E-mail: alecal@terra.com.br**

How to cite this article/*Como citar este artigo*: Caldeira ACBF, Cas K, Pinto TPL, Zômpero CM, Pés C, Guolo CE. Small vessel vasculitis as first manifestation of paracoccidioidomycosis - Case report. An Bras Dermatol. 2011;86(6):1208-12.