

# Infections caused by dematiaceous fungi and their anatomoclinical correlations

Infecções causadas por fungos demácios e suas correlações anátomo-clínicas

Camila de Camargo Hoffmann<sup>1</sup>  
Katia Sheylla Malta Purim<sup>3</sup>

Itamara Pereira Danucalov<sup>2</sup>  
Flavio Queiroz-Telles<sup>4</sup>

**Abstract:** The *Exophiala* genus comprises dimorphic melanized fungi responsible for a spectrum of diseases including phaeohyphomycosis, mycetoma, chromoblastomycosis and fungemia. The *E. jeanselmei* species is predominant in such infections, followed by *E. dermatitidis*. This paper aims at reporting four cases and at discussing clinical, histological, mycological and epidemiological aspects for its diagnosis.

**Keywords:** *Exophiala*; Chromoblastomycosis; Fungi

**Resumo:** O gênero *Exophiala* é composto por fungos melanizados dimórficos, responsáveis por um espectro de doenças, incluindo feohifomicoses, micetomas, cromoblastomicoses e fungemia. A espécie *E. jeanselmei* é a predominante nestas infecções, seguida de *E. dermatitidis*. Este trabalho tem como objetivo relatar quatro casos e discutir aspectos clínicos, histológicos, micológicos e epidemiológicos para o seu diagnóstico.

**Palavras-chave:** Fungos; Cromoblastomicose; *Exophiala*

## INTRODUCTION

Dematiaceous fungi are found in nature and one of their characteristics is the presence of melanin, responsible for the dark pigmentation of their spores and conidia and that seems to behave as a virulence factor. More than a hundred species and sixty genera of these fungi are connected to a broad spectrum of human infections.<sup>1</sup> The main clinical forms of presentation of the infections through these dematiaceous fungi include phaeohyphomycoses (cutaneous, subcutaneous and systemic), that affect both immunocompetent and immuno-compromised individuals; chromoblastomycosis, mycetoma, sinusitis and bloodstream infections. Among these, chromoblastomycosis and mycetoma are considered occupational diseases.

Clinicopathological studies involving dematiaceous fungi are scarce in medical literature. The recent contributions from Molecular Biology revolutionized the taxonomy of these agents leading to a revision of past diagnosed cases and improving the perspective of present and future diagnoses.<sup>3</sup>

The authors of this study present four cases of infections caused by species from the genus *Exophiala*, all of them in farmers from the interior of the state of Paraná, addressing the different clinical, therapeutic and epidemiological aspects as well as the laboratory tests related to these infections

## CASE REPORTS

**CASE 1** – Male patient, aged 36, Caucasian, with a nodule-cystic lesion well defined, without inflammatory signs, measuring 4,5 cm of diameter in the cavum of the left foot which had started 6 months before with no apparent connection with trauma. He had undergone a renal transplant 4.5 years ago and is currently using prednisone - 15mg /day, cyclosporine-350mg/day and azathioprine - 75mg/day. The aspiration of the lesion, of chocolate like staining, presented, when directly examined, pigmented fungal elements: septate hyphae, catenulate and vesicular elements.

Received on 15.09.2009.

Approved by the Advisory Board and accepted for publication on 21.12.10.

<sup>1</sup> Work conducted at Infectology Service from the University Hospital of the Federal University of Paraná - Curitiba (PR), Brasil.

Conflict of interest: None / *Conflito de interesse: Nenhum*

Financial funding: None / *Suporte financeiro: Nenhum*

<sup>1</sup> Medical doctor graduated from the Federal University of Paraná - Curitiba (PR), Brasil.

<sup>2</sup> Medical doctor graduated from the Federal University of Paraná – Internal Medicine resident at the University Hospital from the Federal University of Paraná - Curitiba (PR), Brasil.

<sup>3</sup> PhD in Internal Medicine from the Federal University of Paraná – Doctor from the ambulatory of Dermatology from the University Hospital of the Federal University of Paraná - Curitiba (PR), Brasil.

<sup>4</sup> PhD in Infectious and Parasitic Diseases from the University of São Paulo (USP) – Assistant Professor of Infectology from the Federal University of Paraná - Curitiba (PR), Brasil.

©2011 by Anais Brasileiros de Dermatologia

The patient had a surgical excision of the cystic lesion that was unilocular, with a thick and fibrotic wall, needing a skin graft in the area. The cultivation of secretion originated dematiaceous colonies identified as *Exophiala jeanselmei* species *jeanselmei*. The electron microscopy of transmission revealed the presence of great quantities of polymorphonuclear hyphae at different stages of digestion. The electron microscopic scanning of fungus revealed a conidiogenous annelid characteristic of the genus *Exophiala* (Picture 1). It progressed without recurrence of the lesion.

CASE 2 – Thirty-eight year-old patient, Caucasian, presenting erythematous desquamative plaque and cicatricial lesions on the buttocks which had begun 15 years before and the patient was complaining of pruritus and local pain (Picture 2). For 2 years he underwent two treatments with amphotericin B, with partial response. Histopathological examination showed muriform cells and microabscesses (Picture 3). It was observed the growth of *Exophiala jeanselmei* in the culture of the lesion. It was suggested treatment with itraconazole but we could not track the patient any further.

CASE 3 – Fifty-nine year-old patient, Caucasian, presenting erythematous desquamative plaque of circinate edges and cicatricial lesions on the lower part of the left leg and foot for 10 years, with pruritus and local pain. This lesion started on the calf after a trauma with fracture of the bone. Skin biopsy revealed muriform cells and granulomatous reaction. It was observed growth of *Exophiala sp* in the tissue culture. The patient was treated with itraconazole 400mg/ day for 14 months and there was clinical and mycological cure.

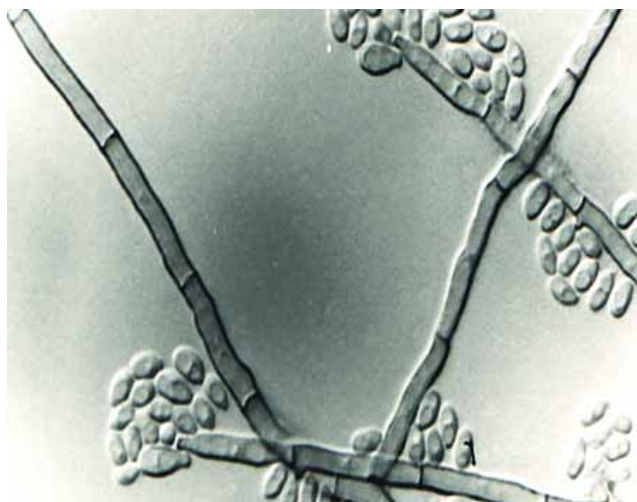


FIGURE 1: Micromorphology of *Exophiala jeanselmei* during the yeast and mycelial phases. It is observed that the unicellular annelid conidia accumulate themselves in the apex of elongated annelids and with terminal or intercalate formation

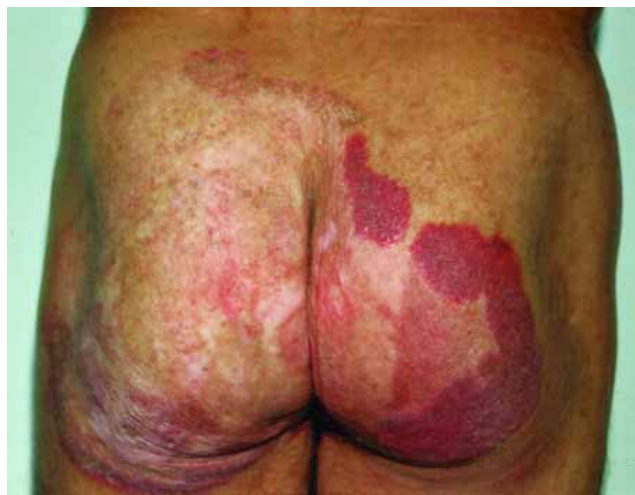

FIGURE 2: Lesions of this type erythematous desquamative and cicatricial type on the buttocks of a patient with chromoblastomycosis

CASE 4 – Forty-nine year-old patient, African-Brazilian, presenting edemato-fistulous lesions at his left foot with drainage of black grains and serous secretion (Picture 4). He complained of pruritus and articular pain when walking. The condition had started 33 years before on the toe after a transcutaneous trauma while tilling. For 20 years he was treated with sulfonamides, penicillin and ketoconazole without response. Radiological and functional assessments showed loss of the mobility of the foot; bone and joint lesions extending to tibial diaphysis. The patient underwent amputation of the leg followed by 1 gram of intravenous amphotericin B. Pathology revealed swollen and distorted foot with multiple fistulas transmitting to deep tissue, affecting the bones it also

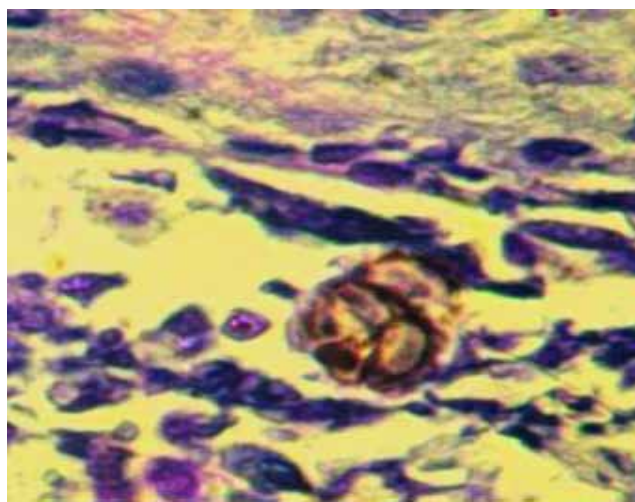


FIGURE 3: Skin biopsy showing typical muriforme cell (sclerotic body) in the midst of a microabscess. PAS x 1000

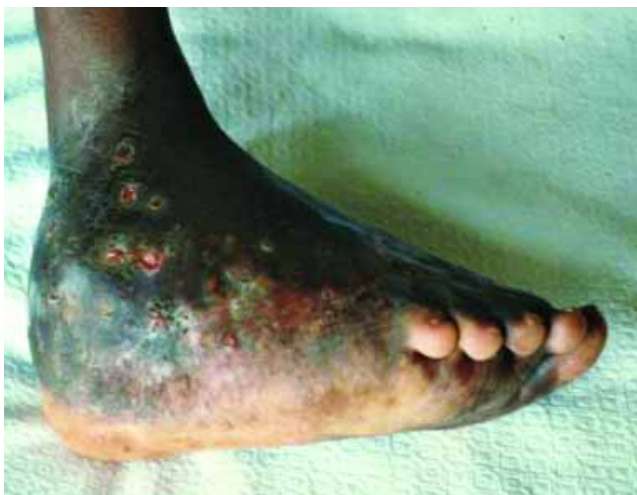

FIGURE 4: Mycetoma after 33 years of evolution. It is observed fistulas and the characteristic swelling

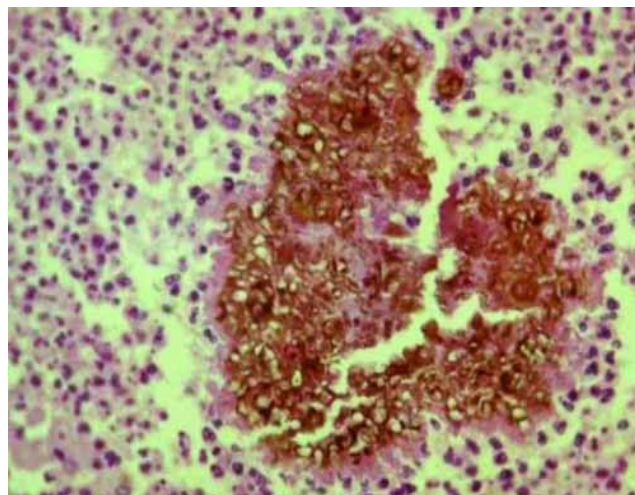


FIGURE 5: Optical microscopy shows mycetomas with the characteristic grain formation, as seen above.. (HE x 400)

showed granules composed of brown aggregates of swollen cells and rare hyphae, with  $80\ \mu\text{m}$ , without intercellular substance. Around the grains there was a granulomatous tissue with multinucleate histiocytes and neutrophilic exudate (Picture 5). Direct microscopy showed grains presenting smooth texture with characteristics similar to the fixed material. In the Sabouraud's dextrose agar medium the grains collected from the surgical specimen gave growth to black colonies that later were covered with gray mycelium. The fungus was identified as *Exophiala jeanselmei*.

## DISCUSSION

Infections caused by dematiaceous fungi have a great variety of clinical manifestations, represented clinically on the skin as phaeohyphomycosis, chromoblastomycosis and eumycotic mycetoma. Allergic diseases may occur such as fungal sinusitis apart from pneumonia and lung abscess.<sup>1</sup> The disease tends to be systemic<sup>2</sup> in immuno-compromised patients, mainly with cellular immunodeficiency.

The genus *Exophiala* is composed of dimorphic fungi. The yeast colonies are of brown or black color and dry aspect<sup>4</sup>. Optical microscopy showed dark yeast cells, septate and branched hyphae or hyphae formed by chains of spherical cells (moniliform or muriform hyphae) with abundant buds and annelid conidiogenesis, unicellular, rarely septate, hyaline or dark.<sup>5</sup>

The cases reported are cases of chronic fungal diseases with prolonged evolution and incubation period, prevalent in men around 30-40 years of age<sup>7</sup>. They were farmers that presented risk factors for the traumatic inoculation of these fungi. The immunosuppression condition verified in one of them that develops fungal infection and its occurrence is increasing

due to a increasing population of patients with secondary immune deficiency.<sup>2</sup> These epidemiological data are in accordance with the medical literature. The clinical presentation of the disease, in our patients, was classic and considered as: a nodule-cystic lesion without signs of inflammation in phaeohyphomycosis<sup>5</sup> (Case 1), plaques in chromoblastomycosis<sup>6</sup> (cases 2 and 3) and fistulas with grain drainage in eumycetoma (Case 4).<sup>8</sup>

Case 1 reports a post renal transplantation patient using immunosuppressive drugs who developed phaeohyphomycosis. Sabbaga *et al* describe four patients who had had a renal transplantation and developed phaeohyphomycosis caused by *Exophiala jeanselmei* and who had had good results after surgical excision, as our patient.<sup>9</sup> Silva *et al* present a similar case also caused by *E. jeanselmei*: a patient after cardiac transplantation with similar results.<sup>10</sup>

Cases 2 and 3 portray the classic patients affected by chromoblastomycosis, farmers, presenting chronic lesions on the limbs<sup>11</sup>, with a history of previous trauma in one of the cases.<sup>12</sup>

Case 4 is a characteristic case of a eumycetoma infection, a patient from the countryside that after transcutaneous trauma developed fistulae formation with grains drainage. Bone invasion suggests an advanced disease, refractory to inadequate therapeutics that had been used for 20 years, progressing to limb amputation.<sup>8</sup>

The final diagnosis of the diseases caused by any of the species of cutaneous and subcutaneous fungi should be made through culture of the biopsied materials.<sup>1</sup> These procedures, carried out in our patients, confirmed the diagnosis with the development of the *Exophiala* fungus. This microorganism, usually of low virulence, presents itself clinically and

of importance when the host is exposed to its risk factor, in the cases described, the inoculation and the immunosuppression. Three patients had results of culture with *Exophiala jeanselmei*, while the fourth had *Exophiala sp.*, coinciding with the literature that cites *Exophiala jeanselmei* as the dominant species followed by *E. dermatitidis*.<sup>5</sup>

Subjects in the treatment which was carried out was consistent with other authors. As for phaeohyphomycosis, surgical excision is the most frequent procedure and it was carried out with success, without evidence of recurrence.<sup>6</sup> As for chromoblastomycosis, in the third case was treated with itraconazole, drug from the group of azoles that *in vitro* proved to have excellent activity against dematiaceous<sup>1</sup>. this being one of the drugs of choice for the treatment of this type of infection. The patient with mycetoma underwent a left lower limb amputation due to the refractoriness of the case to the medications used, a common fact concerning mycetomas.

The analysis of these cases shows us that the clinical aspect of the infections caused by dematiaceous, in special from the *Exophiala* genus, is broad and requires different procedures. The members of this genus is present *in vitro* and has a high degree of phenotypic plasticity as the fragment of tissue from skin lesions is rarely cultivated.

Early diagnosis is primordial despite the chronicity and long evolution of these diseases. Its infiltrative feature is capable of leading to sequelae and amputations. There is no consensus yet regarding the treatment of subcutaneous fungal diseases and there are few clinical trials comparing different drugs. On the other hand, research indicates practicality in the *in vitro* susceptibility test of each causal agent with certain drugs<sup>13</sup> that would provide a more targeted and effective treatment. It is noteworthy that educational measures in health are important to minimize the damage and injuries of such infections. □

## REFERENCES

1. Revankar SG. Dematiaceous fungi. *Mycoses*. 2007; 50:91-101.
2. Silveira F, Nucci M. Emergence of Black moulds in fungal disease: epidemiology and therapy. *Curr Opin Infect Dis*. 2001; 14(6):679-84.
3. Zeng JS, Sutton DA, Fothergill AW, Rinaldi MG, Harrak MJ, de Hoog GS. Spectrum of clinically relevant *Exophiala* species in the united states. *J Clin Microbiol*. 2007; 45(11):3713-20.
4. Ajello, L. The Black yeast as disease agents: historical perspective. *Pan Am Health Organ Science Publ* 1978; 356: 9-19.
5. Garcia-Martos P, Márquez A, Gene J. Infecciones humanas por levaduras negras Del género *Exophiala*. *Rev Iberoam Micol*. 2002; 19:72-79.
6. Pang KR, Wu JJ, Huang DB, Tying SK. Subcutaneous fungal infections. *Dermatologic Therapy*. 2004; 17: 523-31.
7. Rossetto AL, Dellatorre G, Pérsio RA, Romeiro JC, Cruz RC, Subcutaneous phaeohyphomycosis on the scrotum caused by *Exophiala jeanselmei*: case report. *An Bras Dermatol*. 2010; 85:517-20.
8. Welsh O, Vera-Cabrera L, Salinas-Carmona M.C. Mycetoma. *Clin Dermatol*. 2007; 25:195-202.
9. Sabbaga E, Tedesco-Marchesi LM, Lacaz CS, Cucê LC, Salebian A, Iieins-Vaccari EM et al. Feohifomicose subcutânea por *Exophiala jeanselmei*. Registro de três casos em transplantados renais. *Rev Inst Med Trop São Paulo*. 1994; 36 (2):175-83.
10. Silva Mdo R, Fernandes Ode F, Costa CR, Chaul a, Morgado Lf, Fleury-Junior Lf, et al. Subcutaneous phaeohyphomycosis by *Exophiala jeanselmei* in a cardiac transplant recipient. *Rev Inst Med Trop Sao Paulo*.2005;47(1):55-7.
11. Queiroz-Telles F, Esterre P, Perez-Blanco M, Vitale RG, Salgado CG, Bonifaz A. Chromoblastomycosis: an overview of clinical manifestations, diagnosis and treatment. *Med Mycol*. 2009; 47(1):3-15.
12. Queiroz-Telles F, McGinnis MR, Salkin I, Graybill jr et al. Subcutaneous mycoses. *Infect Dis Clin N Am*. 2003; 17:59-85.
13. Vivas JRC, Torres-Rodríguez JÁ. Sensibilidad de hongos miceliares dematiáceos a diez antifúngicos empleando um método de difusión em Agar. *Rev Iberoam Micol*. 2001; 18:113-17.

MAILING ADDRESS / ENDEREÇO PARA CORRESPONDÊNCIA:

**Flavio de Queiroz-Telles Filho**  
 Av. General Carneiro, 181, Alto da Glória,  
 80060-900, Curitiba, PR, Brazil  
 e-mail: camiladech@yahoo.com.br

How to cite this article/Como citar este artigo: Hoffmann CC, Danucalov IP, Purim KSM, Queiroz-Telles F. Infections caused by dematiaceous fungi and their anatomoclinical correlations . *An Bras Dermatol*. 2011;86(1):138-41.