

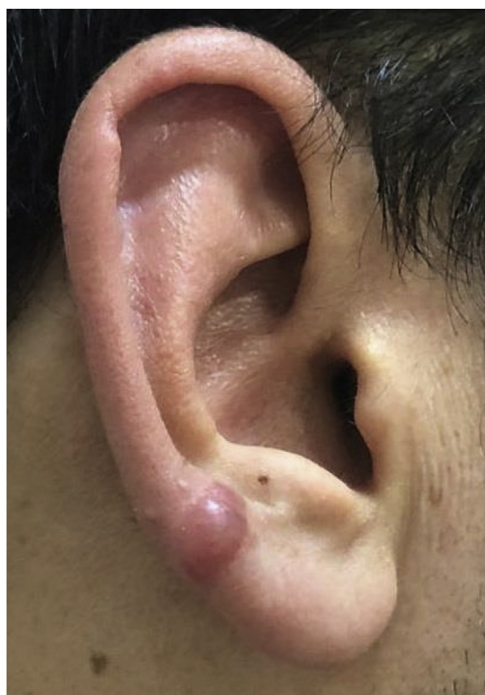

Figure 2 Keloid formation following piercing through the transitional zone in patient 3.

Financial support

This research did not receive any specific grant from funding agencies in the public, commercial, or not-for-profit sectors.

Author's contribution


All authors (Ozge Zorlu, Serkan Yazici, Şaduman Balaban Adım) have been actively involved in study conception and planning, critical literature review, data collection, analysis and interpretation, research orientation, preparation and writing of the manuscript, and review of the manuscript. All authors read and approved the final version of the manuscript.

Conflicts of interest

None declared.

References

1. Simplot TC, Hoffman HT. Comparison between cartilage and soft tissue ear piercing complications. *Am J Otolaryngol.* 1998;19:305–10.
2. Hochman B, Isoldi FC, Silveira TS, Borba GC, Ferreira LM. Does ear keloid formation depend on the type of earrings or piercing jewellery? *Australas J Dermatol.* 2015;56:e77–9.
3. Inui S, Shono F, Nakajima T, Hosokawa K, Itami S. Identification and characterization of cartilage oligomeric matrix protein as a novel pathogenic factor in keloids. *Am J Pathol.* 2011;179:1951–60.
4. Hosalkar H, Greenberg J, Gaugler RL, Garg S, Dormans JP. Abnormal scarring with keloid formation after osteochondroma excision in children with multiple hereditary exostoses. *J Pediatr Orthop.* 2007;27:333–7.
5. Fijałkowska M, Kasielska A, Antoszewski B. Variety of complications after auricle piercing. *Int J Dermatol.* 2014;53:952–5.

Ozge Zorlu ^{a,*}, Serkan Yazici ^a, Şaduman Balaban Adım ^b

^a Department of Dermatology and Venereology, Bursa Uludağ University School of Medicine, Bursa, Turkey

^b Department of Pathology, Bursa Uludağ University School of Medicine, Bursa, Turkey

* Corresponding author.

E-mail: zorluz@gmail.com (O. Zorlu).

Received 22 July 2021; accepted 6 August 2021;
Available online 28 March 2023

<https://doi.org/10.1016/j.abd.2021.08.016>

0365-0596/ © 2023 Sociedade Brasileira de Dermatologia.

Published by Elsevier España, S.L.U. This is an open access article under the CC BY license (<http://creativecommons.org/licenses/by/4.0/>).

Pemphigus vulgaris associated with nasoseptal perforation, ocular conjunctival herpes infection and milia formation[☆]

Dear Editor,

We report a 60-year-old woman who was diagnosed with pemphigus vulgaris (PV) associated with uncommon pre-



sentations, i.e., nasal mucosal involvement with septal perforation, ocular conjunctival involvement of herpes simplex virus (HSV) infection, and milia on the re-epithelialized skin. We will discuss each association based on the results of our laboratory examinations.

Clinical examination revealed erosive skin lesions mainly on the face, trunk, and limbs, as well as mucosal lesions on the tongue, gingivae, and palate (Fig. 1A), and hyperemia on the left conjunctiva. Erosions and crusts in the nasal mucosa, and anterior nasoseptal perforation were also detected. Additionally, milia were observed on the skin of the face and shoulders, which were previously affected by PV (Fig. 1B).

Histopathology showed suprabasal acantholysis for biopsies taken from the chest and from the nasal septum (Fig. 2A). IgG deposition on keratinocyte cell surfaces

[☆] Study conducted at the Laboratory of Dermatology, University Hospital, Ribeirão Preto Medical School, University of São Paulo, Brazil, and at the Department of Dermatology, Kurume University School of Medicine, and Kurume University Institute of Cutaneous Cell Biology, Fukuoka, Japan.

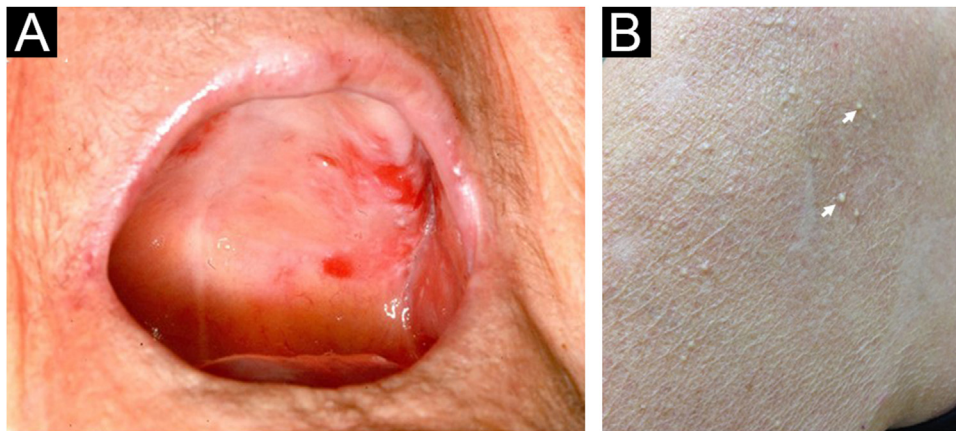


Figure 1 Clinical features of the present case. (A) Erosions on the soft and hard palate. (B) Milia seen over previously erosive PV lesions on the shoulder (arrows).

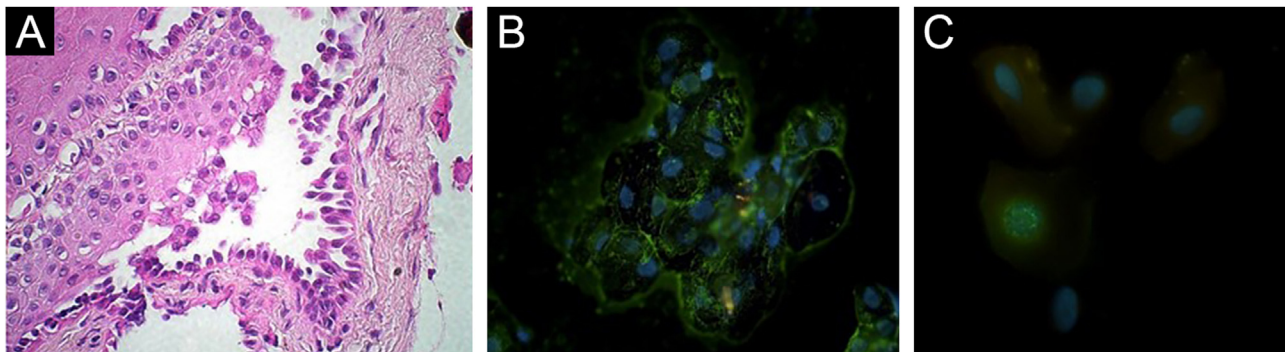


Figure 2 Histopathological and immunofluorescence findings. (A) Suprabasal acantholysis in biopsy taken from nasal mucosa (Hematoxylin & eosin, $\times 63$). (B) Positive reactivity in oral mucosal cell surfaces with FITC-conjugated anti-human IgG antibody using Direct Immunofluorescence (DIF) on Tzanck smears taken from oral mucosae ($\times 63$). (C) DIF using ocular conjunctival scraped smears with FITC-conjugated anti-HSV-1 antibody showing positive nuclear staining ($\times 100$).

was detected on direct immunofluorescence (DIF) using Tzanck smears from oral mucosa (Fig. 2B), which suggested PV. Anti-herpes simplex virus (HSV)-1 antibody (Abcam, Cambridge, USA) on DIF using scraped smears showed negative staining in oral mucosa but positive nuclear staining in ocular conjunctiva (Fig. 2C), while immunohistochemistry using nasal mucosa biopsy showed negative HSV staining. Polymerase-chain-reaction for *Leishmania* sp., *Mycobacterium* sp., *M. tuberculosis* and *M. leprae*, and fungal culture from nasal mucosa samples were negative.

Antinuclear antibody, HIV and VDRL serologies were negative. Indirect immunofluorescence (IIF) using a normal human skin section detected IgG anti-keratinocyte cell surface antibodies. IIF on 1M-NaCl-split-skin was negative in the basement membrane zone.

ELISA (MBL, Japan) was positive for desmoglein (Dsg) 1 (112.7 U/mL) and Dsg3 (39.3 U/mL) (cut-off 20 U/mL), but negative for BP180 (4.21 U/mL) and BP230 (1.51 U/mL) (cut-off 9 U/mL). Immunoblotting analyses using normal human epidermal and dermal extracts, recombinant proteins of BP180 NC16a and C-terminal domains, concentrated culture supernatant of HaCaT cells, and purified human laminin – 332 were all negative.

The patient underwent three monthly cycles of pulse therapy (dexamethasone and cyclophosphamide), followed by oral prednisone 12.5 mg/day, and cyclophosphamide 50 mg/day. Acyclovir was also given. Skin lesions quickly disappeared. All the mucosal lesions gradually improved.

Nasal mucosal involvement in PV has rarely been reported¹. In this case, histopathology showed suprabasal acantholysis in nasal mucosa biopsy. Collagen disease and infections of HIV, syphilis, HSV, leishmaniasis, leprosy, and fungus were excluded². We suppose that the nasoseptal perforation was attributed secondarily to repetitive traumatic manipulation for PV-induced nasal mucosal crusts.

DIF on the Tzanck smear suggested HSV-1 infection for the left conjunctival lesion, and the conjunctival lesions improved after acyclovir treatment. HSV-1 infection was occasionally observed on the oral mucosa³, but not on the ocular conjunctiva, in PV.

Finally, our patient showed milium formation in skin previously affected by PV. Therefore, we also performed various IIF, ELISA, and immunoblotting analyses, which excluded the diagnoses of epidermolysis bullosa acquisita and bullous pemphigoid, the diseases commonly developing milia⁴.

In conclusion, although PV is a prevalent disease in South-eastern Brazil⁵, this is the first PV case with nasoseptal

perforation, conjunctival herpetic infection and milium-associated features.

Financial support

This study was partially supported by FAPESP (Fundação de Amparo à Pesquisa do Estado de São Paulo), process number 2010/51729-2, and by FAEPA (Fundação de Apoio ao Ensino, Pesquisa e Assistência). SV received a PhD scholarship from CAPES (Coordenação de Aperfeiçoamento de Pessoal de Nível Superior).

Authors' contributions

Sebastian Vernal: Has contributed with collection and interpretation of data, writing the manuscript, effective participation, literature review, final approval of the final version of the manuscript.

Roberto Bueno-Filho: Has contributed with collection and interpretation of data, effective participation, participation of therapeutic conduct of the studied cases, final approval of the final version of the manuscript.

Takashi Hashimoto: Has contributed with collection and interpretation of data, effective participation, writing the manuscript, final approval of the final version of the manuscript.

Ana Maria Roselino: Has contributed with the study concept and design, collection, and interpretation of data, writing the manuscript, effective participation, literature review, participation of therapeutic conduct of the studied cases, final approval of the final version of the manuscript.

Conflicts of interest

None declared.





Acknowledgments

We thank the medical staff, especially Dr. Daiane Pess, of the autoimmune dermatoses' outpatient clinics at the University Hospital of Ribeirão Preto Medical School, University of São Paulo. We are grateful to Dr. Norito Ishii, Department of Dermatology, Kurume University School of Medicine, and Kurume University Institute of Cutaneous Cell Biology for various serological studies for autoantibodies and autoanti-

gens. We also thank Aline Turatti, PhD, University Hospital of Ribeirão Preto Medical School, University of São Paulo, for technical assistance for direct and indirect immunofluorescence.

References

- Ohki M, Kikuchi S. Nasal, oral, and pharyngolaryngeal manifestations of pemphigus vulgaris: Endoscopic ororhinolaryngologic examination. *Ear Nose Throat J.* 2017;96:120-7.
- Sardana K, Goel K. Nasal septal ulceration. *Clin Dermatol.* 2014;32:817-26.
- Machado ARDSR, La Serra L, Turatti A, Machado AM, Roselino AM. Herpes simplex virus 1 and cytomegalovirus are associated with pemphigus vulgaris but not with pemphigus foliaceus disease. *Exp Dermatol.* 2017;26:966-8.
- Vernal S, Oliveira EV, Bueno Filho R, Julio TA, Donadi EA, Turatti A, et al. Bullous pemphigoid and milia: prevalence and clinical laboratory findings in a Brazilian sample. *An Bras Dermatol.* 2022;97:435-42.
- Celere BS, Vernal S, La Serra L, Franco Brochado MJ, Moschini LE, Roselino AM, et al. Spatial Distribution of Pemphigus Occurrence over Five Decades in Southeastern Brazil. *Am J Trop Med Hyg.* 2017;97:1737-45.

Sebastian Vernal ^a, Roberto Bueno-Filho ^a, Takashi Hashimoto ^b, Ana Maria Roselino ^{a,*}

^a Dermatology Division, Department of Clinical Medicine, Faculdade de Medicina de Ribeirão Preto, Universidade de São Paulo, Ribeirão Preto, SP, Brazil

^b Department of Dermatology, Kurume University School of Medicine, and Kurume University Institute of Cutaneous Cell Biology, Fukuoka, Japan

* Corresponding author.

E-mail: amfrosel@fmrp.usp.br (A.M. Roselino).

Received 15 August 2021; accepted 20 September 2021; Available online 21 March 2023

<https://doi.org/10.1016/j.abd.2021.09.019>

0365-0596/ © 2023 Sociedade Brasileira de Dermatologia.

Published by Elsevier España, S.L.U. This is an open access article under the CC BY license (<http://creativecommons.org/licenses/by/4.0/>).

Perniosis-like erythema after SARS-CoV2 infection reactivated by vaccination with inactivated virus[☆]



Dear Editor,

Chilblain-like or perniosis-like erythema (PLE) has been frequently reported in association with SARS-CoV2 infection.¹

With the advancement of vaccination against this virus, there have also been reports of these lesions after the use of messenger RNA (mRNA) vaccines.² This report describes a case in which such lesions manifested after the infection and recurred with the patient receiving a vaccine against COVID-19 containing inactivated virus.

A 71-year-old female patient presented with acrocyanosis and erythematous infiltrated papules on the fingers in June 2020. One week before, she had presented with asymptomatic SARS-CoV2 infection, confirmed by RT-PCR (real time – polymerase chain reaction) testing. The condition was treated with dapsone 50 mg/day, with improvement after two months of use. The patient had a previous history of central nervous system vasculitis, diagnosed seven years before, based on neurological manifestations – with-

[☆] Study conducted at the Dermatology Outpatient Clinic, Hospital das Clínicas, Universidade Federal de Minas Gerais, Belo Horizonte, MG, Brazil.