

# Mucous membrane pemphigoid with severe esophageal stricture

## Penfigoide de membranas mucosas com estenose esofágica grave

Lívia do Nascimento Barbosa<sup>1</sup>

Gustavo Costa Verardino<sup>3</sup>

Maria de Fátima Guimarães Scotelaro Alves<sup>5</sup>

Roberto Souto da Silva<sup>2</sup>

Alexandre Carlos Gripp<sup>4</sup>

**Abstract:** Mucous membrane pemphigoid (MMP) is a rare nosological entity. MMP consists of a clinical phenotype in which several autoimmune subepidermal bullous diseases are classified. It occurs predominantly in the mucous membranes and usually results in scarring. Esophageal involvement in MMP is rare and is generally seen in patients in whom lesions are widespread. The most common alterations are multiple esophageal membranes or strictures. In the present case, the authors report on a patient with MMP without any skin lesions and with severe esophageal strictures who went into remission following use of intravenous immunoglobulin.

**Keywords:** Esophageal stenosis; Pemphigoid, Benign mucous membrane; Pemphigoid, bullous

**Resumo:** O penfigoide de membranas mucosas é entidade nosológica encarada como um fenótipo, que engloba várias dermatoses autoimunes com lesões bolhosas subepidérmicas, ocorrendo predominantemente nas membranas mucosas, com êxito cicatricial. O acometimento esofágico no penfigoide de membranas mucosas é raro e observado em pacientes com lesão disseminada. As alterações mais comuns são múltiplas membranas ou constrictões esofagianas. No presente relato, os autores apresentam paciente com PMM sem lesões cutâneas e estenose esofágica grave, que entrou em remissão após uso de imunoglobulina venosa.

**Palavras-chave:** Estenose esofágica; Penfigoide bolhoso; Penfigoide mucomembranoso benigno

### INTRODUCTION

Mucous membrane pemphigoid (MMP) is a nosological entity considered to represent a phenotype that encompasses various autoimmune dermatoses with subepidermal bullous lesions that include bullous pemphigoid, acquired epidermolysis bullosa and dermatitis herpetiformis. Nevertheless, MMP predominantly affects the mucous membranes, resulting in scarring. The lesions are most commonly situated in the oral, ocular, nasopharyngeal, esophageal, laryngeal or genital mucosae. The vari-

ability of the disease and its morbidity depend on the degree to which the patient is affected and the location of the mucosa affected. Some authors believe that there is a correlation with an increased incidence of solid cancer, principally in patients in whom the disease was triggered by anti-epiligrin antibodies.<sup>1-7</sup>

### CASE REPORT

A 75-year old black housewife from Rio de Janeiro sought medical care in February 2007 com-

Received on 01.05.2010.

Approved by the Advisory Board and accepted for publication on 04.06.2010.

\* Study conducted at the Pedro Ernesto Teaching Hospital, State University of Rio de Janeiro (UERJ), Rio de Janeiro, RJ, Brazil.

Conflict of interest: None / *Conflito de interesse: Nenhum*

Financial funding: None / *Suporte financeiro: Nenhum*

<sup>1</sup> Specialist in Dermatology. Currently participating in a Master's Degree Program at the Antonio Pedro Teaching Hospital, Federal Fluminense University (UFF), Niterói, RJ, Brazil.

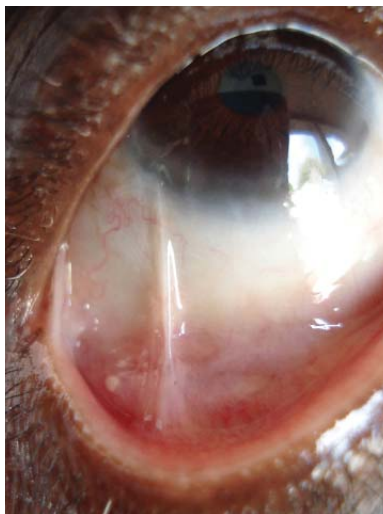
<sup>2</sup> Currently participating in a Master's Degree Program at the School of Medicine, State University of Rio de Janeiro (UERJ). Preceptor of the Outpatient Dermatology Clinic, Pedro Ernesto Teaching Hospital, UERJ, Rio de Janeiro, RJ, Brazil.

<sup>3</sup> Physician, currently undertaking postgraduate studies in Dermatology at the Pedro Ernesto Teaching Hospital, State University of Rio de Janeiro (UERJ), Rio de Janeiro, RJ, Brazil.

<sup>4</sup> Master's Degree in Dermatology. Auxiliary Professor, Pedro Ernesto Teaching Hospital, State University of Rio de Janeiro (UERJ), Rio de Janeiro, RJ, Brazil.

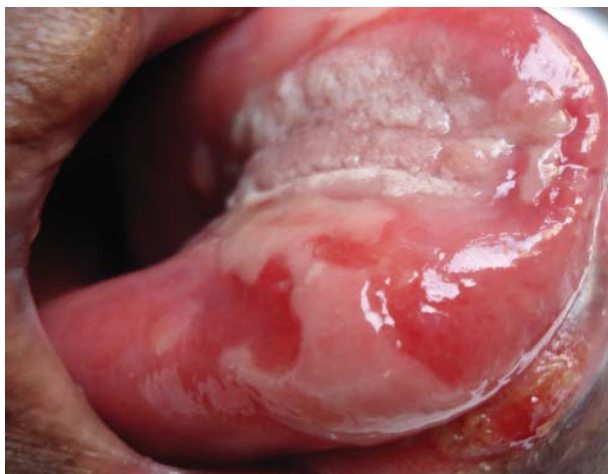<sup>5</sup> PhD in Dermatology. Adjunct Professor of Dermatology in charge of the Dermatopathology Sector, Pedro Ernesto Teaching Hospital, State University of Rio de Janeiro (UERJ), Rio de Janeiro, RJ, Brazil.

plaining of ulcerative lesions of the oral mucosa that had appeared around two years previously and were hampering mastication. She reported having had no health problems prior to the development of these symptoms. She also reported dysphagia for solids, hoarseness and the sensation of a foreign body in her eyes, which had developed in recent months and was becoming progressively worse. She denied having any other lesions on the skin or genital mucosa, any other systemic symptoms or having used any medication in recent years. At physical examination, the patient was found to be in good general health. Examination of the oropharynx revealed eroded lesions with a whitish halo on her palate, tongue and lower lip as well as a few eroded lesions in the cheek mucosa (Figure 1). There were also small, friable, easily ruptured bullous lesions, particularly on her tongue. There were no lesions on the tonsillar pillars, uvula or gums. Examination of the ocular mucosa showed the presence of bilateral, nasal and temporal symblepharon (Figure 2). No further abnormalities were found at dermatological examination and investigation of the cardiovascular and respiratory systems revealed no alterations. Additional tests were requested to clarify the condition, including biopsy of the perilesional mucosa. Hematoxylin-eosin (HE) staining revealed nonspecific inflammatory infiltrate, while direct immunofluorescence showed a linear deposit of IgG in the basement membrane of the epidermis (Figure 3). Barium esophagography showed significant stenosis in the mid-third of the esophagus, and this test was then complemented with upper digestive tract endoscopy, which confirmed the presence of stenosis that prevented the passage of the endoscope. Numerous lesions were observed in the esophageal

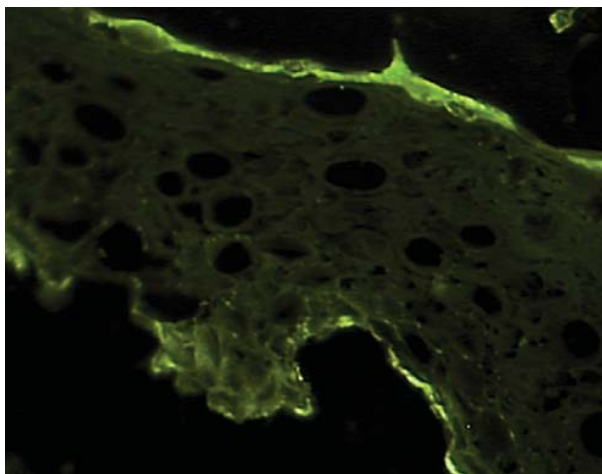


**FIGURE 2:** Temporal symblepharon of the right eye

and laryngeal mucosa and in the supraglottic region, extending beyond the passage of the endoscope (Figure 4). Indirect laryngoscopy confirmed the presence of edema and ulcerated lesions in the supraglottic region; however, the vocal cords were unaffected. Chest x-ray, colonoscopy, gynecological examination, mammography and ultrasonography of the abdomen and pelvis were also performed and no abnormalities were found. Based on the data obtained at clinical examination and on the supplementary tests, a diagnosis of mucous membrane pemphigoid was made and immunosuppressive therapy with glucocorticoids was implemented cautiously in view of the patient's advanced age. Treatment was carried out with methylprednisolone pulse therapy at a dose of 1 gram/day



**FIGURE 1:** Erosions of the mucous membranes of the lip and tongue



**FIGURE 3:** Direct immunofluorescence: linear deposits of IgG in the basement membrane of the epidermis

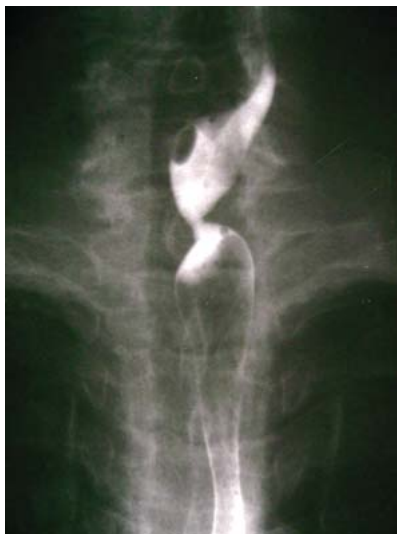

FIGURE 4: Barium esophagography showing stenosis in the upper third of the esophagus

for three consecutive days, with an interval of one week between each of the three cycles administered. There was a significant improvement in the patient's symptoms and in the lesions; therefore, treatment was continued with prednisone at a dose of 1 mg/kg/day on an outpatient basis. Sessions of esophageal dilatation were also provided by the department of gastroenterology and the patient reported a significant improvement in the dysphagia. Treatment was initiated with artificial tears and later followed up by the department of ophthalmology in this same hospital. After two months of follow-up, the patient returned to the clinic complaining that the lesions in the mucosa had deteriorated. At this time, the patient was hospitalized again and the first cycle of intravenous immunoglobulin was initiated at a dose of 1.5 mg/kg, divided over three days. Following treatment, an improvement occurred in her symptoms of dysphagia in the days immediately following pulse therapy. Some of the mucous lesions regressed and no new lesions appeared. The patient was followed up on an outpatient basis for a year during which time she was in use of prednisone 10 mg/day associated with sessions of esophageal dilatation at the gastroenterology department. Eighteen months after diagnosis, the patient died of an undetermined cause that was, however, unrelated to the symptoms of mucous membrane pemphigoid or to corticosteroid therapy.

## DISCUSSION

MMP is a rare vesicular bullous disease that predominantly affects middle-aged women. According to the European literature, the disease affects 1 in 1,000,000 individuals. Clinically, it consists of lesions in (in decreasing order): the oral mucosa, conjunctival

mucosa, scalp, genitalia, pharyngeal, laryngeal and esophageal mucosa. It is currently defined as a heterogeneous group of chronic subepidermal bullous diseases that predominantly affect the mucous membranes.<sup>1</sup> The condition is also known as cicatricial pemphigoid, benign mucous membrane pemphigoid, oral pemphigoid and ocular cicatricial pemphigoid.<sup>1,2</sup>

Involvement of the esophagus in mucous membrane pemphigoid is rare and is usually found in patients with a disseminated form of the disease. The most common alterations are the involvement of multiple mucous membranes or esophageal strictures. The esophagus is affected in only 2-13% of cases of mucous membrane pemphigoid. It may develop years after onset of the disease; however, esophageal involvement alone is very rare.<sup>3</sup>

The physiopathology of MMP is related to the production of antibodies against subepithelial antigens. Histopathology is unable to distinguish between cases of bullous pemphigoid and cases of acquired epidermolysis bullosa; therefore, diagnosis should always be based on clinical criteria.<sup>4</sup> Various studies suggest that there is an association with alleles of the HLA system such as HLADQB1\*0301. T-cells may also participate in the process of basement membrane antigen recognition and posterior production of antibodies by B cells.<sup>5</sup> These autoantibodies are varied and are specific to various antigens such as bullous pemphigoid antigen 2, epilegrin and type VII collagen, among others.<sup>1,6,7</sup>

As a function of the way in which each patient reacts to the autoantibodies involved, cicatricial pemphigoid may be classified into four different subgroups: the first group, in which patients present autoantibodies against laminin 5, cannot be distinguished clinically from the other groups; in the second group, the ocular mucosa is predominantly affected; in the third group, lesions are present in both the skin and the mucous membranes; while the fourth group encompasses patients in whom various mucous membranes may be affected but there is no skin involvement.<sup>8</sup>

Direct immunofluorescence in histology samples shows the presence of immune deposits (IgG, IgA and/or C3) in a linear pattern in the basement membrane zone.<sup>2</sup> In the present case, positivity was for IgG and the pattern was linear, which does not distinguish it from acquired epidermolysis bullosa or bullous pemphigoid.

Prior to making a decision on the therapeutic management of these patients, they should be subdivided into a low-risk group, which consists of patients in whom lesions are restricted to the oral mucosa, and a high-risk group in which patients have ocular, genital, pharyngeal, esophageal or laryngeal lesions. In

the first group, treatment is generally conservative; however, in the second group it has to be aggressive in order to avoid sequelae. In the second group, immunosuppressive therapy may include pulse methylprednisolone, cyclophosphamide, rituximab and even intravenous immunoglobulin in refractory cases.<sup>2,9-14</sup> The patient in question, who was classified as high-risk because of her ocular and esophageal lesions, was submitted to pulse therapy with methylprednisolone and intravenous immunoglobulin. Complete remission was achieved following the sec-

ond form of treatment.

The relevance of this case lies in the rarity of the form of presentation of the disease, which progressed over a long period of time without ever affecting the skin and because of the severity of the esophageal involvement that impaired the patient's quality of life. Another factor was the severity of the esophageal stricture that remained as a sequela even after the patient had achieved complete remission following the cycle of intravenous immunoglobulin. □

## REFERENCES

1. Cunha PR, Barraviera SRCS. Dermatoses bolhosas autoimunes. *An Bras Dermatol.* 2009;84:111-24.
2. Chan LS, Ahmed AR, Anhalt GJ, Bernauer W, Cooper KD, Elder MJ, et al. The first international consensus on mucous membrane pemphigoid: definition, diagnostic criteria, pathogenic factors, medical treatment, and prognostic indicators. *Arch Dermatol.* 2002;138:370-9.
3. Sallout H, Anhalt GJ, Firas H, Al-Kawas FH. Mucous membrane pemphigoid presenting with isolated esophageal involvement: a case report. *Gastrointest Endosc.* 2000;52:429-33.
4. Higgins TS, Cohen JC, Sinacori JT. Laryngeal Mucous Membrane Pemphigoid: A Systematic Review and Pooled-Data Analysis. *Laryngoscope.* 2010;120:529-36.
5. Mostafa IM, Hassib NF, Nemat AH. Oral mucous membrane pemphigoid in a 6-year-old boy: diagnosis, treatment and 4 years follow-up. *Int J Paediatr Dent.* 2010;20:76-9.
6. Egan CA, Lazarova Z, Darling TN, Yee C, Yancey KB. Anti-epiligrin cicatricial pemphigoid: clinical findings, immunopathogenesis, and significant associations. *Medicine (Baltimore).* 2003;82:177-86.
7. Parisi E, Raghavendra S, Werth VP, Sollecito TP. Modification to the approach of the diagnosis of mucous membrane pemphigoid: A case report and literature review. *Oral Surg Oral Med Oral Pathol Oral Radiol Endod.* 2003;95:182-6.
8. Borradori L, Bernad P. Pemphigoid Group. In: Bologna JL, Jorizzo JL, Rapini RP, editors. *Dermatology.* Philadelphia: Mosby; 2008. p.438-41.
9. Fleming TE, Korman NJ. Cicatricial pemphigoid. *J Am Acad Dermatol.* 2000;43:571-91.
10. Foster CS, Sainz De La Maza M. Ocular cicatricial pemphigoid review. *Curr Opin Allergy Clin Immunol.* 2004;4:435-9.
11. Lazarova Z, Yancey K. Cicatricial pemphigoid: immunopathogenesis and treatment. *Derm Ther.* 2002;15:382-88.
12. Sacher C, Hunzelmann N. Cicatricial pemphigoid (mucous membrane pemphigoid): current and emerging therapeutic approaches. *Am J Clin Dermatol.* 2005;6:93-103.
13. Carr DR, Hefferman MP. Off-label uses of rituximab in dermatology. *Derm Ther.* 2007;20:277-287.
14. Cunha PR, Barraviera SRCS. Dermatoses bolhosas autoimunes. *An Bras Dermatol.* 2009;84:111-24.

### MAILING ADDRESS / ENDEREÇO PARA CORRESPONDÊNCIA:

*Livia do Nascimento Barbosa*  
*Rua Presidente Baker, 72/801, Icaraí*  
*24220-041 Niterói (RJ) - Brasil*  
*Tel.: (21) 26180-3021*  
*E-mail: barbosalivia@terra.com.br*

How to cite this article/*Como citar este artigo*: *Barbosa LN, Souto RS, Veradino GC, Gripp AC, Scotelaro MFG. Mucous membrane pemphigoid with severe esophageal stricture . An Bras Dermatol.* 2011;86(3):565-8