

Acute respiratory distress syndrome as a complication of generalized pustular psoriasis

Síndrome do desconforto respiratório agudo como complicação de psoríase pustulosa generalizada

Laura de Sena Nogueira Maehara¹
Aécio Flávio Teixeira de Góis²
Sergio Yamada⁴

Máira Magalhães Mariano¹
Maria Helena V. Q. Padilha³
Adriana Maria Porro⁵

Abstract: Since 1991, eight cases of pulmonary leak capillary syndrome have been described associated with pustular or erythrodermic psoriasis induced or not by the use of acitretin or sirolimus – being one of the cases, fatal. We report the case of a female patient with diagnosed GPP or von Zumbusch and multiple hospitalizations due to such condition. At that time, the condition was evolving with pulmonary onset and resolution with corticosteroids. The patient was not using any previously described medication that could precipitate pulmonary condition (methotrexate and acitretin). This is a rare complication associated with psoriasis which has not been described in Brazilian patients so far.

Keywords: Capillary fragility; Capillary leak syndrome; Psoriasis; Respiratory distress syndrome, adult

Resumo: Desde 1991, há 8 casos relatados de síndrome da fragilidade capilar pulmonar associada à psoríase pustulosa ou eritrodérmica, induzida ou não pelo uso de acitretina ou sirolimus - um dos casos, fatal. Reportamos um caso de psoríase pustulosa de von Zumbusch em paciente feminina com antecedente de várias internações por quadro semelhante, evoluindo nesta ocasião com acometimento pulmonar e resolução com corticosteroide. A paciente não estava em uso de quaisquer medicações previamente descritas como capazes de precipitar o quadro pulmonar (metotrexate e acitretina). Esta é uma complicação rara associada à psoríase, não descrita em pacientes brasileiros até o momento.

Palavras-chave: Fragilidade capilar; Psoríase; Síndrome do desconforto respiratório do adulto; Síndrome de vazamento capilar

INTRODUCTION

Acute respiratory distress syndrome (ARDS) is a rare complication of generalized pustular psoriasis (GPP). ARDS can be caused by apulmonary capillary leak syndrome, an infection or by drugs hypersensitivity reaction (methotrexate or acitretin) and it seems to be related to cytokines (interleukin 1, tumor necrosis factor α and interleukin 2). Corticosteroids can reverse the clinical condition.

CASE REPORT

Thirty-seven year old female patient, phototype III, with a history of psoriasis since she was 14 and three hospitalizations due to disseminated pustular lesions. She had no other morbid history. (pneumo, cardio, nephropathy). She reported previous treatments with methotrexate, cyclosporine and UVA + psoralen method (PUVA). However, at that moment, the patient only presented disease control with topi-

Received on 04.12.2009.

Approved by the Advisory Board and accepted for publication on 12.05.2010.

* Work carried out at the Department of Dermatology from the Medical School of São Paulo – Federal University of São Paulo (EPM – UNIFESP) – São Paulo (SP), Brazil.

Conflict of interest: None / *Conflito de interesse: Nenhum*

Financial funding: None / *Suporte financeiro: Nenhum*

¹ Graduation - Department of Dermatology at the Medical School of São Paulo from the Federal University of São Paulo (EPM – UNIFESP) – São Paulo (SP), Brazil.

² Doctorate - Medical coordinator of the ICU Emergency and coordinator of the intern residents at São Paulo Hospital– Federal University of São Paulo (UNIFESP) – São Paulo (SP), Brazil.

³ Master's degree – Doctor of the Department of Dermatology at the Medical School of São Paulo- Federal University of São Paulo (EPM – UNIFESP) – São Paulo (SP), Brazil.

⁴ Master's degree – Professor of the Department of Dermatology at the Medical School of São Paulo – Federal University of São Paulo (EPM – UNIFESP) – São Paulo (SP), Brazil.

⁵ Doctorate - Professor of the Department of Dermatology at the Medical School of São Paulo – Federal University of São Paulo (EPM – UNIFESP) – São Paulo (SP), Brazil.

cal treatment in lesions that had been spotted a year ago (calcipotriol and corticosteroids).

A week before the medical consultation the patient developed new lesions, ardour, discomfort and fever. Dermatological exam revealed few pustules on the neck, lateral chest, arms and abdomen (Figure 1). A week later there was dissemination of the lesions despite the topical use of betamethasone valerate 0,1% and oral amoxicilin. The patient was then hospitalized, therapy with 40 mg of prednisone daily and cyclosporine 4 mg/kg/day was initiated. Skin biopsy confirmed pustular psoriasis (Figure 2). After two days the patient developed oliguria, peripheral edema, cough and orthopnea. Chest x-ray revealed intense infiltrate in the lung bases and computerized tomography showed bilateral pleural effusion and difuse bilateral pulmonary consolidations predominantly in the central regions and suggesting pulmonary edema. There was no alteration in renal function.

The patient was transferred to an intensive care unit for hemodynamic and ventilatory control. The case was discussed by the two teams and it was decided to keep the dose of oral prednisone – considering the possibility of ARDS by GPP – and to start antibiotics (cefepime and vancomycin) after the collection of cultures – if ARDS was secondary to an infection - but blood culture and urine culture were negative. After three days there was significant and sustainable improvement in the pulmonary symptoms. After twenty days there were no more skin lesions and prednisone was withdrawn slowly (Figure 3). The patient is currently under outpatient control of the disease and has been using acitretin for one year.

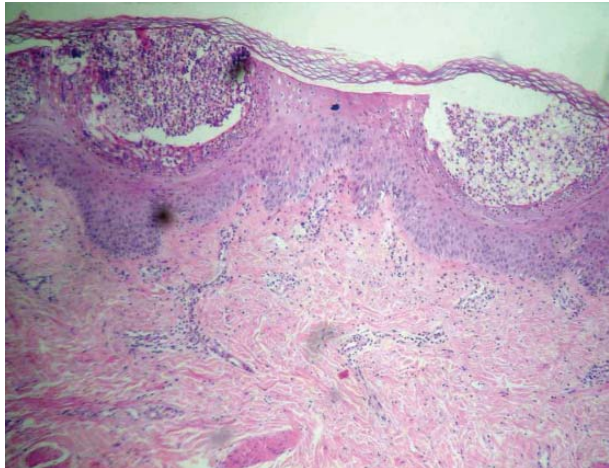


FIGURE 2: Subcorneal pustules characteristic of pustular psoriasis. (hematoxylin and eosin, 400x)

DISCUSSION

Since 1991¹, eight cases of ARDS have been described associated with generalized pustular psoriasis (GPP or von Zumbusch). ARDS is defined as a sudden onset of noncardiogenic pulmonary edema with refractory hypoxemia in the context of severe infection, aspiration pneumonia and trauma associated with shock and other causes.² This is also a rare manifestation of GPP.³ The pathogenesis of ARDS in GPP is related to lymphocyte T-helper 1 (Th1) that is activated in psoriasis.⁴ Animal models suggest the role of the tumor necrosis factor α (TNF- α) - important Th1 cytokine- in the alveolar damage.³ Other cytokines involved are interleukin 1 and 2.¹

It was reported here the case of a patient with

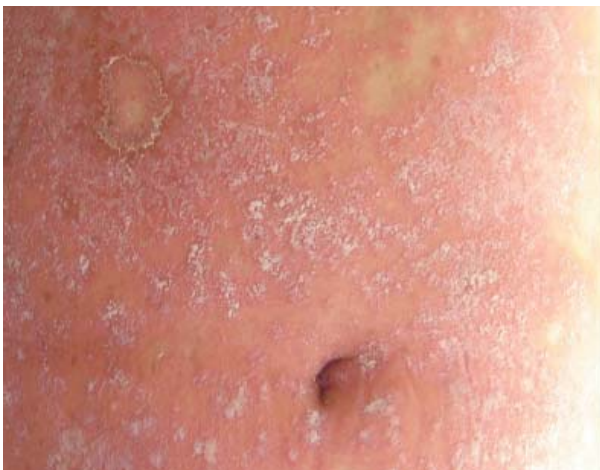

FIGURE 1: Generalized pustular psoriasis. Abdominal pustules are noted

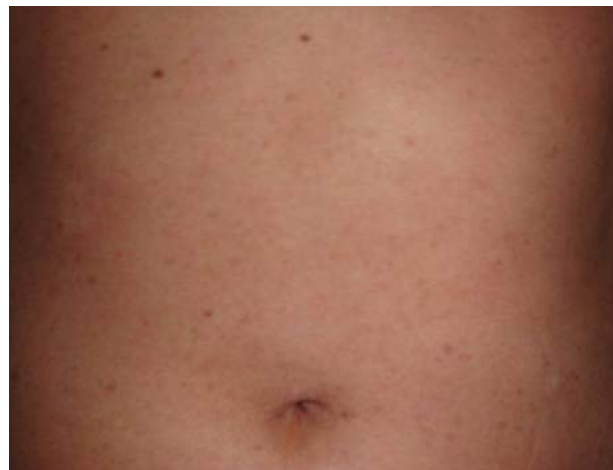

FIGURE 3: Five days after the resolution of the pulmonary condition there was complete resolution of the pustular lesions

diagnosis of pustular psoriasis and various previous hospitalizations due to GPP, without base cardiopulmonary disease, who presented sudden dyspnea, orthopnea and peripheral edema that associated with the exam of pulmonary image characterized ARDS – according to previous definition – associated with GPP. The condition was satisfactorily treated with corticoids and intensive care therapy as suggested by literature reports.^{2,3} Cyclosporine was introduced to control pustular psoriasis even before the patient starts to develop the pulmonary condition .

In GPP, ARDS can represent a pulmonary capillary leak syndrome, an infection or a drug reaction (already mentioned methotrexate and acitretin).³ Considering the fact that the patient was not using these medications and that there was no evidence of infection (blood culture or suggestive imaging), we can attribute the symptoms to the pulmonary capillary leak syndrome causing ARDS combined with GPP.³

The only medication that was being used was

calcipotriol (besides eventual use of topical corticosteroid), that is related to the onset of the GPP condition, but not to the onset of ARDS.^{5,6} Calcipotriol alone or combined with betamethasone were described as capable of precipitating GPP although a rare event.⁵ Calcipotriol is a known irritant. Therefore, it triggers irritant contact dermatitis in which keratinocytes release various cytokines among them IL-1, IL-6, TNF- α and IFN- γ . If the area of application is sufficiently extensive it is possible that the amount of cytokines released is sufficient to precipitate GPP.⁵ Therefore, it is possible that the GPP in our patient has been triggered by the topical use of calcipotriol and betamethasone. However, there is no report of development of ARDS after using these medications and we can not also discard the role of these drugs on the subsequent development of pulmonary condition.

The case was presented here as it is a serious complication associated with psoriasis and as it has, so far, not been described in Brazilian patients . □

REFERENCES

1. McGregor JM, Barker JN, MacDonald DM. Pulmonary capillary leak syndrome complicating generalized pustular psoriasis: possible role of cytokines. *Br J Dermatol.* 1991;125:472-4.
2. Griffiths MR, Porter W, Fergusson-Wood LA, Adriaans B. Generalized pustular psoriasis complicated by acute respiratory distress syndrome. *Br J Dermatol.* 2006;155:496-7.
3. Abou-Samra T, Constantin JM, Amarger S, Mansard S, Souteyrand P, Bazin JE, et al. Generalized pustular psoriasis complicated by acute respiratory distress syndrome. *Br J Dermatol.* 2004;150:353-6.
4. Arruda LHF, Campbell GAM, Takahashi MDF. Psoríase. *An Bras Dermatol.* 2001;76:141-67.
5. Tobin AM, Langan SM, Collins P, Kirby B. Generalized pustular psoriasis (von Zumbusch) following the use of calcipotriol and betamethasone dipropionate ointment: a report of two cases. *Clin Exp Dermatol.* 2009;34:629-30.
6. Tamiya H, Fukai K, Moriwaki K, Ishii M. Generalized pustular psoriasis precipitated by topical calcipotriol ointment. *Int J Dermatol.* 2005;44:791-2.

MAILING ADDRESS / ENDEREÇO PARA CORRESPONDÊNCIA:

Laura de Sena Nogueira Maehara
Rua Borges Lagoa 508
Vila Clementino
04038-001 São Paulo, SP – Brasil
E-mail: lauradesena@hotmail.com

How to cite this article/*Como citar este artigo*: Maehara LSN, Mariano MM, Góis AFT, Padilha MHVQ, Yamada S, Porro AM. Acute respiratory distress syndrome as a complication of generalized pustular psoriasis . *An Bras Dermatol.* 2011;86(3):579-81.