



## Stewart Treves Syndrome\*

Elisangela Samartin Pegas Pereira<sup>1</sup>  
Daniela Melo Siqueira<sup>1</sup>

Elisa Trino de Moraes<sup>1</sup>  
Marcel Alex Soares dos Santos<sup>1</sup>

DOI: <http://dx.doi.org/10.1590/abd1806-4841.20153685>

**Abstract:** Stewart-Treves Syndrome is characterized by the presence of lymphangiosarcoma on limb extremities. Rare, it occurs in 0.5% of patients who have undergone radical mastectomy with axillary node dissection. The main cause is chronic lymphedema with endothelial and lymphatic differentiation, with no direct relationship to breast cancer. Seven years after a radical right-side mastectomy with lymph node dissection and adjuvant therapy, the patient developed a lesion on her right arm. The dermatological examination revealed an erythematous nodule with bleeding surface on chronic right forearm lymphedema. After the biopsy, a lymphangiosarcoma on chronic lymphedema was diagnosed. Infrequent, this syndrome is relevant because of its associated mortality. Early diagnosis is important to improve survival and reduce complications.

**Keywords:** Lymphangiosarcoma; Lymphedema; Mastectomy; Radiotherapy

### INTRODUCTION

Stewart Treves syndrome is characterized by the presence of lymphangiosarcoma on chronic lymphedema. Commonly described as subsequent to radical mastectomy, it can also occur in cases of congenital diseases and chronic lymphedema secondary to other diseases.<sup>1</sup> It occurs in 0.5% of patients undergoing radical mastectomy with axillary dissection after 5 years or more.<sup>2</sup> The disease affects predominantly women, with a higher incidence in the fifth and seventh decades. The main etiopathogenesis is chronic lymphedema and it is believed to occur a neoplastic proliferation with blood and lymphatic endothelial differentiation, but it's not possible to determine which predominates, not existing a direct relationship with breast cancer.<sup>3,4</sup>

### CASE REPORT

Female patient, 79 years old, came to the Dermatology department due to the presence of a node on the right arm, with local bleeding. She presented Alzheimer's disease and reported history of radical mastectomy on the right side, lymph node dissection and adjuvant therapy (radiotherapy and

chemotherapy), for 7 years; and hysterectomy for 2 years due to cervix cancer. Dermatological examination revealed erythematous nodule with bleeding surface on the right forearm on chronic lymphedema. Diagnostic of pyogenic granuloma and amelanotic melanoma were suggested. It was performed excision of the lesion.

The patient returned in 2 months with histopathological results that showed multifocal epithelioid angiosarcoma, infiltrating the skin and deep soft tissue, and also microscopic perineural invasion without angiolymphatic invasion. Surgical margins were free. At the time, she presented papules and erythematous-violet nodules on the right arm on chronic lymphedema during dermatological examination (Figure 1). A new diagnosis was made: lymphangiosarcoma on chronic lymphedema (Stewart-Treves syndrome). In the breast ultrasonography it was found a left retroareolar nodule. Total abdominal ultrasonography, laboratory tests and chest X-ray showed no alterations. The patient was monitored in conjunction with the Oncology and Orthopedics departments, that performed amputation of the right arm, keeping proximal humerus.

Received on 08.05.2014.

Approved by the Advisory Board and accepted for publication on 13.08.2014.

\* Study performed at Serviço de Dermatologia da Pontifícia Universidade Católica de Campinas (PUC Campinas) – Campinas (SP), Brazil.  
Financial Support: None.  
Conflict of Interest: None.

<sup>1</sup> Pontifícia Universidade Católica de Campinas (PUC Campinas) – Campinas (SP), Brazil.

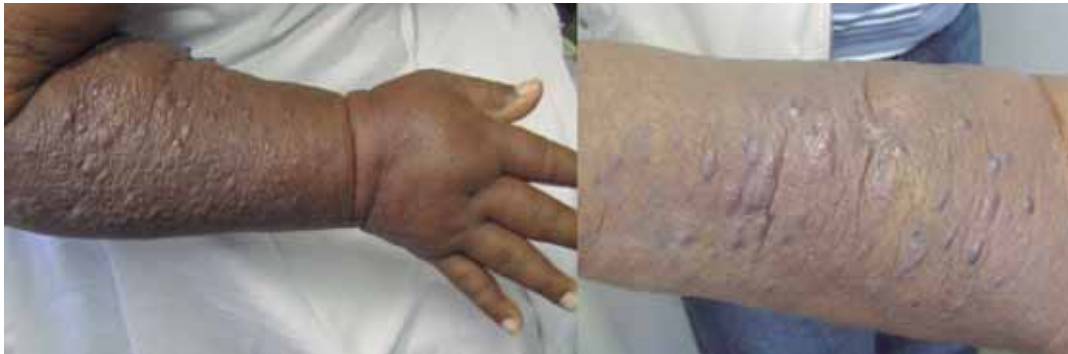

FIGURE 1: Multiple papules and erythematous-violet nodules on chronic lymphedema in the right upper limb

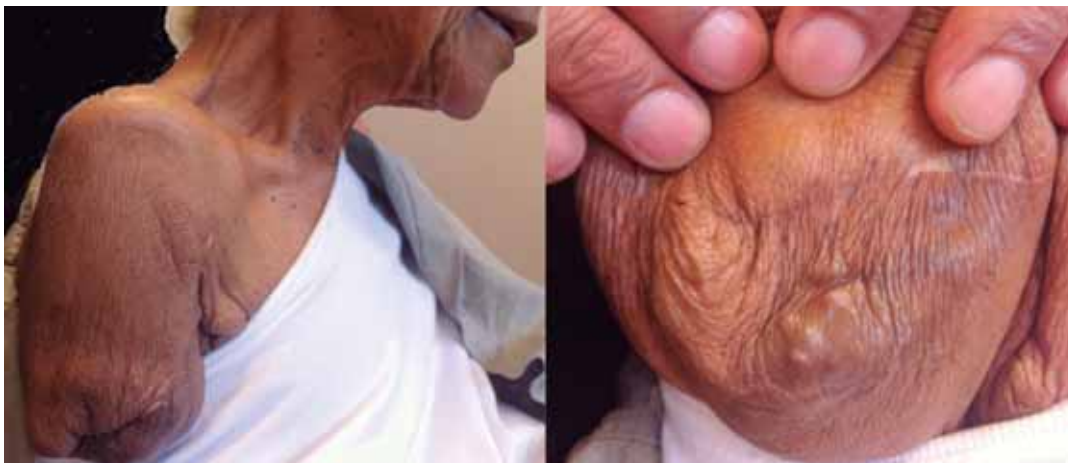

FIGURE 2: Local recurrence of lesions in the base of the amputated arm

After 3 months there was a local recurrence of lesions in the base of the amputated arm, and a new surgical approach was programmed (Figure 2).

#### DISCUSSION

Sarcomas are connective tissue tumors, comprising approximately 1% of all malignant tumors. They are subdivided according to the tissue of origin, and angiosarcoma is one of its aspects, emerging from vascular endothelium.

Stewart-Treves syndrome occurs usually after a latency period of 5 to 11 years after mastectomy.<sup>5</sup> There is failure of the local lymphatic drainage and consequent accumulation of interstitial fluid and lymphatic stasis. Thus, there is a reduction in local immunity with cellular degeneration by growth factors and angiogenic stimulus. This chronic process generates the malignant transformation characteristic of the disease. Use of radiotherapy in adjuvant treatment of early disease contributes directly to the development of the syndrome, attacking the DNA, and indirectly causing lymphatic blockage.<sup>6,7</sup>

The clinical profile features, as initial injury, violet stains and papules on chronic lymphedema, with possible ulceration of lesions. The most common sites of lesions are arms, followed by forearms and elbows.

The dissemination of lymphangiosarcoma occurs in the subcutaneous tissue, following the subcutaneous veins and extending beyond the proximal region of the affected limb. Metastases can impact any organ by hematogenous route, affecting most frequently lung and bones.

For diagnosis, besides dermatological test, it should be done a histopathological examination of the lesions, characterized by irregular vascular spaces of different sizes, and covered by polygonal cells with pleomorphic hyperchromatic nuclei and with positive immunohistochemistry for CD31 and CD34 (Figure 3).<sup>8</sup>

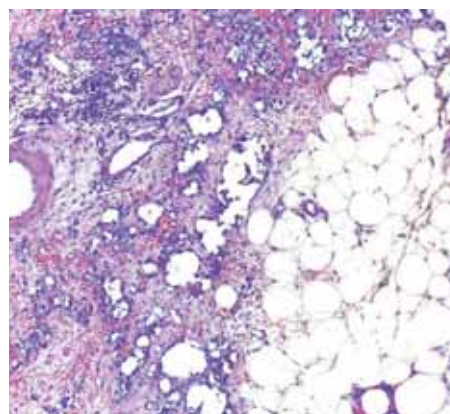


FIGURE 3: Irregular vascular spaces of different sizes and covered by polygonal cells with hyperchromatic pleomorphic nuclei (hematoxylin-eosin 10X).

Considering that the disease is multifocal, it can be treated with limb amputation associated with radiotherapy.<sup>1</sup> Excision should be wide when there is possibility of surgical margin.<sup>4</sup> Chemotherapy is reserved for patients with no clinical or surgical conditions, as unresectable disease or refusal of amputation. Radiotherapy is performed as adjuvant therapy.

The prognosis of Stewart-Treves syndrome is poor.<sup>9</sup> Its survival rate is approximately of 15 to 30 months and, without treatment, of nearly 6 months.<sup>1,10</sup> Local recurrence rate is high, with frequent need for further amputation.<sup>8</sup>

Although it is a rare disease, the diagnosis of Stewart-Treves syndrome is extremely important due to its morbidity and, especially, to its mortality. The disease can cause disability and impairment of the patient's quality of life, as well as lead to death in short time. Diagnosis should be made early, since it will cause a positive impact on survival and reduce the appearance of complications. But to reach an early diagnosis, medical specialties responsible for the treatment of the primary cancer, including breast cancer, should be aware of the emergence of this syndrome as a result.<sup>5</sup> □

## REFERENCES

1. Sharma A, Schwartz RA. Stewart treves syndrome: pathogenesis and management. *J Am Acad Dermatol.* 2012;67:1342-8.
2. Komorowski AL, Wysocki WM, Mitu J. Angiosarcoma in a chronically lymphedematous leg: an unusual presentation of stewart treves syndrome. *South Med J.* 2003;96:807-8.
3. Stanczyk M, Gewartowska M, Swierkowski M, Grala B, Maruszynski M. Stewart Treves syndrome angiosarcoma expresses phenotypes of both blood and lymphatic capillaries. *Chin Med J (Engl).* 2013;126:231-7.
4. Aguiar Bujanda D, Camacho Galán R, Bastida Iñarrea J, Aguiar Morales J, Conde Martel A, Rivero Suárez P, et al. Angiosarcoma of the abdominal wall after dermolipectomy in a morbidly obese man. A rare form of presentation of stewart treves syndrome. *Eur J Dermatol.* 2006;16:290-2.
5. Yokoyama A, Yokoyama K, Matsumoto K. Two cases of stewart treves syndrome observed at sanshu hospital. *Gan To Kagaku Ryoho.* 2010;37:229-31.
6. Iga N, Endo Y, Fujisawa A, Matsumura Y, Kabashima K, Tanioka M, et al. Two cases of cutaneous angiosarcoma developed after breast cancer surgery. *Case Rep Dermatol.* 2012;4:247-9.
7. Kunkel T, Mylonas I, Mayr D, Friese K, Sommer HL. Recurrence of secondary in a patient with postradiated breast for breast cancer. *Arch Gynecol Obstet.* 2008;278:497-501.
8. Tassone P, Tagliaferri P, Cucinotto I, Lavecchia AM, Leone F, Pietragalla A, et al. Pegylated liposomal doxorubicin is active in stewart treves syndrome. *Ann Oncol.* 2007;18:959-60.
9. Buehler D, Rice SR, Moody JS, Rush P, Hafez GR, Attia S, et al. Angiosarcoma outcomes and prognostic factors: a 25 year single institution experience. *Am J Clin Oncol.* 2014;37:473-9.
10. McHaffie DR, Kozak KR, Warner TF, Cho CS, Heiner JP, Attia S. Stewart treves syndrome of the lower extremity. *J Clin Oncol.* 2010;28:e351-2.

---

## MAILING ADDRESS:

*Daniela Melo Siqueira*  
*Faculdade de Medicina da Pontifícia Universidade Católica*  
*de Campinas*  
*Centro de Ciências da Vida*  
*John Boyd Dunlop Avenue,*  
*Jardim Ipaussurama*  
*13059-900 Campinas, SP*  
*Phone: 19 3343-8496*  
*Email: d.melosiqueira@gmail.com*

**How to cite this article:** Pareira ESP, Moraes ET, Siqueira DM, Santos MAS. Stewart Treves Syndrome. *An Bras Dermatol.* 2015;90(3 Suppl 1):S223-5