

5. Bilen N, Bayramgürler D, Sikar A, Erçin C, Yılmaz A. Anetoderma associated with antiphospholipid syndrome and systemic lupus erythematosus. *Lupus*. 2003;12:714–6.

Mariana Piraja Genta ^{a,*}, Marilda Aparecida Milanez Morgado de Abreu ^a, Gisele Alborghetti Nai ^b

^a Department of Dermatology, Hospital Regional de Presidente Prudente, Presidente Prudente, SP, Brazil

^b Department of Pathology, Universidade do Oeste Paulista, Presidente Prudente, SP, Brazil

Corresponding author.

E-mail: maripgenta@hotmail.com (M.P. Genta).

Received 28 February 2019; accepted 18 April 2019

<https://doi.org/10.1016/j.abd.2019.04.010>

0365-0596/ © 2019 Sociedade Brasileira de Dermatologia.

Published by Elsevier España, S.L.U. This is an open access article under the CC BY license (<http://creativecommons.org/licenses/by/4.0/>).

Familial fibrosing frontal alopecia in six sisters^{☆,☆☆}



Dear Editor,

Frontal fibrosing alopecia (FFA) is a progressive cicatricial alopecia that was first described by Kossard in 1994 and has been increasingly reported worldwide in the last decade. Familial cases of FFA have been described since 2008,¹ but all series include up to three relatives in the same generation or five in two generations.^{2,3} We encountered a group of six sisters presenting clinical and histological diagnosis of FFA in Brazil.

This family consists of eight siblings, two brothers (not examined), and six sisters, who are all committed by this condition (Fig. 1). The sisters' parents were not consanguineous, and were not examined, they are deceased. The sisters live in the same city; however, they do not live together. All of them are postmenopausal, and none has taken Hormone Replacement Therapy (HRT). The age at FFA onset ranges from 31 years to 62 years while the mean age is 50.7 years. Five have loss of eyebrows and eyelashes, and four have loss of body hair. Lichen Planus Pigmentosus (LPPig) is noted in two sisters and facial papules in three. The diagnosis was made by clinical and tricoscopic characteristics (Fig. 2). They refused to be submitted to

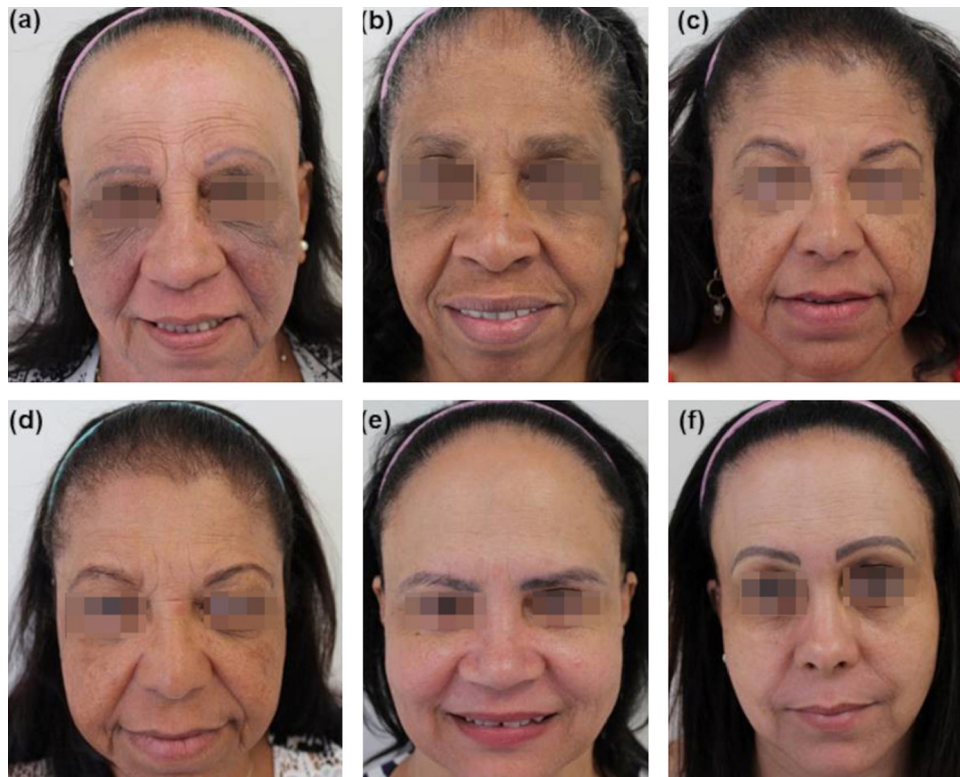


Figure 1 Six sisters with FFA, named by letters, being (a) the oldest and (f) the youngest.

[☆] How to cite this article: Rocha VB, Pires MC, Contin LA. Familial fibrosing frontal alopecia in six sisters. *An Bras Dermatol*. 2019;95:125–8.

^{☆☆} Study conducted at the Hospital do Servidor Público Municipal de São Paulo, São Paulo, SP, Brazil.

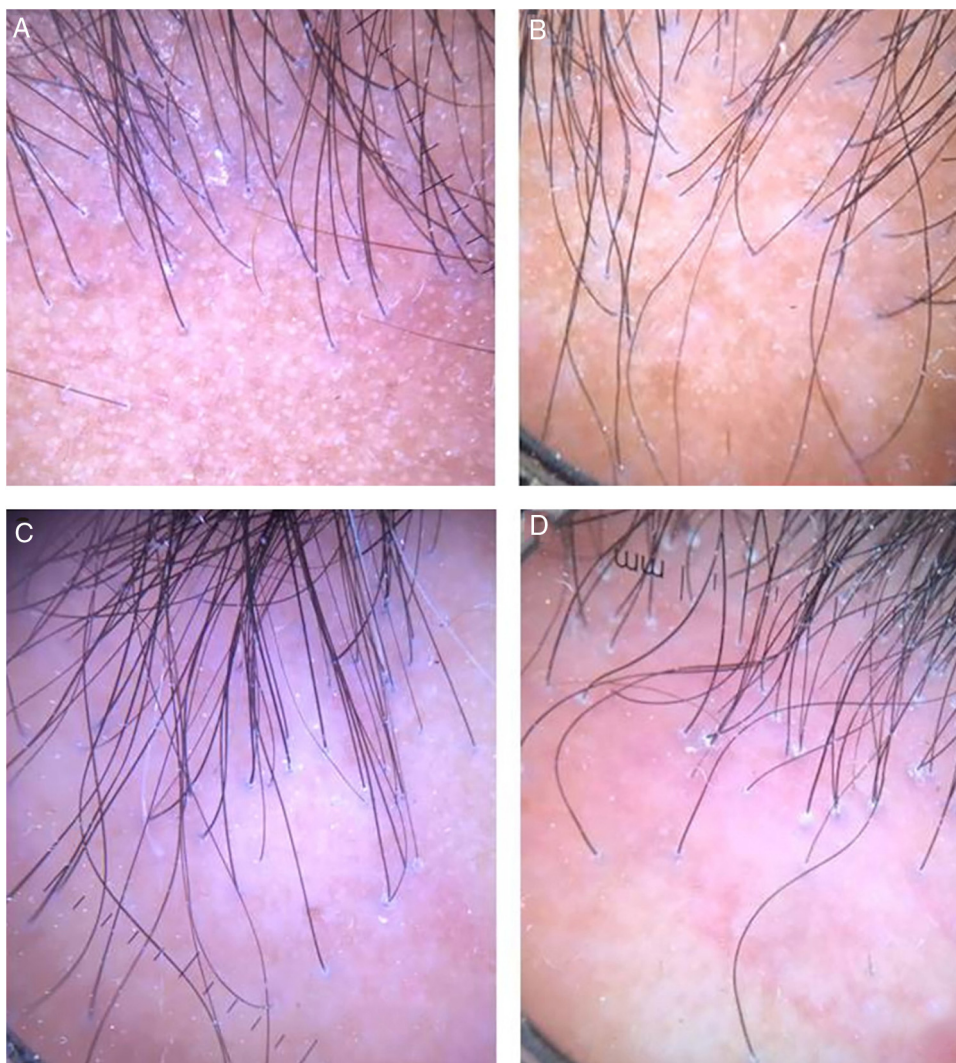

Figure 2 Tricoscopy of the frontal implantation region of patients a, b, e, f, showing absence of vellus and erythema and perifollicular desquamation in all cases, and interfollicular desquamation in C and D.

biopsy. As a differential diagnosis, it could be considered atrophic pilar keratosis, but none of them presented pilar keratosis.

Associated diseases are Systemic Arterial Hypertension (SAH) and Diabetes Mellitus (DM) in one patient, Deep Vein Thrombosis (DVT) and allergic rhinitis in two other. There are no cases of thyroid dysfunction. Clinical and demographic data are summarized in [table 1](#).

Clinical patterns of FFA have been described based upon frontal hairline recession as pattern I (linear), pattern II (diffuse), pattern III (pseudo-''fringe sign'')⁴ and patchy pattern.⁵ In our series pattern II is found in all of the patients and patchy pattern in one.

The genetic of FFA is still unknown. Studies show that HLA-DR1 has been implicated in lichen planus and Lassueur-Graham-Little-Piccardi syndrome, but it was not found in FFA.¹ Familial cases could indicate a genetic mechanism.

Moreover, the FFA epidemic seen nowadays strongly suggests an environmental trigger is also involved. In this series we could not define any substance that could be pointed

as this factor, even though they all used sunscreen at some point in their lives.

To our knowledge, this is the largest series with FFA in the same family ever described. Studying these families could help to understand the genetic and the pathogenesis of this intriguing disease.

Financial support

None declared.

Author's contribution

Vanessa Barreto Rocha: Approval of the final version of the manuscript; conception and planning of the study; elaboration and writing of the manuscript; collection, analysis, and interpretation of data; critical review of the literature; critical review of the manuscript.

Mario Cezar Pires: Approval of the final version of the manuscript; effective participation in research orientation; critical review of the literature.

Table 1 Clinical and demographic data of the six sisters with frontal fibrosing alopecia.

Patient	Patient age/phototype	Age at diagnosis	Clinical subtype of FFA	LPPig	Eyebrow loss	Eyelashes loss	Body hair loss	Facial papules	Age of menopause/HRT	Comorbidities
1	67y, III	52y	II (diffuse)	Yes	Yes	Yes	Yes	No	55y/no	SAH, DM
2	64y, V	62y	Patchy + II	No	Yes, partial	Yes	No	No	48y/no (hysterectomy)	No
3	62y, IV	60y	II	No	No	Yes	Yes	No	55y/no	No
4	61y, IV	31y	II	No	Partial	Yes	Yes	Yes	48y/no	Allergic rhinitis
5	52y, III	50y	II	No	Yes	No	Yes	Yes	49y/no	DVT
6	51y, III	49y	II	Yes	Yes	Yes	No	Yes	51y/no	No

LPPig, Lichen Planus Pigmentosus; HRT, Hormone Replacement Therapy; SAH, Systemic Arterial Hypertension; DM, Diabetes Mellitus; DVT, Deep Vein Thrombosis.

Leticia Arsie Contin: Approval of the final version of the manuscript; conception and planning of the study; elaboration and writing of the manuscript; collection, analysis, and interpretation of data; effective participation in research orientation; intellectual participation in propaedeutic and/or therapeutic conduct of the cases studied; critical review of the manuscript.

Conflicts of interest

None declared.

References

1. Roche M, Walsh M, Armstrong D. Frontal fibrosing alopecia – occurrence in male and female siblings. *J Am Acad Dermatol.* 2008;58(S2):AB81.
2. Tziotzios C, Fenton DA, Stefanato CM, McGrath JA. Familial frontal fibrosing alopecia. *J Am Acad Dermatol.* 2015;73:e37.
3. Dlova N, Goh CL, Tosti A. Familial frontal fibrosing alopecia. *Br J Dermatol.* 2013;168:220–2.
4. Moreno-Arrones OM, Saceda-Corralo D, Fonda-Pascual P, Rodrigues-Barata AR, Buendía-Castaño D, Alegre-Sánchez A, et al. Frontal fibrosing alopecia: clinical and prognostic classification. *J Eur Acad Dermatol Venereol.* 2017;31:1739–45.
5. Contin LA, de Almeida Ledá YL, Caldeira Nassif K, Suárez Restrepo MV. Patchy frontal fibrosing alopecia: description of an incomplete clinical presentation. *Skin Appendage Disord.* 2017;3:190–2.

Vanessa Barreto Rocha *, Mario Cezar Pires ,
Leticia Arsie Contin 

Hospital do Servidor Público Municipal de São Paulo, São Paulo, SP, Brazil

Corresponding author.

E-mail: vanessabarreto@oi.com.br (V.B. Rocha).

Received 10 September 2018; accepted 6 February 2019

<https://doi.org/10.1016/j.abd.2019.02.009>

0365-0596/ © 2019 Sociedade Brasileira de Dermatologia.

Published by Elsevier España, S.L.U. This is an open access article under the CC BY license (<http://creativecommons.org/licenses/by/4.0/>).