



WHAT IS YOUR DIAGNOSIS?

Case for diagnosis. Pruritic erythematous squamous lesion in the auricle☆☆☆



Elaine Dias Melo ^{a,*}, Patrícia Motta de Moraes ^b,
Débora Cristina de Lima Fernandes ^c, Paula Frassinetti Bessa Rebello ^d

^a Teaching and Research Department, Fundação de Dermatologia Tropical e Venereologia Alfredo da Matta, Manaus, AM, Brazil

^b Department of Histopathology, Fundação de Dermatologia Tropical e Venereologia Alfredo da Matta, Manaus, AM, Brazil

^c Laboratory of Mycology, Fundação de Dermatologia Tropical e Venereologia Alfredo da Matta, Manaus, AM, Brazil

^d Department of Tropical Dermatology, Fundação de Dermatologia Tropical e Venereologia Alfredo da Matta, Manaus, AM, Brazil

Received 4 October 2019; accepted 24 November 2019

Available online 11 May 2020

KEYWORDS

Auricle;
Chromoblastomycosis;
Ear, external;
Mycosis

Abstract Chromoblastomycosis is a subcutaneous mycosis with chronic evolution that mainly affects the lower limbs and, less frequently, the auricles. Clinically, it presents with papillary verrucous, nodular, and/or tumoral lesions, whether isolated or infiltrated, forming plaques and, sometimes, atrophic in some areas. Histopathologically, it is characterized by a dermal granulomatous inflammatory infiltrate, and the diagnosis can be confirmed by the presence of fumagoid bodies in anatomopathological or direct mycological exams. The treatment to be indicated will depend on the extent and location of the lesions, using systemic antifungals, surgical removal, cryotherapy, thermotherapy, and immunoadjuvants. The present study reports an atypical presentation of chromoblastomycosis on the auricle.

© 2020 Sociedade Brasileira de Dermatologia. Published by Elsevier España, S.L.U. This is an open access article under the CC BY license (<http://creativecommons.org/licenses/by/4.0/>).

Case report

A 57-year-old male farmer presented a pruritic lesion on the left auricle, with 20 years of evolution. He did not

recall local trauma at the onset of the condition. Upon examination, an infiltrated, erythematous squamous lesion was observed on the left ear. The histopathological examination presented a granulomatous inflammatory infiltrate with suppurative foci (Fig. 1A and B).

What is your diagnosis?

☆ How to cite this article: Melo ED, Moraes PM, Fernandes DCL, Rebello PFB. Case for diagnosis. Pruritic erythematous squamous lesion in the ear. An Bras Dermatol. 2020;95:521–3.

☆☆ Study conducted at the Fundação de Dermatologia Tropical e Venereologia Alfredo da Matta, Manaus, AM, Brazil.

* Corresponding author.

E-mail: e.dmelo@yahoo.com (E.D. Melo).

1. Jorge Lobo's disease
2. Sarcoidosis
3. Paracoccidioidomycosis
4. Chromoblastomycosis

<https://doi.org/10.1016/j.abd.2019.11.011>

0365-0596/© 2020 Sociedade Brasileira de Dermatologia. Published by Elsevier España, S.L.U. This is an open access article under the CC BY license (<http://creativecommons.org/licenses/by/4.0/>).

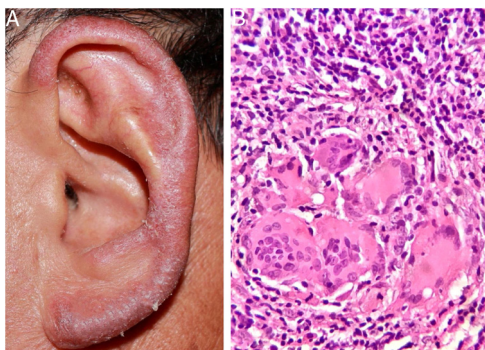


Figure 1 (A and B) Erythematous, infiltrative lesion in the left ear. Histopathological examination: granulomatous inflammatory infiltrate with suppurative foci (Hematoxylin & eosin, $\times 400$).

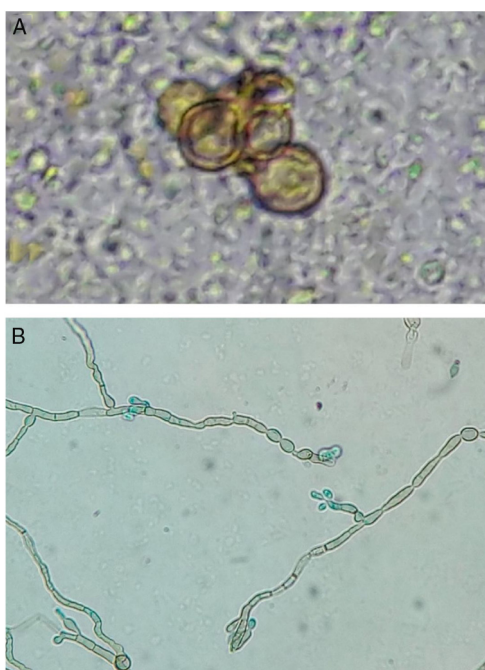


Figure 2 (A and B) Direct examination: fumagoid bodies. Microculture: septate demaceous hyphae and elliptical conidia in the upper portion of simple or slightly branched conidiophores – phenotypic characteristics compatible with *Rhinocladiella* spp. (KOH-20%, $\times 400$; blue, lactophenol, $\times 400$).

The review of the sections for histopathological examination evidenced the presence of fumagoid bodies, compatible with chromoblastomycosis.

In the direct examination of biopsy fragments in 20% KOH, septate demaceous hyphae and isolated yeast cells in pairs were observed, as well as some gemmule structures. In culture, on Mycosel agar (DIFCO®) and Sabouraud dextrose agar (DIFCO®) with chloramphenicol (0.05 g/L), a blackened colony growth was observed; in microculture, phenotypic findings compatible with *Rhinocladiella* sp. were observed (Fig. 2 A and B).

R. aquaspersa was confirmed through amplification and sequencing of the intergenic spacer (ITS) region of the

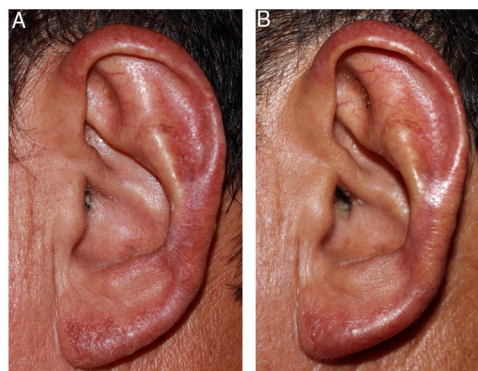


Figure 3 (A and B) After 25 days of treatment, and at the end of ten weeks.

ribosomal DNA (rDNA) using the polymerase chain reaction (PCR) technique.

After confirmation of the diagnosis of chromoblastomycosis, itraconazole (300 mg/day) was initiated; the patient presented significant improvement after 25 days and almost complete remission in ten weeks (Fig. 3 A and B). The patient remains under outpatient follow-up.

Discussion

Chromoblastomycosis is a subcutaneous mycosis caused by demaceous fungi of the order Chaetothyriales, family Herpotrichiellaceae, found in decomposing soil, vegetables, plants, and wood.^{1,2} The main etiological agents are from the genera *Fonsecaea*, *Cladophialophora*, *Phialophora*, *Rhinocladiella*, and *Exophiala*. Inoculation occurs after trauma with contaminated material.^{1,3,4}

The condition most frequently affects men between 40 and 50 years of age, being considered a cosmopolitan disease, with greater prevalence in tropical and subtropical regions.² In Brazil, it occurs in most states, with a predominance in the Amazon region, particularly in the state of Pará.^{2,5}

The disease mainly affects the lower limbs. In cases with long evolution, association with lymphedema is common.^{1,4,6} In Japan, the most common locations involved are the upper limbs, face, and cervical region.² Reports of manifestations exclusively on the auricle are rare.^{1,3,6-10} Among the cases reported in this topography, *Fonsecaea pedrosoi*^{1,3,10} and *Phialophora verrucosa*⁷ were the most commonly identified agents, followed by *Fonsecaea nubica*⁶ and *Rhinocladiella aquaspersa*.⁸

According to the literature consulted, this is the second case with isolated involvement of the auricle caused by *R. aquaspersa*.

In the Amazon region, the differential diagnosis must include Jorge Lobo's disease, leprosy, anergic leishmaniasis, cutaneous tuberculosis, and paracoccidioidomycosis. Histopathological and mycological exams are essential for diagnosis.

Several treatments are indicated for chromoblastomycosis. For localized lesions, surgical excision, cryotherapy, or thermotherapy are recommended; for more extensive cases, systemic and immunoadjuvant antifungals are recommended.^{2,4} Among systemic antifungals, itraconazole,

posaconazole, voriconazole, and isavuconazole are used.⁴ The literature reports two cases of chromoblastomycosis in auricular locations, which presented complete regression after treatment with flucytosine³ and itraconazole¹ for 12 and 10 weeks, respectively.

There are reports of a good therapeutic response with the association of systemic antifungals and topical immunoadjuvants, such as imiquimod.⁴

Financial support

None declared.

Authors' contributions

Elaine Dias Melo: Conception and planning of the study; elaboration and writing of the manuscript; obtaining, analyzing, and interpreting the data; intellectual participation in propaedeutic and/or therapeutic conduct of studied cases; critical review of the literature.

Patrícia Motta de Moraes: Approval of the final version of the manuscript; intellectual participation in propaedeutic and/or therapeutic conduct of studied cases; critical review of the literature; critical review of the manuscript.

Débora Cristina de Lima Fernandes: Elaboration and writing of the manuscript; critical review of the literature.

Paula Frassinetti Bessa Rebello: Approval of the final version of the manuscript; intellectual participation in propaedeutic and/or therapeutic conduct of studied cases.

Conflicts of interest

None declared.

Acknowledgements

Thanks to professor Antônio Pedro Mendes Schettini, dermatopathologist, head of the histopathology laboratory

at the Fundação de Dermatologia Tropical e Venereologia Alfredo da Matta; Dr. Sinésio Talhari, dermatologist at the Fundação de Dermatologia Tropical e Venereologia Alfredo da Matta; and Dr. Maria Zeli Moreira Frota, biochemical pharmacist at the Universidade Federal do Amazonas.

References

1. Estrada VFM, Paz GAV, Tolosa MR. Chromomycosis: report of a case with unusual topography. *Rev Iberoam Micol.* 2011;28:50–2.
2. Brito AC, Bittencourt MJS. Chromoblastomycosis: an etiological, epidemiological, clinical, diagnostic, and treatment update. *An Bras Dermatol.* 2018;93:495–506.
3. Iwatsu T, Takano M, Okamoto S. Auricular chromomycosis. *Arch Dermatol.* 1983;119:88–9.
4. Queiroz-Telles F, de Hoog S, Santos DW, Salgado CG, Vicente VA, Bonifaz A, et al. Chromoblastomycosis. *Clin Microbiol Rev.* 2017;30:233–76.
5. Talhari S, Cunha MG, Schettini AP, Talhari AC. Deep mycoses in Amazon region. *Int J Dermatol.* 1988;27:481–4.
6. Chen Y, Yin S, Li M, Chen R, Wei L, Ma H, et al. A case of chromoblastomycosis by *Fonsecaea nubica* indicating a possible insect route of transmission. *Mycoses.* 2016;59:662–7.
7. Bittencourt AL, Londero AT, Andrade JA. Auricular chromoblastomycosis. A case report. *Rev Inst Med Trop São Paulo.* 1994;36:381–3.
8. Arango M, Jaramillo C, Cortés A, Restrepo A. Auricular chromoblastomycosis caused by *Rhinocladiella aquaspersa*. *Med Mycol.* 1998;36:43–5.
9. Minotto R, Bernardi CD, Mallmann LF, Edelweiss MI, Scroferneker ML. Chromoblastomycosis: a review of 100 cases in the state of Rio Grande do Sul, Brazil. *J Am Acad Dermatol.* 2001;44:585–92.
10. França K, Villa RT, Bastos VR, Almeida AC, Massucatti K, Fukumaru D, et al. Auricular chromoblastomycosis: a case report and review of published literature. *Mycopathologia.* 2011;172:69–72.