

## Tufted angioma: a case report treated with pulsed-dye laser\* *Angioma em tufos: relato de um caso tratado com laser corante pulsado\**

Alberto Oiticica Cardoso<sup>1</sup>  
Luís Antonio Torezan<sup>4</sup>  
Marcello Menta Simonsen Nico<sup>7</sup>

Tatiana Tayti<sup>2</sup>  
Mirian N. Sotto<sup>5</sup>  
Nuno de Sanches Osório<sup>8</sup>

Juliana Pedroso de Oliveira<sup>3</sup>  
Maria Aparecida Vilela<sup>6</sup>  
Cyro Festa Neto<sup>9</sup>

**Abstract:** Tufted angioma is a rare, benign, cutaneous angiomatous proliferation. It is more common in children and is clinically characterized by red-purple painfull plaques, more common in trunk. When spontaneous regression does not occur, proposed treatments (conventional surgery, steroid therapy, interferon and laser) achieve little success. We describe a case of a 11-year-old girl with a tufted angioma located in the trunk treated with pulsed-dye laser, showing important relief of local pain, and small reduction in lesion size. We have been motivated to describe this case due to the small number of such reports in Brazil and by the attempt to treat it with pulsed-dye laser.

Keywords: Hemangioma; Lasers; Therapeutics

**Resumo:** O angioma em tufos é quadro raro, benigno, de proliferação cutânea angiomatosa. Acomete mais crianças e clinicamente caracteriza-se por lesões em placas, vermelho-violáceas, dolorosas e mais frequentes no tronco. Quando não regride espontaneamente, os tratamentos propostos (cirurgia convencional, corticoterapia, interferon e laser) alcançam pouco sucesso. Descreve-se o caso de uma menina de 11 anos, com angioma em tufos no tronco, tratada com laser corante pulsado que mostrou alívio importante da dor local e redução discreta do tamanho da lesão. A raridade de casos relatados no Brasil e a tentativa terapêutica com laser corante pulsado motivaram a divulgação do caso.

**Palavras-chave:** Hemangioma; Lasers; Terapêutica

Received on April 06, 2004.

Approved by the Consultative Council and accepted for publication on May 29, 2006.

\* Work done at the University Hospital of the Universidade de São Paulo - HC-FMUSP - São Paulo (SP), Brazil.

Conflict of interests: None

<sup>1</sup> Resident doctor/trainee in Dermatology at Hospital das Clínicas da Faculdade de Medicina da Universidade de São Paulo - HC-FMUSP - São Paulo (SP), Brazil.

<sup>2</sup> Resident doctor/trainee in Dermatology at Hospital das Clínicas da Faculdade de Medicina da Universidade de São Paulo - HC-FMUSP - São Paulo (SP), Brazil.

<sup>3</sup> Dermatologist.

<sup>4</sup> Dermatologist.

<sup>5</sup> PhD, Prof at the Department of Dermatology at Hospital das Clínicas da Faculdade de Medicina da Universidade de São Paulo - HC-FMUSP - São Paulo (SP), Brazil.

<sup>6</sup> PhD, Prof at the Department of Dermatology at Hospital das Clínicas da Faculdade de Medicina da Universidade de São Paulo - HC-FMUSP - São Paulo (SP), Brazil.

<sup>7</sup> PhD, Prof at the Department of Dermatology at Hospital das Clínicas da Faculdade de Medicina da Universidade de São Paulo - HC-FMUSP - São Paulo (SP), Brazil.

<sup>8</sup> Dermatologist.

<sup>9</sup> Prof at the Department of Dermatology at Hospital das Clínicas da Faculdade de Medicina da Universidade de São Paulo - HC-FMUSP - São Paulo (SP), Brazil.

## INTRODUCTION

Tufted angioma is a rare, benign condition of cutaneous angiomatous proliferation whose name is based on its histological pattern. It affects children more often, and is clinically characterized by pain erythematous-purple plaque lesions, more frequent in trunk.<sup>1</sup> Its diagnosis is made by characteristic histological examination, with the presence of vessels grouped in glomerulus-like patterns with the aspect of a “cannon bullet”.<sup>2</sup> When it does not regress spontaneously, it responds little to proposed treatments, such as conventional surgery, steroids, interferon and laser.

Approximately 60 cases have been described in the English literature and 160 in Japan, where it is called angioblastoma.<sup>3</sup> The existence of rare cases in Brazil<sup>4</sup> and the attempt of treatment with pulsed-dye laser have motivated the publication of the case.

## CASE REPORT

Eleven-year-old brown-skinned female patient, Born at and coming from Nova Conquista, Bahia, who sought for our service with the complaint of a spot in the right mammary region, with progressive growth for six years. Upon dermatological examination, an erythematous-purple infiltrated plaque was noted on the right mammary region, together with multiple satellite plaques with the same features, extending to the dorsum (Figure 1). Lesions presented an increase in local sensitivity and were painful to palpation, and had no history of bleeding or ulceration.

A biopsy of the mammary lesion was performed, with the observation, on histological examination, of vessels grouped in glomerulus-like patterns with the aspect of a “cannon bullet” in the mid and

deep reticular dermis. In the periphery of the tufted capillaries, were noted canalicular structures in glomerulus-like patterns (Figure 2) with thin dilated walls, with a semilunar aspect. Upon immunohistochemistry, dermal dendrocytes (CD34+) were observed, evidencing the “cannon bullet” pattern. Histological findings were compatible to the diagnosis of tufted angioma.

With the intention of verifying the extension of the lesions, a magnetic resonance was carried out, revealing the presence of a hypervascular disc-shaped lesion affecting skin and underlying subcutaneous tissue of the anteroposterior wall of the right thorax, with no signs of infiltration in the underlying muscles.

An initial attempt was made for a treatment with intralesional injection of triancilone at 5mg/mL; however, the patient complained a lot of pain, making the procedure impossible.

Based on the literature and on the vascular nature of the pathology, the choice was made for the attempt of treatment with laser. Initially a test with NdYAG long pulse laser (Vasculight®/Lumenis, 1064nm of wavelength) was carried out, with a fluence of 90J and pulse duration of 100 ms, with no response. Later, pulsed-dye laser was attempted (Candela-VBEAM FLPDL, with 585 to 595nm of wavelength). Patient was submitted to four sessions, in which large areas were treated, with the fluence ranging from 8,0 to 9,0J/cm<sup>2</sup>, a spot of 7mm, and pulse duration time ranging from 0,45 to 3ms. Interval between sessions was 45 days. During laser application, the patient complained of pain, despite use of topic local anesthetic (lidocaine and prilocaine). Lesion

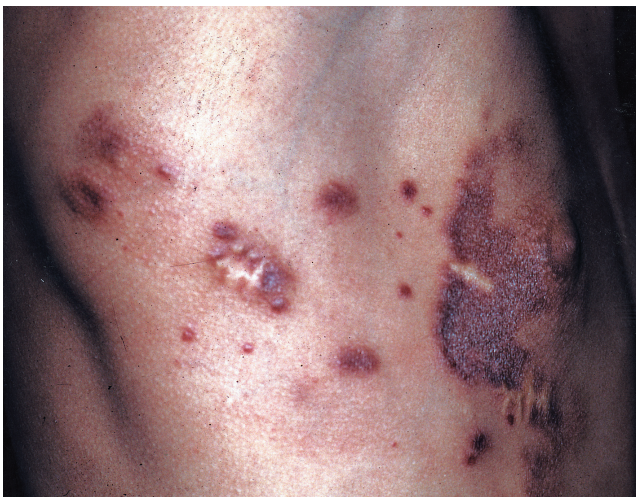

FIGURE 1: Tufted hemangioma on right breast, extending to dorsum

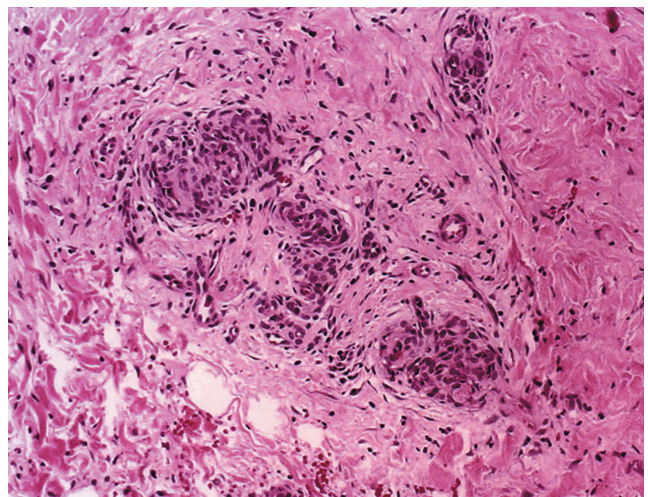


FIGURE 2: Histological skin slices stained by HE (100x). Capillary tufts in glomerulus-like pattern

size reduced little and, by the end of the sessions, there was a clinical improvement of about 20% of treated areas (Figure 3), yet with an almost total decrease in pain. During case follow-up, of around three years, new papules appeared, demonstrating the case was not yet stabilized.

## DISCUSSION

Tufted angioma was described by Nakagawa<sup>5</sup> in 1949 under the name of angioblastoma. Later, Wilson-Jones,<sup>2</sup> in 1976, based on a case series, designated this vascular tumor as an “acquired tufted angioma”, with regards to its histological aspect. They were initially considered to be distinct nosological entities, but today many consider them as the same disease.<sup>6,7</sup> There are reports of this vascular tumor in Asia, Europe, United States and Latin America.

Tufted angioma is a rare, benign condition of cutaneous angiomatous proliferation. Mechanism leading such vascular proliferation remains obscure. Several hypotheses have been formulated, based on clinical observations. The possible participation of estrogens was considered in a patient whose tumor onset happened in two consecutive pregnancies, disappearing after delivery.<sup>7</sup> Other possibilities are post-traumatic hyperplastic vascular reaction or alteration in supporting factor of angiogenesis, as observed in a patient who had received liver transplantation with ensuing spontaneous development of lesions.<sup>8</sup> In the present case, as in most cases, the condition appeared spontaneously, with no apparent triggering factor.

Tufted angioma is clinically characterized by the presence of stains, papules and plaques of red-violet color, with a tendency to increase in size, many times very quickly, to then stabilize. Spontaneous

regression may then follow.<sup>7</sup> It is generally located in trunk and limbs.<sup>2</sup>

Onset of tufted hemangioma usually occurs in the first two decades of life, specially during the first year. Other clinical findings include increase in local sensitivity, and, more rarely, hyperhidrosis and hypertrichosis.<sup>9</sup> All clinical and epidemiological data of the present patient agree to those in literature.

In the case of tufted hemangioma in children, differential diagnosis is clinically made with childhood hemangioma, which is usually soft and not painful to palpation, and, more rarely, with hemangioendothelioma, infantile hemangiopericytoma and infantile myofibroma.<sup>9</sup> When in adults, vascular tumors such as Kaposi's sarcoma and angiosarcoma should be discarded.<sup>10</sup>

Diagnosis is generally based on the histological picture, very typical in tufted hemangioma, presenting a lobular pattern of densely distributed capillaries with the aspect of a “cannon bullet”.<sup>2</sup> Vascular tufts are constituted by long hypertrophied endothelial cells, very next one to the other, which makes it hard to define the lumen of the capillary. Endothelial cell nuclei are regular, round, egg-shaped or fusiform. This allows differentiation from other vascular pathologies with relative safety. Immunohistochemistry (CD 34+) is not necessary for diagnostic confirmation, even though it helps in the confirmation of the vascular origin.

There are few reports of effective treatments for tufted hemangioma in the literature. Apparently, surgical excision, when feasible, is the best option, with high success and low relapse rates.<sup>2</sup> In the present case, tumor extension was a contra-indication for such a procedure.

Other options are steroids, both systemically in high doses and topically (clobetasol propionate at 0,05%),<sup>6</sup> with little size reduction of the lesions, and some improvement in pain. Attempts to make intralesional steroid infiltration, in this case, were not unviable due to local pain produced, making treatment evaluation impossible.

Use of  $\alpha$ -interferon, either systemically or intralesionally, is still controversial, either with good or no therapeutical results.<sup>10</sup>

Pulsed-dye laser promotes selective vascular destruction with minimal aggression to surrounding skin. Thus, capillary tufts in these case could serve as a target for the laser.<sup>11</sup> Even though this is a rare disease, five cases of treatment with pulsed-dye laser for tufted hemangioma have been described, with variable results – in two of them with good response,<sup>11,12</sup> and with complete failure in three others.<sup>1,13,14</sup> Yet, because it is a relatively safe method, with few side effects, the main being post-inflammatory hyperpig-

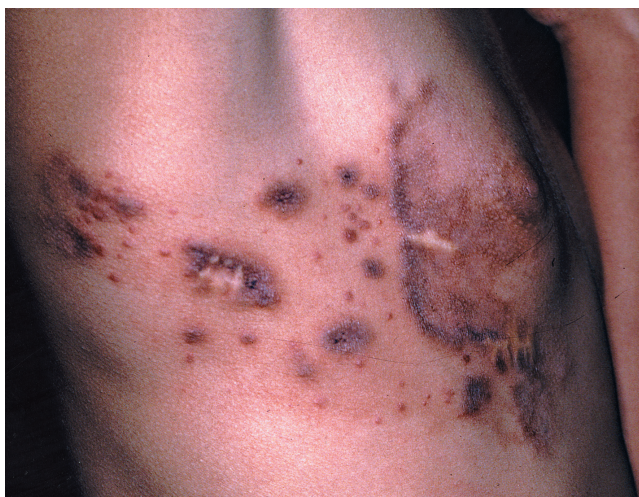

FIGURE 3: Lesion after treatment with pulsed-dye laser. Initial reduction on right breast and appearing of new papules



mentation, which regresses later on,<sup>15</sup> such therapy was chosen.

The use of pulsed-dye laser was efficient in reducing pain, but the same success was not obtained with lesion size, in spite of the slight improvement. As there are few reports of treatment with pulsed-dye laser, it is still early to state a clear opinion on the

indication of such laser for the treatment of tufted angioma. However, it can be stated that the improvement in pain justified its use. In this case, there were no side effects, only pain during application of the method, which reinforces its safety. □

## REFERENCES

1. Bernstein EF, Kantor G, Howe N, Savit RM, Koblenzer PJ, Uitto J. Tufted angioma of the thigh. *J Am Acad Dermatol.* 1994;31:307-11.
2. Jones EW. Malignant vascular tumors. *Clin Exp Dermatol.* 1976;1:287-312.
3. Ban M, Kamiya H, Kitajima Y. Tufted angioma of adult onset, revealing abundant eccrine glands and central regression. *Dermatology.* 2000;201:68-70.
4. Issa MCA, Rochael MC, Peçanha MAP. Angioma adquirido em tufos. *An Bras Dermatol.* 1997;72:363-6.
5. Kakagawa K. Case report of angioblastoma of the skin. *J Dermatol.* 1949;59:92-4.
6. Alessi E, Bertani E, Sala F. Acquired tufted angioma. *Am J Surg Pathol.* 1986;8:426-9.
7. Kim YK, Kim HJ, Lee KG. Acquired tufted angioma associated with pregnancy. *Clin Exp Dermatol.* 1992;17:458-9.
8. Chu P, LeBoit PE. An eruptive vascular proliferation resembling acquired tufted angioma in the recipient of a liver transplant. *J Am Acad Dermatol.* 1992;26:322-5.
9. Wong SN, Tay YK. Tufted angioma: a report of five cases. *Pediatr Dermatol.* 2002;19:388-93.
10. Munn SE, Jackson JE, Jones RR. Tufted haemangioma responding to high-dose systemic steroids: a case report and review of the literature. *Clin Exp Dermatol.* 1994;19:511-4.
11. Mahendran R, White SI, Clark AH, Sheehan-Dare RA. Response of childhood tufted angioma to the pulsed-dye laser. *J Am Acad Dermatol.* 2002;47:620-2.
12. Frenk E, Vion B, Merot Y, Alvero H, Ruffieux C. Tufted angioma. *Dermatologica.* 1990;181:242-3.
13. Dewerdts S, Callens A, Machet L, Grangeponce MC, Vaillant L, Lorette G. Angiome en touffes acquis de l'adulte: échec du traitement par laser à colorant pulsé. *Ann Dermatol Venereol.* 1998;125:47-9.
14. Descours H, Grezard P, Chouvet B, Labeille B. Angiome en touffes acquis de l'adulte. *Ann Dermatol Venereol.* 1998;125:44-6.
15. Seukeran DC, Collins P, Sheehan-Dare RA. Adverse reactions following pulsed tunable dye laser treatment of port wine stains in 701 patients. *Br J Dermatol.* 1997;136:725-9.

---

### MAILING ADDRESS:

Alberto Eduardo Oiticica Cardoso  
Rua Ponta Delgada, 76 - Apto 182 - Vila Olímpia  
04548-020 - São Paulo - SP - Brazil  
Tel.: +55 (11) 8147-8946  
E-mail: albertooiticica@hotmail.com