

## Zoon's plasma cell balanitis: a report of two cases treated with pimecrolimus

Balanite plasmocitária de Zoon: relato de dois casos tratados com pimecrolimo

Livia Delgado<sup>1</sup>  
Damaris G. Ortolan<sup>1</sup>  
Paulo Ricardo Criado<sup>3</sup>

Hebert Roberto Clivati Brandt<sup>1</sup>  
Régia Celli Ribeiro Patriota<sup>2</sup>  
Walter Belda Junior<sup>4</sup>

**Abstract:** Initially called (in French) "Balanoposthite chronique circonscrite benigne a plasmocytes", Zoon's plasma cell balanitis is a chronic inflammatory dermatosis affecting the glans and foreskin of uncircumcised men. The different treatment options for this condition often present partial results. Reports have shown therapeutic success using topical tacrolimus. We report the use of pimecrolimus, a homologue of tacrolimus, with good response. Two male patients diagnosed with Zoon's plasma cell balanitis, confirmed by biopsy, were subjected to daily treatment with topical pimecrolimus 1%. Significant improvement was noted in patient 1 after 6 weeks and after 8 weeks in patient 2. Conclusion: Pimecrolimus cream may be an option for the treatment of this disease.

**Keywords:** Balanites; Calcineurin; Male urogenital diseases; Treatment outcome

**Resumo:** Inicialmente, denominada "Balanoposthite chronique circonscrite benigne a plasmocytes", a balanite plasmocitária de Zoon é uma dermatose inflamatória crônica da glande e prepúcio afetando homens não circuncidados. As diferentes opções de tratamento para esta afecção apresentam frequentemente resultados parciais. Relatos têm demonstrado sucesso terapêutico, com o uso de tacrolimo tópico. Relatamos o uso de pimecrolimus, um homólogo de tacrolimo, com boa resposta. Dois doentes do sexo masculino, com diagnóstico de Balanite de Zoon confirmado através de biópsia, foram submetidos a um tratamento diário com pimecrolimus tópico a 1%, com importante melhora da doença após 6 semanas para o paciente, 1 e 8 semanas para o 2. Conclusão: O pimecrolimus em creme pode ser uma opção para o tratamento da doença.

**Palavras-chave:** Balanites; Calcineurina; Doenças urogenitais masculinas; Resultado de tratamento

Received on 01.03.2011.

Approved by the Advisory Board and accepted for publication on 07.04.2011.

\* Study undertaken at: Sexually Transmitted Diseases Clinic of the Department of Dermatology, Faculty of Medicine, University of São Paulo (FMUSP), São Paulo (SP), Brazil.

Conflict of interest: None / *Conflito de interesse: Nenhum*

Financial funding: None / *Suporte financeiro: Nenhum*

<sup>1</sup> Dermatologist, Department of Dermatology, Faculty of Medicine, University of São Paulo (FMUSP), São Paulo (SP), Brazil.

<sup>2</sup> Residency in Dermatology, Faculty of Medicine, University of São Paulo (FMUSP, São Paulo (SP), Brazil.

<sup>3</sup> Master's Degree in Dermatology awarded by the Faculty of Medicine (Department of Dermatology), University of São Paulo (USP); MD in the Clinical Dermatology Department, Faculty of Medicine Hospital das Clinicas, University of São Paulo (HC-FMUSP, São Paulo (SP), Brazil.

<sup>4</sup> Dermatologist, PhD in science (specialization in dermatology) awarded by the Faculty of Medicine, University of São Paulo (FMUSP); Assistant in the Clinical Dermatology Department and researcher at the Medical Research Laboratory LIM 53, Faculty of Medicine Hospital das Clinicas, University of São Paulo (HC-FMUSP); responsible for the Vasculitis Outpatients Clinic of the Hospital das Clinicas Faculty of Medicine, University of São Paulo (HC-FMUSP), São Paulo (SP), Brazil.

<sup>5</sup> PhD in Medicine awarded by the Faculty of Medicine, University of São Paulo (USP); Associate Professor in Dermatology Department, University of Campinas (Unicamp); Responsible for the STD/AIDS Department of the Brazilian Dermatology Society; Professor at the Department of Dermatology, Faculty of Medicine, University of São Paulo (FMUSP), São Paulo (SP), Brazil.

## INTRODUCTION

Zoon's plasma cell balanitis is a genital inflammatory dermatosis generally occurring in uncircumcised elderly males.<sup>1,2</sup> Clinically the disease is characterized by the presence of a single, well-demarcated, bright red or reddish-brown plaque affecting the glans and inner foreskin<sup>3,4</sup>. It is a benign condition of unknown etiology that tends to be asymptomatic.<sup>1,2,3</sup>

While circumcision is considered to produce the best treatment results it is rejected by the majority of patients. Other treatment modalities often present partial results<sup>5</sup>.

Recent reports have shown a favorable response in patients treated with topical tacrolimus 0.03%.<sup>1,2,3,6</sup>

We report the use of pimecrolimus 1% cream, a homologue of tacrolimus, in two patients, with good response.

## CASE REPORT

**Case 1:** Male, 37 years old, uncircumcised, was referred to the STD Clinic with a 1 year history of genital lesions and no prior treatment. A dermatological examination indicated the presence of three shiny, well-defined, reddish plaques on the glans and foreskin (Figure 1).

Histopathology with punch biopsy of one of the lesions on the glans showed a strip of infiltrate rich in plasma cells in the papillary dermis, confirming the diagnosis of Zoon's plasma cell balanitis (Figure 2).

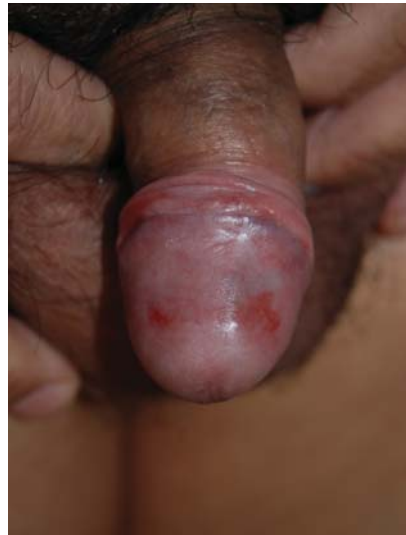The patient was treated with pimecrolimus 1% cream, with significant improvement after 6 weeks of treatment. Improvement was maintained over the 3-month follow-up period (Figure 3).

**Case 2:** Male, 62 years old, uncircumcised, was referred to the Clinic, with a 1 year history of genital lesions and no prior treatment. Dermatological exam showed a well delimited reddish plaque on the glans (Figure 4). Histopathology of a biopsy made of one lesion on the glans, confirmed the diagnosis of Zoon's plasma cell balanitis.

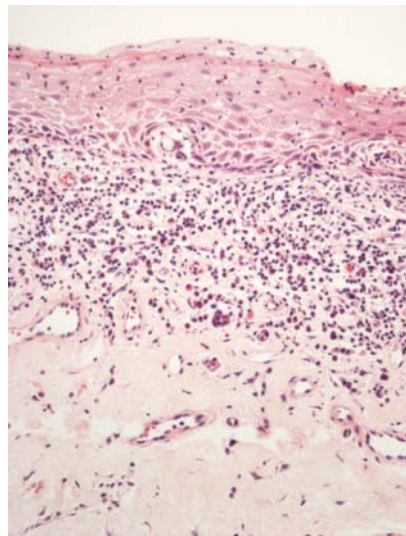
The patient was treated with pimecrolimus 1% cream and showed significant improvement after 8 weeks. Improvement was maintained over the 3-month follow-up period (Figure 5).

## DISCUSSION

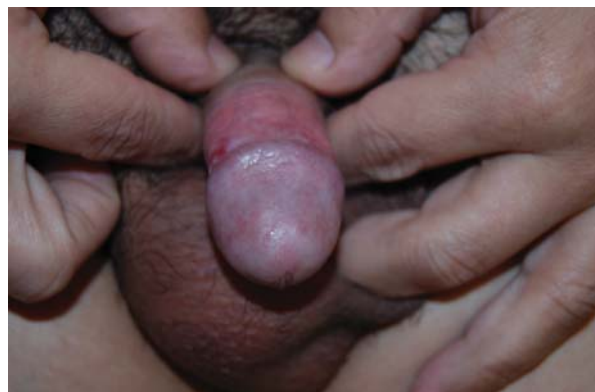Zoon's plasma cell balanitis is a chronic inflammatory disease of the genital tract of unknown etiology. A number of predisposing factors proposed are nevertheless unproven: friction, trauma, heat, poor hygiene, chronic infection with *Mycobacterium smegmatis*, reaction to an unknown exogenous infectious factor, hypospadias and an immune response mediated by IgE.<sup>1,2</sup>



**Figure 1:** Case 1 before treatment: well-demarcated erythematous plaques of the glans and foreskin. Photo before treatment



**Figure 2:** Histologic examination: Lymphocytic balanitis rich in plasma cells



**FIGURE 3:** Case 1 after treatment: total remission of lesions after six weeks of commencing treatment

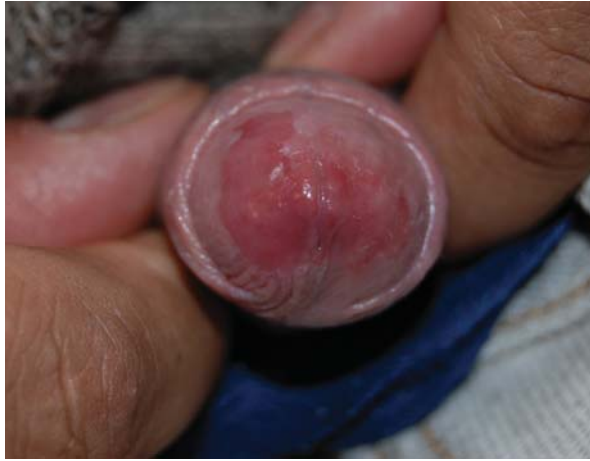

FIGURE 4: Case 2 before treatment: erythematous plaque of the glans before treatment

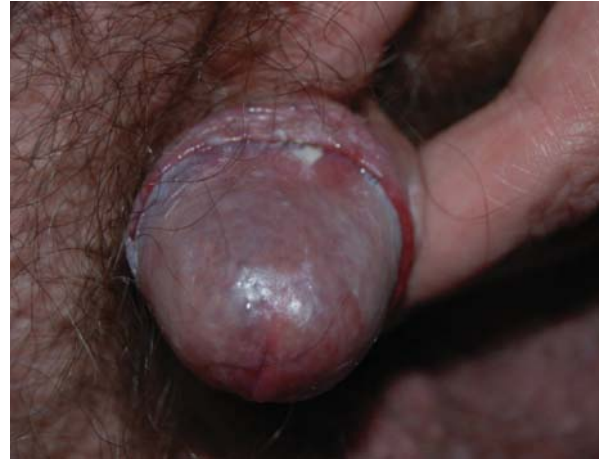

FIGURE 5: Case 2 after treatment: remission of the lesion 8 weeks after commencing treatment

The condition is relatively common in elderly men and presents clinically as well-demarcated, erythematous, shiny plaques on the glans, coronal sulcus or the inner surface of the foreskin.<sup>4</sup>

Histologically, the process begins with a slight thickening of the epidermis, with parakeratosis and a characteristic band-like lymphocytic infiltrate of rare *plasma cells* in the upper dermis.<sup>3,4</sup> As the disease progresses, atrophy of the epidermis, superficial erosions and a denser plasma cell infiltration appear.<sup>4</sup>

The main differential diagnosis should be performed with *Erythroplasia of Queyrat*, an early pre-malignant form of skin cancer found on the penis, which is clinically similar but histologically different.<sup>7</sup>

Regarding therapy, while circumcision is a highly effective treatment it is rejected by most patients. As an alternative, partial results can be obtained with the use of corticosteroid creams.<sup>1,3,5,8</sup>

Recent reports indicate that tacrolimus ointment can be used with good response and in some cases remission.<sup>1,2,3,6</sup> This drug is a potent anti-inflammatory agent which acts by inhibiting the protein phosphatase calcineurin, preventing the *transcriptional* induction of *numerous cytokines*.<sup>2</sup>

Pimecrolimus, a calcineurin inhibitor which is a homologous counterpart of tacrolimus, has also been used for treatment by Bardazzi *et al*<sup>9</sup> in two patients with good response, and by Stinco *et al*<sup>10</sup> in three cases, with different results: one patient had complete remission, one partial remission and another had to cease treatment on account of an alleged recurrent herpetic infection.

Our results help to confirm that pimecrolimus cream is a good alternative for treating Zoon's plasma cell balanitis. □

**REFERENCES**

1. Roé E, Dalmau J, Peramiqnel L, Pérez M, López-Lozano HE, Alomar A. Plasma cell balanitis of zoon treated with topical tacrolimus 0.1%: report of three cases. *J Eur Acad Dermatol Venereol.* 2007;21:284-5.
2. Moreno-Arias GA, Camps-Fresneda A, Llaberia C, Palou-Almerich J. Plasma cell balanitis treated with tacrolimus 0,1%. *Brit J Dermatol.* 2005;153:1204-6.
3. Hernandez-Machin B, Hernando LB, Marrero OB, Hernandez B. Plasma cell balanitis of Zoon treated successfully with topical tacrolimus. *Clin Exp Dermatol.* 2005;30:588-9.
4. Weyers W, Ende Y, Schalla W, Diaz-Cascajo C. Balanitis of Zoon: A Clinicopathologic Study of 45 Cases. *Am J Dermatopathol.* 2002;24:459-67.
5. Kumar B, Sharma R, Rajagopalan M, Radotra BD. Plasma cell balanitis: clinical and histopathological features-response to circumcision. *Genitourin Med.* 1995;71:32-4.
6. Santos-Juanes J., Sánchez del Río J., Galache C, Soto J. Topical Tacrolimus: an effective therapy for zoon balanitis. *Arch Dermatol.* 2004;140:1538-9.
7. Reis VMS, Moraes Junior O, Almeida FA. Balanite plasmocelular de Zoon. *An Bras Dermatol.* 1983;58:173-4.
8. Tang A., David N., Horton LWL. Plasma cell balanitis of Zoon: response to Trimovate cream. *Int J STD & AIDS.* 2001;12:75- 8.
9. Bardazzi F, Antonucci A, Savoia F, Balestri R. Two cases of Zoon's balanitis treated with pimecrolimus 1% cream. *Int J Dermatol.* 2008;47:198-201.
10. Stinco G, Piccirillo F, Patrone P. Discordant results with pimecrolimus 1% cream in the treatment of plasma cell balanitis. *Dermatology.* 2009;218:155-8.

---

**MAILING ADDRESS / ENDEREÇO PARA CORRESPONDÊNCIA:****Livia Delgado****Av. Dr. Enéas Carvalho de Aguiar, 255 - 3º andar****CEP: 05403 000 - São Paulo – SP, Brazil****E-mail: paralivi@hotmail.com**

How to cite this article/*Como citar este artigo*: Delgado L, Brandt HR, Ortolan DG, Patriota RC, Criado PR, Belda Junior W. Zoon's plasma cell balanitis: a report of two cases treated with pimecrolimus. *An Bras Dermatol.* 2011;86(4 Supl 1):S35-8.

*An Bras Dermatol.* 2011;86(4Supl1):S35-8.