

## References

1. Malissen N, Fabre C, Joux JM, Bourquard P, Dandurand M, Marque M, et al. Multiple primary cutaneous plasmacytoma. *Ann Dermatol Venereol*. 2014;141:364–8.
2. Kazakov DV, Belousova IE, Müller B, Palmedo G, Samtsov AV, Burg G, et al. Primary cutaneous plasmacytoma: a clinicopathological study of two cases with a long-term follow-up and review of the literature. *J Cutan Pathol*. 2002;29:244–8.
3. Tsang DS, Le LW, Kukreti V, Sun A. Treatment and outcomes for primary cutaneous extramedullary plasmacytoma: a case series. *Curr Oncol*. 2016;23:e630–46.
4. Requena L, Kutzner H, Palmedo G, Calonje E, Requena C, Pérez G, et al. Cutaneous involvement in multiple myeloma: a clinicopathologic, immunohistochemical, and cytogenetic study of 8 cases. *Arch Dermatol*. 2003;139:475–86.
5. Rongioletti F, Patterson JW, Rebora A. The histological and pathogenetic spectrum of cutaneous disease in monoclonal gammopathies. *J Cutan Pathol*. 2008;35:705–21.

Giuseppe Broggi <sup>a,\*</sup>, Enrica Martino <sup>b</sup>,  
Valeria Calafiore <sup>b</sup>, Rosario Caltabiano <sup>a</sup>

<sup>a</sup> Department Gian Filippo Ingrassia, Section of Anatomic Pathology, University of Catania, Catania, Italy

<sup>b</sup> Division of Hematology, Azienda Ospedaliero-Universitaria Policlinico-Vittorio Emanuele, Catania, Italy

\* Corresponding author.

E-mail: [giuseppe.broggi@gmail.com](mailto:giuseppe.broggi@gmail.com) (G. Broggi).

Received 30 November 2018; accepted 1 April 2019;

Available online 7 November 2019

<https://doi.org/10.1016/j.abd.2019.04.004>

0365-0596/ © 2019 Sociedade Brasileira de Dermatologia.

Published by Elsevier España, S.L.U. This is an open access article under the CC BY license (<http://creativecommons.org/licenses/by/4.0/>).

## Perforating necrobiosis lipoidica: good response to adalimumab<sup>☆,☆☆</sup>

Dear Editor,

Necrobiosis lipoidica (NL) is a rare granulomatous dermatosis of unknown origin, often related to diabetes mellitus (DM).<sup>1,2</sup> The perforating form of necrobiosis lipoidica (PNL) is even more infrequent, affecting mainly adults between 30 and 60 years, particularly women. The clinical lesion consists of coalescing plaques, of various diameters, in the classical localization of NL. The presence of keratotic “plugs,” which leave small depressions in the tissue when removed, is characteristic.<sup>2</sup> Histologically, there is the elimination of the necrobiotic material through the follicular canal, in addition to the “palisade” granulomas with collagen necrobiosis.

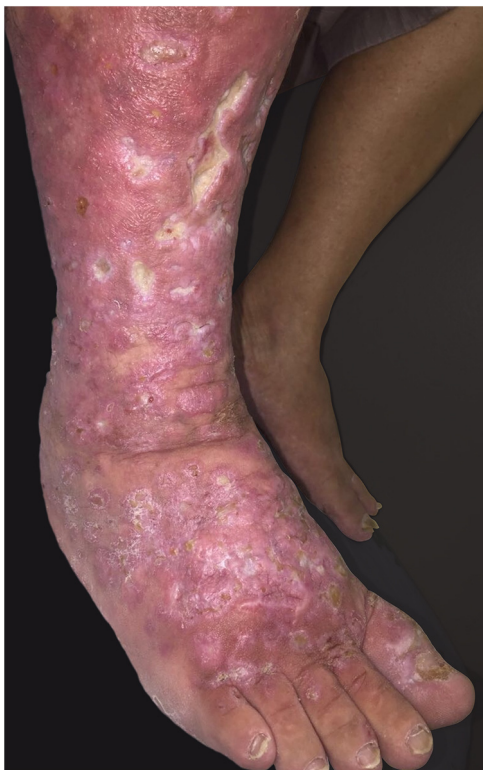This report details the case of a male patient, 65 years old, who referred to the appearance of papules and plaques initially in the right forearm a year ago, and three months later, in the scapular region and right leg, with pustules, edema, and erythema to proximal third of the right leg, accompanied by discreet pruritus and local discomfort. The patient has arterial hypertension and depressive disorder, and uses losartan, fluoxetine, and diosmin. He is a former smoker, while denying alcoholism and other comorbidities. The dermatological examination showed erythematous, infiltrated, annular-like plaques with ulcerated areas and fibrin on the inside of both legs, the right foot, and right arm (Fig. 1). Serological tests were negative and fasting glycemia was within normal limits. The bacilloscopy

was negative for leprosy. The culture was negative for *Histoplasma capsulatum*, *Paracoccidioides brasiliensis*, and other fungi. The chest X-ray was unaltered, as were the right leg and foot X-ray. Histopathological examination revealed palisade granuloma, consisting of epithelioid histiocytes and multinucleated giant cells, centered by fibrinoid necrosis, with some neutrophils and signs of vascular damage in the dermis (Fig. 2). In the sample of the left scapular region, there was an area of epidermal perforation that communicated to the granuloma area. The search for fungi and BAAR by histochemical staining of PAS, Grocott and Ziehl-Neelsen and *M. tuberculosis* by polymerase chain reaction (PCR) were negative. The patient used rifampicin 300 mg 12/12 h and clindamycin 300 mg 12/12 h for ten weeks, presenting partial improvement of the lesions. Therefore, it was decided to start prednisone 20 mg per day, methotrexate 20 mg per week, folic acid 10 mg per week, and moisturizing dressing with calcium alginate and sodium and clobetasol daily. In two months of evolution, he presented little improvement, thus it was decided to initiate injections of adalimumab 40 mg weekly; after five months of evolution, the patient presented significant improvement of the lesions, remaining only with scars (Fig. 3).

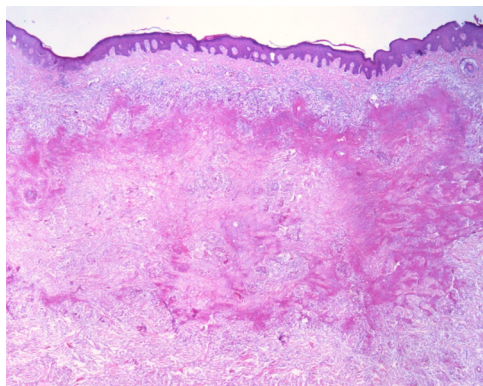
The treatment of NL and PNL is difficult and often frustrating,<sup>2</sup> based on reports of few cases, due to the rarity of the disease. The literature describes a broad therapeutic arsenal, ranging from local treatments such as tacrolimus, in addition to PUVA, photodynamic therapy, and systemic anti-inflammatory drugs and immunomodulators; in this context, TNF- $\alpha$  inhibitors show good effectiveness in controlling the formation of granulomas.<sup>1,2</sup> Adalimumab is a monoclonal antibody that binds to soluble TNF- $\alpha$  to prevent its interaction with TNF receptors on cell surfaces, thereby fixing the complement and inducing apoptosis in cells expressing TNF *in vitro*.<sup>3</sup> A case study by Zhang et al. treated NL in a 29-year-old woman for 12 months using etanercept and injectable adalimumab, but they recorded more significant improvement with etanercept, with no reported side effects. Chung et al. presented a case of a rheumatoid arthritis patient who developed an NL lesion even

<sup>☆</sup> How to cite this article: Mattos ABN, Brummer CF, Funchal GD, Nunes DH. Perforating necrobiosis lipoidica: good response to adalimumab. *An Bras Dermatol*. 2019;94:769–71.

<sup>☆☆</sup> Study conducted at the Hospital Universitário Polyodoro Ernani de São Thiago, Universidade Federal de Santa Catarina, Florianópolis, SC, Brazil.

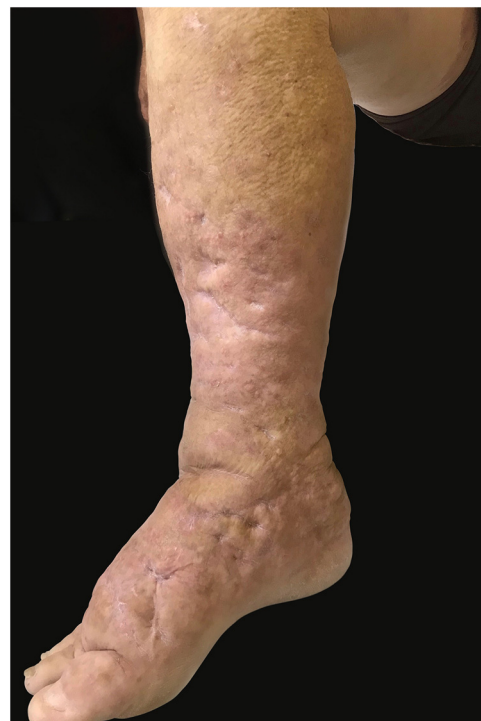

**Figure 1** Infiltrated, ring-shaped, erythematous plaques with ulcerations, on the right leg and foot.



**Figure 2** Histopathological examination shows palisade granuloma, consisting of epithelioid histiocytes and multinucleated giant cells, centered by fibrinoid necrosis, with some neutrophils and signs of vascular damage in the dermis. (Hematoxylin & eosin,  $\times 40$ ).

when using adalimumab, who was treated with topical and intralesional corticosteroids and maintenance of previous medication, with improvement of the lesions.<sup>4</sup> Leister et al. demonstrated the case of a 71-year-old man with NL with complete improvement after 12 weeks of adalimumab, who underwent a total period of 15 months of treatment and sustained response up to five months after the end of treatment, when the results were published.<sup>5</sup> The present patient presented improvement after five months while using adalimumab without side effects up to the present moment, one and a half years after starting the medication. Based



**Figure 3** Aspect of lesions after five months of treatment with adalimumab.

on these cases, together with this report, it is possible to understand the complex role of TNF- $\alpha$  in the recruitment of histiocytes and formation of granulomas, which may help to focus future prospective NL treatments on this subset of patients.

### Financial support

None declared.

### Author contribution

Alexandra Brugnera Nunes de Mattos: Composition of the manuscript; participation in the design of the study; critical review of the manuscript.

Carolina Finardi Brummer: Conception and planning of the study; composition of the manuscript; participation in the design of the study.

Gabriela Di Giunta Funchal: Critical review of the literature; critical review of the manuscript.





Daniel Holthausen Nunes: Intellectual participation in the propaedeutic and/or therapeutic conduct of the studied cases; critical review of the manuscript.

### Conflicts of interest

None declared.

### References

1. Peckruhn MD, Tittelbach J, Elsner P. Update: treatment of necrobiosis lipoidica. *J Dtsch Dermatol Ges.* 2017;15:151–7.
2. Hammami H, Youssef S, Jaber K, Dhaoui MR, Doss N. Perforating necrobiosis lipoidica in a girl with type 1 diabetes mellitus: a new case reported. *Dermatol Online J.* 2008;14:11.
3. Zhang KS, Quan LT, Hsu S. Treatment of necrobiosis lipoidica with etanercept and adalimumab. *Dermatol Online J.* 2009;15:12.
4. Chung CG, Rosengrant A, Helm KF, Shupp DL. Necrobiosis lipoidica occurring in a patient with rheumatoid arthritis on concurrent tumor necrosis factor- $\alpha$  inhibitor therapy. *Int J Dermatol.* 2015;54:1294–6.
5. Leister L, Körber A, Dissemond J. Successful treatment of a patient with ulcerated necrobiosis lipoidica non diabeticorum with adalimumab. *Hautarzt.* 2013;64:509–11.

Alexandra Brugnera Nunes de Mattos <sup>a,\*</sup>,  
 Carolina Finardi Brummer <sup>a</sup>,  
 Gabriela Di Giunta Funchal <sup>b</sup>,  
 Daniel Holthausen Nunes <sup>c</sup>

<sup>a</sup> *Dermatology Service of the Hospital Universitário Polyodoro Ernani de São Thiago, Universidade Federal de Santa Catarina, Florianópolis, SC, Brazil*

<sup>b</sup> *Pathology and Dermatology Service of the Hospital Universitário Polyodoro Ernani de São Thiago, Department of Pathology of Universidade Federal de Santa Catarina, Florianópolis, SC, Brazil*

<sup>c</sup> *Dermatological Medical Residency Program in Dermatology of the Hospital Universitário Polyodoro Ernani de São Thiago, Universidade Federal de Santa Catarina, Florianópolis, SC, Brazil*

\*Corresponding author.

E-mail: [anunes12@hotmail.com](mailto:anunes12@hotmail.com) (A.B. Nunes de Mattos).

Received 23 August 2018; accepted 18 April 2019;

Available online 4 November 2019

<https://doi.org/10.1016/j.abd.2019.04.003>

0365-0596/ © 2019 Sociedade Brasileira de Dermatologia.

Published by Elsevier España, S.L.U. This is an open access article under the CC BY license (<http://creativecommons.org/licenses/by/4.0/>).

## Squamous cell carcinoma of the vulva diagnosed by a dermatologist<sup>☆,☆☆</sup>

Dear Editor,

Vulvar cancer is considered a rare disease, accounting for approximately 4% of all female genital neoplasms, and squamous cell carcinoma is the most prevalent, accounting for 90% of malignant tumors in this region, followed by melanoma. Its incidence is higher in the elderly population, with a worldwide incidence of approximately 1.8/100,000 women, increasing to 20/100,000 after the age of 75 years.<sup>1–4</sup>

A female patient, 82 years old, from Bauru-SP, was referred to the dermatology department with complaint of pruritus and a lesion in the genital region two months previously. Hypertension, hypothyroidism, and diabetes were reported as comorbidities. Widowed 14 years ago, she denied sexual activity ever since.

On examination of the genital region, erythema and edema of the entire labia majora were found, and an ulcerative nodule approximately 1.7 cm in diameter was found in the region of the labia minora (Fig. 1).

An incisional biopsy was performed, showing a well-differentiated, invasive, ulcerated squamous cell carcinoma (Fig. 2). HPV screening for genome amplification was negative (Table 1). The patient was referred to the oncology department for treatment at a referral hospital.

Squamous cell carcinoma of the vulva usually presents as a solitary nodule or ulcer on the labia majora or minora, with associated pain, bleeding, itching, odor, or discharge. Among the causative factors involved in its pathogenesis are smoking, HPV infection, and precursor lesions such as lichen-sclerotic atrophy and incipient vulvar carcinomas – now called vulvar intraepithelial neoplasms – also related to HPV.<sup>2</sup>

Morphological variants have been described, including basaloid and verrucoid subtypes, which are related to viral infection and are more common in the young population, whereas keratinizing variants tend to be HPV-negative and occur in elderly women.<sup>1</sup>

The staging is performed by the TNM system. Tumors diagnosed early, up to stage T1a, can be treated only with resection of the lesion with at least 1 cm of margin, with survival rates at five and ten years around 100% and 94.7%, respectively. From the T1b stage, tumors from 2 cm with stromal invasion of at least 1 mm may require partial or total vulvectomy, with ipsilateral or bilateral lymph node dissection. Since lymphatic dissemination is the most important prognostic factor, histopathological study of regional lymph nodes is essential in cases of invasive tumors. If lymph node invasion is confirmed, chemotherapy and additional radiation therapy may be required.<sup>3,5</sup>

Treatment in the early stages has better results, both esthetic-functional and in terms of overall survival, presenting a high cure rate; however, it occurs in a very low percentage of women affected, since in general they seek medical services late and professionals delay in making the diagnosis.

The dermatological literature lacks of scientific articles of the neoplasms of the female genital epithelium; the present report attempts to demonstrate the importance of the anamnesis and the dermatological examination of this anatomical region in order to make an early diagnosis.

<sup>☆</sup> How to cite this article: Michels IB, Tonello CS, Soares CT. Squamous cell carcinoma of the vulva diagnosed by a dermatologist. *Am Bras Dermatol.* 2019;94:771–2.

<sup>☆☆</sup> Study conducted at the Instituto Lauro de Souza Lima, Bauru, SP, Brazil.