

# Papillary thyroid cancer case masked by subacute thyroiditis

*Caso de carcinoma papilar de tiroide mascarado por tireoidite subaguda*

Bekir Ucan<sup>1</sup>, Tuncay Delibasli<sup>1</sup>, Erman Cakal<sup>1</sup>, Muyesser Sayki Arslan<sup>1</sup>, Nujen Colak Bozkurt<sup>1</sup>, Taner Demirci<sup>1</sup>, Mustafa Ozbek<sup>1</sup>, Mustafa Sahin<sup>2</sup>

## SUMMARY

Subacute thyroiditis (SAT) association with thyroid carcinoma has been rarely reported in the literature. We present a patient with SAT and papillary thyroid cancer that was suspected by ultrasonographic evaluation (US) following SAT treatment. A fifty-four-year old female patient referred to our department due to tachycardia, jitteriness and pain in cervical region for the past one month. SAT diagnosis was established by physical examination, laboratory and ultrasonographic findings. After treatment, control thyroid US revealed regression of the hypoechogenic regions seen in both lobes, and a previously unreported hypoechogenic lesion with microcalcification focus that had irregular borders and was not clearly separated from the surrounding parenchyma located in the posterior aspect of the lobe (Elasto score: 4, Strain index: 7.08). Fine needle aspiration biopsy was taken from this nodule; cytology was assessed to be compatible with papillary thyroid carcinoma. Postsurgical pathology evaluation showed a papillary microcarcinoma. SAT may produce ultrasound changes that obscure the coexistence of papillary carcinoma. We recommend that patients with SAT have ultrasonography after they recover. Hypoechogenic regions bigger than 1 cm that are present in the follow-up post-therapy US should be assessed by biopsy. *Arq Bras Endocrinol Metab.* 2014;58(8):851-4

<sup>1</sup> Diskapi Yildirim Beyazit Training and Research Hospital, Department of Endocrinology and Metabolism, Ankara, Turkey  
<sup>2</sup> Ankara University, School of Medicine, Department of Endocrinology and Metabolism, Ankara, Turkey

## SUMÁRIO

A associação da tireoidite subaguda (TSA) com o carcinoma de tiroide foi raramente relatada na literatura. Apresentamos uma paciente com TSA e tumor papilar de tiroide suspeito na ultrassonografia (US) após o tratamento para a TSA. Uma mulher de 54 anos de idade foi encaminhada ao nosso departamento com taquicardia, agitação e dor na região cervical, com duração de 1 mês. O diagnóstico de TSA foi estabelecido pelo exame físico, e pelos achados laboratoriais e ultrassonográficos. Depois do tratamento, o US para controle da tiroide mostrou regressão das regiões hipoeoicas vistas em ambos os lobos e uma lesão hipoeoica anteriormente não observada com focos de microcalcificação, bordas irregulares, não claramente separada do parênquima circundante e localizada na região posterior do lobo. (Escore elástico: 4, índice de deformação: 7,08). Foi feita uma biópsia do nódulo por meio de aspiração por agulha fina. A citologia mostrou-se compatível com um carcinoma papilar de tiroide. A avaliação pós-cirúrgica mostrou um microcarcinoma papilar. A TSA pode produzir alterações ultrassonográficas que obscurecem a coexistência de carcinoma papilar. Recomendamos que pacientes com TSA passem por exame ultrassonográfico após a recuperação. Regiões hipoeoicas maiores que 1 cm encontradas no US para acompanhamento pós-tratamento devem ser avaliadas por biópsia. *Arq Bras Endocrinol Metab.* 2014;58(8):851-4

## Correspondence to:

Bekir Ucan  
 Diskapi Yildirim Beyazit Training and Research Hospital, Department of Endocrinology and Metabolism, Ankara, Turkey  
 uzm.dr.bekir@hotmail.com.tr

Received on Jan/12/2014  
 Accepted on Mar/11/2014

DOI: 10.1590/0004-2730000003222

## INTRODUCTION

Subacute thyroiditis (SAT) is one of the inflammatory thyroid diseases known as de Quervain's disease. This disease affects women three to five times more often than men. In addition to that, viral infection is

the most common cause of this disease (1,2). SAT is generally clinically diagnosed after evaluating both the clinical and laboratory data (3). This self-limited disease often resolves spontaneously or it may improve with anti-inflammatory medications and corticosteroids (4).

Ultrasonography (US) is a useful tool for diagnosing and monitoring thyroid pathology, including subacute thyroiditis. Characteristic ultrasonographic features of thyroiditis are enlargement of thyroid gland, focal hypoechoic zones with indefinite borders or diffuse hypoechoecogenicity, and lack or low flow on color Doppler in these areas (5). These findings usually accompany hard and tender thyroid gland (3). However these ultrasonographic findings are not pathognomic for SAT.

Diffuse hypoechoicity can be seen in Graves' disease and Hashimoto thyroiditis, whereas benign nodules and thyroid carcinomas may present as focal hypoechoic regions (4,5). In pathological examinations, thyroid gland is seen as engorged and edematous in SAT. There is follicular cell destruction and the infiltration of inflammatory cells. These inflammatory cells are neutrophils, lymphocytes, histiocytes and multinuclear giant cells and are seen in the hypoechoic regions determined in the biopsy taken under US guidance. With the regression of the inflammatory process, there are different stages of fibrosis and granuloma formation in the thyroid gland (6).

SAT's association with thyroid carcinoma has been rarely reported in the literature. In this case report, we presented a 54 years old female patient who was diagnosed subacute thyroiditis and papillary thyroid cancer by US evaluation following treatment.

## CASE REPORT

Fifty-four years old female referred to our department due to tachycardia, jitteriness and pain in servical region for the past 1 month. The pain in the neck that radiated to the ear and jaw and was worsening with swallowing. Asthma, gastritis and carpal tunnel syndrome was present in her history. There were no thyroid carcinoma in her family history. In the physical examination, thyroid gland was bilaterally enlarged and hard. Also tenderness was found in the thyroid region by palpation. Thyroid gland was not fixated to the surrounding tissue. No cervical lymph node was apparent.

Her laboratory examinations were as follows; TSH: 0.2 (0.55-4.78 mIU/L), sT4: 1.09 (0.74-1.52), sT3: 3 (2.3-4.2 pg/mL), anti-TPO: 10 (10-35 IU/mL), anti-tg: 72 (0-40 IU/mL), sedimentation rate: 52 (0-20 mm/h), C-reactive protein (CRP): 36.8 (0-8 µg/L), neutrophils 11 (4-10  $10^3/\mu\text{L}$ ), absolute neutrophil 6.34 (2,1-6.1  $10^3/\mu\text{L}$ ), haemoglobin: 12.6 (11.4-16.4 g/dL), and thrombocyte count was 269.000 ( $150-372 10^3/\mu\text{L}$ ).

In the thyroid ultrasonography, bilaterally enlarged, diffuse and tenderness with contact of the probe in the thyroid gland was detected. Moreover, hypoechogenic heterogeneous regions of irregular borders in both thyroid lobes. SAT diagnosis was established by physical examination, laboratory and ultrasonographic findings. Medical therapy was initiated. On the second day of the steroid treatment, there were significant regression in the symptoms and signs of the patient. Steroid treatment was continued for a month with gradual decreases. The patient's control levels were as follows; sedimentation rate 9 mm/h, CRP:1.441 mg/L, TSH: 2 (0.55-4.78 mIU/L), sT4: 0.8 (0.74-1.52 pg/mL), sT3:2.8 (2.3-4.2 pg/mL), neutrophil: 8.3 (1.69-8.3  $10^3/\mu\text{L}$ ). Her control thyroid US revealed regression of the hypoechogenic regions seen in both lobes and a previously unreported hypoechogenic region or nodule with microcalcification focus that had irregular borders and was not clearly separated from the surrounding parenchyma localized in the posterior aspect of the right thyroid lobe (elasto score: 4, strain index: 7,08). The fine needle aspiration biopsy taken from this nodule revealed a malign cytology and was compatible with papillary thyroid carcinoma. Total thyroidectomy and central neck lymph node dissection were planned. Postsurgical pathology evaluation was reported to be papillary microcarcinoma (9 mm).

## DISCUSSION

Subacute granulomatous thyroiditis (SAT) is a self-limiting, painful, non-infectious inflammatory disease of the thyroid gland. Although the etiology of subacute thyroiditis is not completely known, it is assumed to be related to viral infections and genetic factors. Infectious etiology is not clearly proven that no proliferation was found in viral cultures, however viral antibodies were found to be high (7).

Thyroid carcinoma rarely co-exists with subacute thyroiditis. Fatourechi and cols. found no thyroid cancer in 160 SAT patients (8). But there are several case reports about this co-existence worldwide in the literature (9-11).

Ultrasonography provides important clues for diagnosis of SAT however hypoechogenic regions that are typical ultrasonographic findings of subacute thyroiditis are not specific to this disease (12). Hypoechogenicity, nodule shape, tumor margin, hypoechoic rims are important factors in evaluating nodule for thyroid carci-

noma (13). Also ultrasonographic features such as microcalcification and blurred borders are very important for deciding biopsy even there is no obvious nodule. Without any other suspicious clue than diffuse hypoechoic regions, it is very difficult to determine the cooccurrence of SAT and papillary carcinoma. In our case, the presence of microcalcification focus and blurred borders accompanying the hypoechoic regions in the ultrasonography was a red flag.

In the subacute thyroiditis, initial sonographic examination is important, unlike typical findings on the presence of a suspicious lesion should be considered. In other words, at the first ultrasonography may be missed the suspicious lesion. Because, it was difficult to point out the coexistence of papillary carcinoma with SAT, based on no clues other than diffuse hypoechoic area at initial ultrasonographic examination. Nishihara and cols. were also not determined a suspicious lesion at the first ultrasound examination in their study (11).

Thyroid US is useful for the follow-up of patients with subacute granulomatous thyroiditis. The follow-up US findings of SAT were a reduction of an enlarged thyroid volume and a decreased or absent hypoechoic areas. A follow-up US exam is recommended rather than immediately performing fine needle aspiration biopsy (FNAB). However, FNAB is indispensable in cases of lesions that are seen as a focal mass mimicking thyroid malignancy (11). Also, as in our case, control ultrasonography is very important in SAT for undetectable suspicious lesions in first ultrasound.

In a study 15 patients with subacute thyroiditis, Tokuda and cols. have reported that sonographic findings changed during the course of the disease. They have reported the presence of hypoechoic regions during the active phase, and their regression and di-

sappearance when the clinical symptoms ameliorated. They have shown in 3 patients that hypoechoic regions reoccurred with the recurrence of the disease (12). In our case, there was also significant decrease in hypoechoic regions following therapy. This enabled the detection of the suspicious region.

Lymphadenopathy (LAP) might accompany to thyroid carcinoma and SAT. Nishihara and cols. detected that two patients had enlarged and rounded cervical lymph nodes and diffusely hypoechoic areas in their thyroid (11). In our case, there was no LAP accompanying suspicious lesions. Elastography may assist in the diagnosis and monitoring of SAT. Also it may help in deciding biopsy requirement in SAT coexistent with suspicious lesions or nodules.

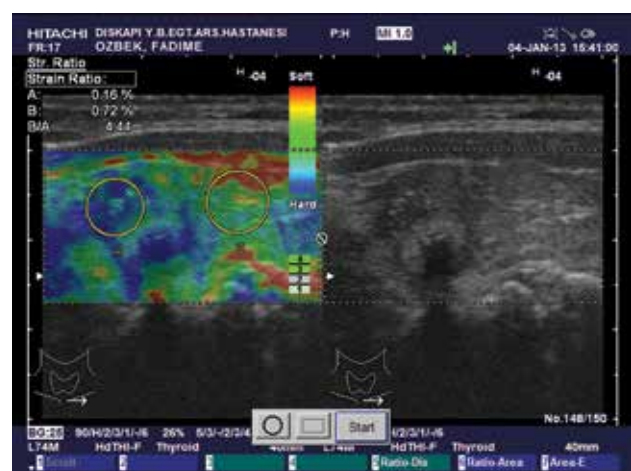
It is also uncertain whether a coexisting thyroid inflammation might influence the result of elastographic evaluation of thyroid focal lesions (14). As cases of coexistence of SAT with nodular goiter or thyroid cancer have been described, it seems best to postpone the assessment of the nodule stiffness until a complete recovery from SAT (11).

In our case, we found a previously unreported suspicious hypoechoic lesion in control thyroid US. This nodule has an increased elastography score and strain index according to uninvolved and other hypoechoic regions. US examination made by an experienced doctor and elastography findings help us to take biopsy decision.

We have reported a case with presentation of diffuse hypoechoic regions in ultrasonography compatible

**Table 1.** Laboratory findings of the patient

	Before treatment	After treatment
TSH (0,55-4,78 mIU/L)	0,2 mIU/L	2 mIU/L
FT4 (0,74-1,52 pg/mL)	1,09 pg/mL	0,8 pg/mL
FT3 (2,3-4,2 pg/mL)	3 pg/mL	2,8 pg/mL
Sedimentation (0-20 mm/sa)	52	9
CRP (0-8 µg/L)	36,8	1,44
Leukocytes (4000-10.000)	11.000	8.300
Absolute neutrophil (2,1-6,1 10 <sup>9</sup> /µL)	6,34	3,8
Anti-Tg (0-40 IU/mL)	72 IU/mL	-
Anti-TPO (10-35 IU/mL)	10 IU/mL	-



**Figure 1.** Longitudinal thyroid ultrasonography and elastography taken when the patient symptoms disappeared with prednisolone treatment, showing a heterogeneous thyroid nodule with microcalcifications and persistent hypoechoic area.

with SAT that masked the papillary carcinoma focus. In conclusion, SAT may accompany to the papillary thyroid carcinoma. Therefore we propose a careful thyroid examination due to the the possibility of SAT and thyroid carcinoma co-existence. Also patients with SAT diagnosis should be followed up by USG after the therapy and hypoechogenic regions greater than 1 cm should be assessed by biopsy.

## REFERENCES

- Zacharia TT, Perumpallichira JJ, Sindhwani V, Chavhan G. Gray-scale and color Doppler sonographic findings in a case of subacute granulomatous thyroiditis mimicking thyroid carcinoma. *J Clin Ultrasound*. 2002;30:442-4.
- Slatosky J, Shipton B, Wahba H. Thyroiditis: differential diagnosis and management. *Am Fam Physician*. 2000;61:1047-52.
- Benker G, Olbricht T, Windeck R, Wagner R, Albers H, Lederbogen S, et al. The sonographical and functional sequelae of de Quervain's subacute thyroiditis: long-term follow-up. *Acta Endocrinol*. 1988;117:435-41.
- Jhaveri K, Shroff MM, Fatterpekar GM, Som PM. CT and MR imaging findings associated with subacute thyroiditis. *Am J Neuroradiol*. 2003;24:143-6.
- Tokuda Y, Kasagi K, Iida Y, Yamamoto K, Hatabu H, Hidaka A, et al. Sonography of subacute thyroiditis: changes in the findings during the course of the disease. *J Clin Ultrasound*. 1990;18:21-6.
- Meachim G, Young MH. De Quervain's subacute granulomatous thyroiditis: histological identification and incidence. *J Clin Pathol*. 1963;16(3):189-99.
- Luotola K, Hyöty H, Salmi J, Miettinen A, Helin H, Pasternack A. Evaluation of infectious etiology in subacute thyroiditis lack of association with coxsackievirus infection. *APMIS*. 1998;106(4):500-4.
- Fatourehchi V, Aniszewski JP, Fatourehchi GZ, Atkinson EJ, Jacobsen SJ. Clinical features and outcome of subacute thyroiditis in an incidence cohort: Olmsted County, Minnesota, study. *J Clin Endocrinol Metab*. 2003;88(5):2100-5.
- Choia YS, Kima BK, Kwon HJ, Lee JS, Heo JJ, Jung SB, et al. Subacute thyroiditis with coexisting papillary carcinoma diagnosed by immediately repeat fine needle aspiration: a case report. *J Med Case Rep*. 2013;7(1):3.
- Lam KY, Lo CY. Papillary carcinoma with subacute thyroiditis. *Endocr Pathol*. 2002 Fall;13(3):263-5.
- Nishihara E, Hirokawa M, Ohye H, Ito M, Kubota S, Fukata S, et al. Papillary carcinoma obscured by complication with subacute thyroiditis: sequential ultrasonographic and histopathological findings in five cases. *Thyroid*. 2008;18(11):1221-5.
- Lu CP, Chang TC, Wang CY, Hsiao YL. Serial changes in ultrasound-guided fine needle aspiration cytology in subacute thyroiditis. *Acta Cytol*. 1997;41:238-43.
- Jeh SK, Jung SL, Kim BS, Lee YS. Evaluating the degree of conformity of papillary carcinoma and follicular carcinoma to the reported ultrasonographic findings of malignant thyroid tumor. *Korean J Radiol*. 2007;8:192-7.
- Xie P, Xiao Y, Liu F. Real-time ultrasound elastography in the diagnosis and differential diagnosis of subacute thyroiditis. *J Clin Ultrasound*. 2011;39(8):435-40.