

## Ultrasonic shears and bipolar vessel-sealing system for three-port laparoscopic ovariohysterectomy in dogs

[*Bisturi ultrassônico e sistema de selamento de vasos sanguíneos para ovário-histerectomia laparoscópica com três portais em cães*]

N. Guizzo-Júnior<sup>1</sup>, J.P.S. Feranti<sup>2</sup>, M.C. Bairros<sup>1</sup>, M. Bortoluzzi<sup>1</sup>, A.C. Motta<sup>3</sup>, L.W. Sartori<sup>1</sup>, F.R. Santos<sup>4</sup>, F.V. Tomazzoni<sup>1</sup>, G. Brambatti<sup>4</sup>, R.L. Guedes<sup>1</sup>, M.A.M. Silva<sup>3</sup>, M.V. Brun<sup>2\*</sup>

<sup>1</sup>Veterinários autônomos – Passo Fundo, RS

<sup>2</sup>Centro de Ciências Rurais – Universidade Federal de Santa Maria – CCR-UFSM – Santa Maria, RS

<sup>3</sup>Universidade de Passo Fundo – UPF – Passo Fundo, RS

<sup>4</sup>Universidade Federal do Rio Grande do Sul – UFRGS – Porto Alegre, RS

### ABSTRACT

In the current experimental study, two different instruments were compared for prophylactic hemostasis during a 3-port technique of laparoscopic ovariohysterectomy (OVH) in bitches. Moreover, the need for port enlargement for specimen retrieval using 5mm or 10mm trocartes, technical difficulties and complications were assessed. Ultrasonic energy and a vascular sealing system were tested. Duration of surgery, patient weight and diameter of the uterine arteries and veins were compared among the groups. Fifteen dogs randomly divided into three groups (GI, GII, GIII) were submitted to ovariohysterectomy with hemostasis from the use of ultrasonic scalpel or vascular sealing equipment. In GI and GII the LigaSure™ impedance-controlled bipolar vessel-sealing device was used, differing in the size of trocartes used between groups, and in GIII Autosonix™ was used. Patients' weight, duration of surgery, technical difficulties and complications were compared among the groups. Statistical analysis showed no difference between the data analyzed among the groups. In conclusion, both methods of hemostasis were effective for 3-port total laparoscopic ovariohysterectomy in bitches. However, 5mm trocartes were not adequate for retrieval of the uterus and ovaries without need for enlargement of the port incision.

Keywords: laparoscopy, canines, coagulation systems, spay, surgery

### RESUMO

No presente experimento, foram comparados dois diferentes equipamentos, um com emprego de energia ultrassônica, e outro utilizando sistema de selamento vascular, como única forma de hemostasia em ovário-histerectomias laparoscópicas com três portais em cadelas. Ademais, a necessidade de ampliação da incisão do portal de 5mm ou de 10mm para a remoção dos espécimes ressecados, dificuldades técnicas e complicações foram avaliadas. Quinze cadelas aleatoriamente distribuídas em três grupos (GI, GII, GIII) foram submetidas à ovário-histerectomia com hemostasia a partir da utilização de bisturi ultrassônico ou equipamento de selamento vascular. Nos GI e GII foi utilizado um sistema de selamento vascular eletrotérmico bipolar (LigaSure®), diferindo-se no tamanho dos portais utilizados; em GIII foi utilizado bisturi ultrassônico (Autosonix®). A análise estatística não demonstrou diferença significativa entre os dados analisados nos três grupos. Conclui-se que ambos os métodos de hemostasia utilizados mostraram-se adequados e viabilizaram a realização de ovário-histerectomia laparoscópica em cadelas. Todavia, o trocar de 5mm não foi adequado para remoção do útero e ovários sem necessidade de ampliação da incisão de acesso.

Palavras-chave: laparoscopia, caninos, sistemas de coagulação, castração, cirurgia

---

Recebido em 10 de março de 2014

Aceito em 21 de agosto de 2014

\*Autor para correspondência (*corresponding author*)

E-mail: silvamam@gmail.com

## INTRODUCTION

Minimally invasive laparoscopic surgery (MILS) has changed the traditional concept of surgery in Human Medicine, not as a substitute for conventional techniques, but as a modern surgical and diagnostic tool. MILS offers many advantages in terms of diagnostic and therapeutic approaches (Malm *et al.*, 2004; Howe, 2006). Currently, endoscopic techniques have been increasingly used in veterinary patients, especially for dog spay (Brun *et al.*, 2000; Austin *et al.*, 2003; Hancock *et al.*, 2005; Mayhew *et al.*, 2007).

Maneuvers such as traction, electrocoagulation of the ovarian pedicles and uterine ligaments/vessels and application of extra-corporal ligatures require adequate training and may affect surgical time (Malm *et al.*, 2004; Silva *et al.*, 2011). Mean surgical time may be similar (Devitt *et al.*, 2005) or longer (Malm *et al.*, 2004; Hancock *et al.*, 2005) using the laparoscopic approach, while intra-operative bleeding and post-operative pain is usually reduced in comparison to the conventional technique of ovariohysterectomy (OVH) (Hancock *et al.*, 2005; Devitt *et al.*, 2005).

The use of monopolar or bipolar diathermy for prophylactic hemostasis may damage the surrounding tissues and be less effective to seal the vessels in comparison to ultrasonic energy or vascular clips (Bubenik *et al.*, 2005; Mayhew and Brown, 2007).

Therefore, the aim of the current study was to compare the effectiveness, complications and technical difficulties of the use of the ultrasonic shears and the modulated bipolar vessel-sealing system on the prophylactic hemostasis of the vessels during a 3-port laparoscopic approach for OVH in bitches, and to assess the need for port enlargement for uterine and ovary retrieval using 5mm or 10mm trocar.

## MATERIALS AND METHODS

The current research was approved by the Committee of Ethics in Research of the University of Passo Fundo (CEP-UPF, protocol number 047/2008). Fifteen healthy mixed-breed bitches, body weight ranging from 6 to 18.9kg, were assessed. The dogs belonged to a private

shelter, and were adopted at the end of the study. The animals were examined clinically and blood analyses were carried out, which were exclusion criteria in order to join the study. The patients were placed in individual kennels and fed adequate commercial dog food and water *ad libitum* up to 12 hours prior to surgery.

The bitches were operated on by a single surgical team, which was at the beginning of the learning curve for laparoscopic spay techniques. The animals were randomly placed into three experimental groups, varying according to the method of prophylactic hemostasis and port size for specimen retrieval. Bitches from group I (GI) were operated on using a 5mm modular bipolar vessel-sealing device (LigaSure<sup>®</sup> - Convivial Surgical Inc., São Paulo, SP, Brazil) and two 5mm trocarts placed in each side, laterally to the midline, and a 10mm midline port, placed cranially to the umbilicus. Group II (GII) was submitted to the same approach, though using a 10mm trocar placed on the right side instead of a 5mm portal. Group III (GIII) was submitted to the same procedure and port placement employed on the GII; however, the ultrasonic shear (Autosonix<sup>®</sup> - Convivial Surgical Inc., São Paulo, SP, Brazil) was used for prophylactic hemostasis. The purpose of comparing 5mm to 10mm trocar was to determine if the shorter diameter trocar is large enough to retrieve the resected reproductive tract with no requirement for port incision enlargement.

A mixture of acepromazine (0.05mg/kg) and tramadol chloride (2mg/kg) was given intramuscularly. Anesthesia was induced 30 minutes following premedication, using intravenous bolus of sodium thiopental (12.5mg/kg). Anesthesia was maintained using halothane vaporized in 100% oxygen, in a semi-closed circuit. Additionally, all animals received epidural lidocaine chloride (6mg/kg) and ampicillin sodium (20mg/kg) intravenously in the early pre-operative period. The same dose of antibiotic solution was given 8 hours following surgery.

The first trocar was introduced into the pre-umbilical ventral midline using the open technique and a retractable trocar blade. The patient was kept in dorsal recumbency without head tilting for insufflation of the peritoneal cavity using carbon dioxide (1L min<sup>-1</sup> flow rate,

### Ultrasonic shears...

12mmHg intra-abdominal pressure). The peritoneal cavity was inspected using a 0° 10mm endoscope. The auxiliary trocarts were inserted under video-assisted guidance. In all groups the trocarts were placed according to the principles of port triangulation (Freeman, 1999). The auxiliary lateral ports were inserted caudally to the camera port, approximately at the level of the umbilicus.

The uterine body was manipulated using atraumatic forceps. A transparietal suspension suture was carried out in order to attach the uterine body to the ventral abdominal wall and expose the uterine vessels adequately (Fig 1A). A 3-0 polyglycolic acid thread with a 3.6 cm curved needle was employed to perform the suspension suture on the most caudal part of either right or left uterine horns. Afterwards, the

uterine body and vessels were sealed and transected immediately cranial to the cervix. LigaSure™ (Fig 1B) was used in GI and GII and Autosonix™ (Fig 1C) was employed in GIII.

The patient position was changed by tying the right thoracic limb along with the contralateral one, in order to promote a slight rotation of the thorax to the left side. Such maneuver aimed to improve the exposure of the right pedicle and move the viscera away from the coagulation site, as described in another study (Silva *et al.*, 2011). In all groups the ovarian suspensory ligament and pedicles were sealed and transected following proper exposure (Fig 1D). The same maneuver was performed for the hemostasis of the opposite pedicle. In GIII, the frequency of the ultrasonic surgical generator was set to 55.5 KHz previous to the procedure.

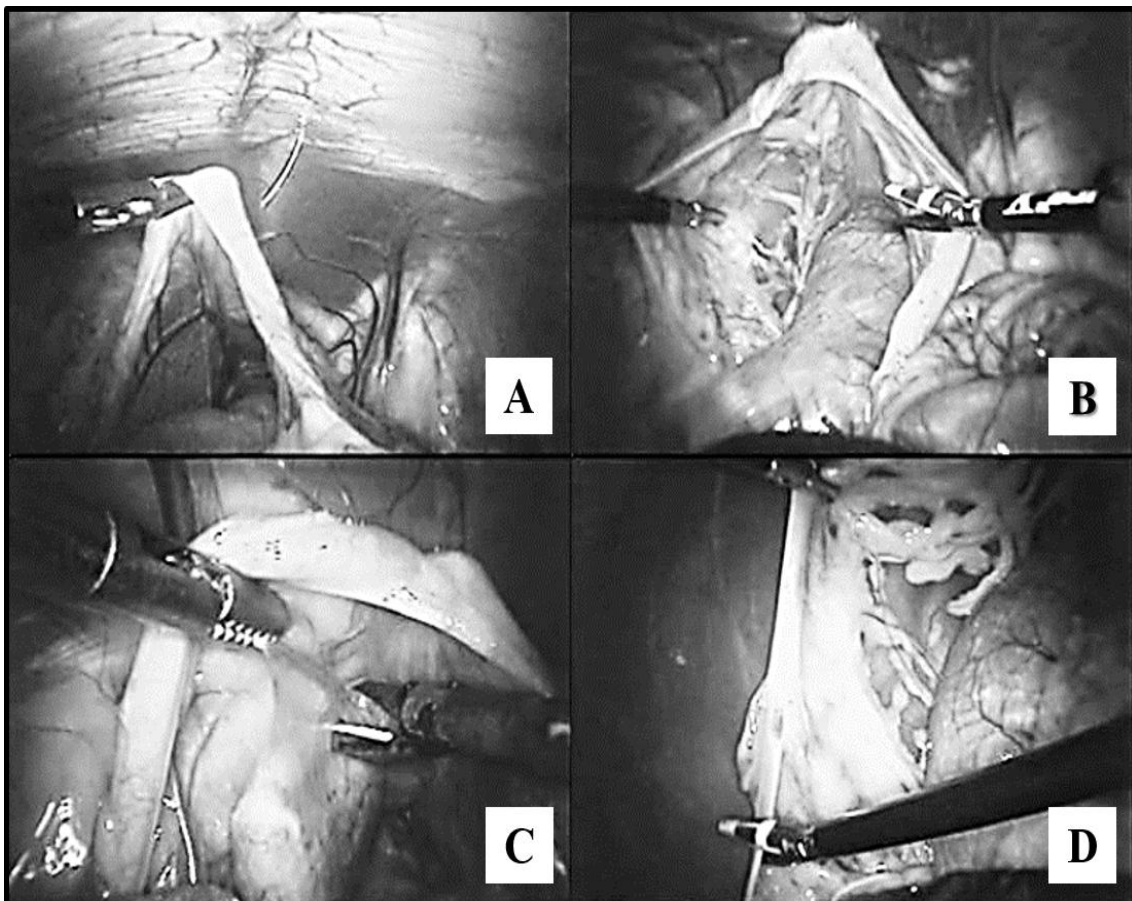


Figure 1. Diagram showing: transparietal suture on the right cranial to the uterine bifurcation, on the right uterine horn, for suspension of the uterus (A); localization of the uterine vessels for application of the LigaSure™ (B); use of the Autosonix™ for prophylactic hemostasis (C); coagulation of the left ovarian pedicle using LigaSure™ (D).

Blunt dissection of the mesometrium and uterine round ligament was performed after the transection of the ovarian pedicles on both sides. The frequency of bleeding during coagulation and transection of the uterine vessels and body, and ovarian pedicles, if present, would be recorded for further comparison among groups. Once the entire uterus was completely dissected, the surgical specimen was grasped and withdrawn from the abdominal cavity, following the retrieval of the right 5mm trocar in the animals in group GI. The incision would be enlarged if necessary in order to retrieve the surgical specimen adequately. In groups GII and GIII a 5-to-10 mm trocar reducer was inserted through the 10mm instrument trocar in order to use a 5mm grasping forceps for specimen retrieval, without leading to loss of pneumoperitoneum. The surgical specimen was then grasped and pulled into the 10mm trocar. Subsequently, the 10mm trocar was withdrawn from the abdomen along with the uterus and ovaries. Synthesis of the muscular layer was carried out using 2-0 nylon thread, in Sultan interrupted cross-pattern. The subcutaneous tissue was sutured using 3-0 nylon thread, in the same fashion employed for the muscular layer. The skin was sutured using 3-0 nylon thread, in simple interrupted pattern.

The animals were monitored for 12 hours following the surgical procedure. The patients were kept in individual cages, in a temperature-controlled environment. Tramadol chloride (2mg/kg, SC, TID, for 4 days) and ketoprofen (2mg/kg, SC, SID, for 3 days) were given. The wounds were cleansed using sterile normal saline three times a day, until suture removal, on the 10<sup>th</sup> day post-op.

The intra-operative complications were classified into minor, intermediate and major. Minor complications included those that require no intervention, such as subcutaneous emphysema and organ or tissue damage without tearing or bleeding; intermediate complications were those that required laparoscopic intervention, with no need to convert to the open procedure, such as mild bleeding from the uterus or pedicles or due to damage to other organs or tissues; and major complications were considered as the life-threatening conditions, which required interruption of the procedure and/or conversion for proper resolution, such as massive bleeding

uncontrollable by laparoscopic approach, severe damage or tear to surrounding organs or tissues and anesthetic complications related to CO<sub>2</sub> pneumoperitoneum.

The statistical analyses consisted of ANOVA and comparison of means using the Student's t-test for comparison of surgical time and patient weight among groups. The Chi-square test was used to assess the frequency of bleeding, complications and the need for port enlargement for specimen retrieval among groups. Technical difficulties encountered during surgery in all groups were assessed descriptively. A *p*-value below 0.05 was considered significant. The surgical complications were assessed descriptively.

## RESULTS

There was no difference among groups regarding body weight and surgical time ( $P>0.05$ ). Body weight ranged from 8.0 to 18.9kg ( $\pm 3.88$ kg) in GI, 6.1 and 16.0kg ( $\pm 3.96$ kg) in GII and 6.0 and 14.7kg ( $\pm 3.24$ kg) in GIII. The mean surgical time was 53.4 $\pm$ 6.02 minutes for GI, 64 $\pm$ 19.19 minutes for GII and 49.4 $\pm$ 11.24 minutes for GIII.

Laparoscopic ovariectomy in dogs using both devices for prophylactic hemostasis was perfectly feasible. There was no major complication in any of the groups. There were 18 intra-operative complications. Minor and intermediate complications occurred in 72.3% and 27.7% of all complications, respectively, regardless of the group (Table 1). Five out of all intra-operative complications (27.7%) occurred in GI, all of them classified as minor; six (33.3%) occurred in GII (three minor and three intermediate complications); and seven complications (39.0%) occurred in GIII (five minor and two intermediate complications) ( $p=0.7788$ ).

There were two cases of subcutaneous emphysema adjacent to the trocar sites, two lesions of the uterine horns with no bleeding during manipulation and one mechanical bladder serosa injury due to accidental clamping of the bladder wall with LigaSure<sup>TM</sup> during manipulation of the uterine vessels in GI. GII showed one case of portal site subcutaneous emphysema, two cases of trauma with no bleeding on the uterine horns during

manipulation, two minor bleeding episodes in the ovarian pedicles, which were classified as intermediate lesions. There was one case of mild splenic bleeding caused by accidental puncture

during laparoscopic-assisted insertion of an auxiliary trocar, which was controlled by simple compression using a gauze swab.

Table 1. Distribution of frequencies of complications during 3-port laparoscopic ovariohysterectomy in bitches using LigaSure™ and 5mm trocar, LigaSure™ and 10mm trocar and Autosonix™ and 10mm trocar for retrieval of resected reproductive tract

Severity	Complications	Frequency per group			Overall
		GI	GII	GIII	
Minor	Subcutaneous emphysema	2	1	4	7 (38.9%)
	Trauma to uterine horn	2	2	1	5 (27.8%)
	Trauma to the bladder	1	-	-	1 (5.6%)
Intermediate	Hemorrhage from the ovarian pedicle	-	2	-	2 (11.05%)
	Hemorrhage from spleen	-	1	1	2 (11.05%)
	Hemorrhage from uterine vessel	-	-	1	1 (5.6%)
Major	-	-	-	-	-
Overall	-	5(27.8%)	6(33.3%)	7(39%)	18(100%)

Minor complications in GIII included four cases of subcutaneous emphysemas and one case of trauma with no bleeding to the uterine horn during manipulation; intermediate complications were a case of puncture to the spleen with the Autosonix™ forceps during manipulation of the viscera, also treated with simple compression. There was a case of bleeding of the uterine vessels due to the application of ultrasonic energy on an incorrect site, thus producing inappropriate hemostasis of the uterine vessels. Such complication was managed by applying a new coagulation closely adjacent to the lesion site. Regarding technical difficulties, the bladder was filled in eight patients (53.3%), which hindered the approach to the round ligament of the uterus in seven cases (46.6%).

The major technical difficulty was the coagulation/resection of the uterine body, which required longer surgical time than the coagulation/resection of the pedicles. The 5mm trocar (GI) was not large enough to allow adequate retrieval of the uterus and ovaries. Port enlargement for retrieval of the uterus and ovaries was required in all patients in GI (100%), while none of the dogs required port enlargement in both GII and GIII ( $p=0.0006$ ).

### DISCUSSION

The approach to the uterus was initiated by the uterine vessels (Brun *et al.*, 2000) and not by the ovarian pedicles as described in other studies

involving laparoscopic (Davidson *et al.*, 2004; Malm *et al.*, 2004; Mayhew and Brown, 2007) and conventional approaches (Hedlund, 2007). The intra-operative modification of the positioning of the patient was another crucial maneuver. The attachment of both thoracic limbs together in a lateral position promoted mild rotation of the thorax as described in another trial (Silva *et al.*, 2011). Consequently, surgical exposure of the ovarian pedicles was improved, although trauma to the uterine horns and bleeding from the ovarian pedicles occurred in five and two cases. Moreover, no head-down tilt was required, as performed in other studies (Hancock *et al.*, 2005; Mayhew and Brown, 2007). The Trendelenburg positioning associated to the CO<sub>2</sub> pneumoperitoneum induces respiratory stress, especially due to the increase of pressure on the diaphragm (Normando *et al.*, 2004).

The two cases of bleeding from the ovarian pedicles were associated to the lack of experience of the surgeon with the sources of energy employed in the current study. Short exposure of the grasped tissue to the ultrasonic energy or exaggerate traction of the pedicle during coagulation could be the main reasons for that mild complication. Hemorrhage of the uterine vessels happened in one case due to incorrect application of the ultrasonic shears on the target tissue. Hemorrhage was also found in other studies and was also attributed to lack of experience of the surgeon (Malm *et al.*, 2004;

Hancock *et al.*, 2005; Silva *et al.*, 2011). Although laparoscopic spay may seem challenging for non-experienced surgeons, the learning curve can be reached with as little as 20 procedures, depending on the technique and instruments employed (Silva *et al.*, 2011).

Injuries inflicted by inaccurate use of laparoscopic surgical instruments were reported by several authors (Brun *et al.*, 2000; Hancock *et al.*, 2005; Mayhew and Brown, 2007). In our study, iatrogenic injury to the spleen occurred during the insertion of an auxiliary trocar in one patient (GII) and in another case, by the imprecise usage of the harmonic scalpel, which was previously reported in another trial (Mayhew and Brown, 2007). Regarding splenic injuries, several techniques can be used in order to manage bleeding, such as compression using gauze swab, argon plasma coagulation, suturing, and application of absorbable gelfoam hemostatic sponges or fibrin sealant (Canby-Hagino *et al.*, 2000).

In our study, bladder catheterization was not performed, which hindered the approach to the round ligament of the uterus. Therefore, we strongly recommend pre-operative bladder emptying. Regarding the transection of the round ligament, we suggest that scissors should be used instead of bipolar diathermy. The uterine round ligament is a thin and poorly vascularized tissue. Such tissue constitution provides low impedance for the application of bipolar energy. Thus, mechanical dissection of the round ligament is efficient and avoids the risk of energy-inflicted damage to the bladder and other surrounding tissues.

The mean overall surgical time obtained in our study differed from those reported by others (Davidson *et al.*, 2004; Malm *et al.*, 2004; Mayhew and Brown, 2007). The intra-corporal dissection of the broad ligament increased the surgical time in comparison to other studies in which such maneuver was not carried out (Mayhew and Brown, 2007; Silva *et al.*, 2011). The learning curve also influences the surgical time (Malm *et al.*, 2004; Silva *et al.*, 2011). The injuries reported in our study were also associated to the lack of experience of the surgical team, which was highlighted by others (Mayhew and Brown, 2007). Such complications

tend to become potentially rare as soon as the learning curve is reached.

The 5mm trocar was not adequate for retrieving the resected uterus and ovaries without need for enlargement of the port incision site. However, such technical difficulty did not affect surgical time in comparison to the use of 10mm trocar in groups GII and GIII. The need for port incision enlargement for specimen retrieval is expected in certain laparoscopic procedures such as nephrectomy (Brun *et al.*, 2002) and OVH for pyometra (Adamovich-Rippe *et al.*, 2013). However, regardless of the trocar diameter or the need for port incision enlargement, laparoscopic surgery may still be considered minimally invasive in comparison to the conventional celiotomy approach (Freeman, 1999).

In conclusion, the harmonic scalpel and the modulated bipolar vessel-sealing device are appropriate for use as a single method of prophylactic hemostasis during 3-port total laparoscopic approach for elective OVH. The equipment and techniques tested did not differ and showed efficiency for spaying healthy bitches and those owning reproductive disorder.

#### ACKNOWLEDGEMENTS

The authors would like to thank Astus Medical Technology and Jomhedica Norte Medical Supply for the technical support, and the University of Passo Fundo for providing the academic facilities.

#### REFERENCE

- ADAMOVIČH-RIPPE, K.N.; MAYHEW, P.D.; RUNGE, J.J. *et al.* Evaluation of laparoscopic-assisted ovariohysterectomy for treatment of canine pyometra. *Vet. Surg.*, v.42, p.572-578, 2013.
- AUSTIN, B.; LANZ, O.I.; HAMILTON, S.M. *et al.* Laparoscopic ovariohysterectomy in nine dogs. *J. Am. Anim. Hosp. Assoc.*, v.39, p.391-396, 2003.
- BRUN, M.V.; BECK, C.A.C.; MARIANO, M.B. *et al.* Nefrectomia laparoscópica em cão parasitado por *Diocotophyoma renale* – relato de caso. *Arq. Cienc. Vet. Zool. Unipar*, v.5, p.145-152, 2002.
- BRUN, M.V.; SILVA FILHO, A.P.; BECK, C.A.C. *et al.* Laparoscopic ovariohysterectomy in canines. *Braz. J. Vet. Res. Anim. Sci.*, v.37, p.480-485, 2000.

*Ultrasonic shears...*

- BUBENIK, L.J.; HOSGOOD, G.; VASANJEE, S.C. *et al.* Bursting tension of medium and large canine arteries sealed with ultrasonic energy or suture ligation. *Vet. Surg.*, v.34, p.289-293, 2005.
- CANBY-HAGINO, E.D.; MOREY, A.F.; JATOI, I. *et al.* Fibrin sealant treatment of splenic injury during open and laparoscopic left radical nephrectomy. *J. Urol.*, v.164, p.2004-2005, 2000.
- DAVIDSON, E.B.; MOLL, H.D.; PAYTON, M.E. *et al.* Comparison of laparoscopic ovariohysterectomy and ovariohysterectomy in dogs. *Vet. Surg.*, v.33, p.62-69, 2004.
- DEVITT, C.M.; COX, R.E.; HAILEY, J.J. *et al.* Duration, complications, stress, and pain of open ovariohysterectomy versus a simple method of laparoscopic-assisted ovariohysterectomy in dogs. *J.A.V.M.A.*, v.227, p.921-927, 2005.
- FREEMAN, L.J. Minimally invasive surgery of the reproductive system. In: FREEMAN, L.J. (ed.). *Veterinary Endosurgery*. St. Louis: Mosby, 1999. pp. 105-117.
- HANCOCK, R.B.; LANZ, O.I.; WALDRON, D.R. *et al.* Comparison of postoperative pain after ovariohysterectomy by harmonic scalpel-assisted laparoscopy compared with median celiotomy and ligation in dogs. *Vet. Surg.*, v.34, p.273-282, 2005.
- HEDLUND, C.S. Surgery of the reproductive and genital systems. In: FOSSUM, T.W.; HEDLUND, C.S.; JOHNSON, A.L. *et al.* (Eds.). *Small animal surgery*, 3.ed., Saint Louis: Mosby Elsevier. 2007. pp.702-774.
- HOWE, L.M. Surgical methods of contraception and sterilization. *Theriogenol.*, v.66, p.500-509, 2006.
- MALM, C.; SAVASSI-ROCHA, P.R.; GHELLEN, V.A. *et al.* Ovariohysterectomy: experimental and comparative study between laparoscopic and conventional approaches. Intra-operative phase. *Arq. Bras. Med. Vet. Zootec.*, v.56, p.457-466, 2004.
- MAYHEW, P.D.; BROWN, D.C. Comparison of three techniques for ovarian pedicle hemostasis during laparoscopic-assisted ovariohysterectomy. *Vet. Surg.*, v.36, p.541-547, 2007.
- NORMANDO, V.M.F.; BRITO, M.V.H.; ARAÚJO JÚNIOR, F.A. *et al.* Respiratory repercussion of pneumoperitoneum induced in pigs. *Acta Cir. Bras.*, v.19, p.664-669, 2004.
- SILVA, M.A.M.; SANTOS-BATISTA, P.A.C.; POGIANNI, F.M. *et al.* Single-port video-assisted ovariohysterectomy in bitches: retrospective study of 20 cases. *Cienc. Rural*, v.41, p.294-300, 2011.