

Mammary botryomycosis: two concomitant cases in mares: case report

[*Botriomicose mamária: dois casos concomitantes em éguas: relato de caso*]

C.B. Belli, J.S. Fonte, L.N. Torres, M.R. Gondin, P.C. Maiorka, C.B. Fernandes

Universidade de São Paulo – USP – São Paulo, SP

ABSTRACT

Mammary disorders in mares are rare and usually only one animal per paddock is affected. In this report, two mares with 7 and 9 years old, were concomitantly diagnosis of chronic pyogranulomatous mastitis, associated with the Splendore-Hoeppli reaction, indicative of botryomycosis a rare, chronic suppurative disease with microabscess formation, characterized by *in vivo* formation of eosinophilic materials around microorganisms or biologically inert material. Various bacteria can cause botryomycosis in horses, and the most frequently isolated one is *Staphylococcus* sp., particularly *S. aureus*. This report confirms the role of *Staphylococcus* sp.; however, specifically *S. hyicus* and *S. cohnii* that prior to the current report, had not been associated with cases of botryomycosis.

Keywords: equine, mastitis, mammary gland, botryomycosis

RESUMO

Enfermidades mamárias em éguas são raras e, normalmente, apenas um animal é afetado. Neste relato, duas éguas, de sete e nove anos, foram diagnosticadas concomitantemente com mastite crônica piogranulomatosa, associada com reação de Splendore – Hoeppli, indicativa de botriomicose, uma doença crônica supurativa rara, com formação de microabscessos caracterizados pela presença de material eosinofílico em torno dos microrganismos ou de material biologicamente inerte. Várias bactérias podem causar botriomicose em cavalos, sendo Staphylococcus sp., particularmente S. aureus, as mais frequentemente isoladas. Este relato confirma o papel do Staphylococcus sp, no entanto este é o primeiro relato em que S. hyicus e S. cohnii foram identificados em lesões relacionadas à botriomicose.

Palavras-chave: equino, mastite, glândula mamária, botriomicose

INTRODUCTION

A number of rare disorders may affect the mammary glands of mares, such as mastitis, agalactia, enlargement due to several causes, premature/inappropriate lactation, abscesses and neoplasms. Whatever the cause, usually only one animal per paddock is affected. Even in bacterial mastitis, rarely are several mares affected at the same time, unlike what occurs in cattle. When examining a mare with an enlarged mammary gland (MG), it is important to conduct a differential diagnosis among the various possible conditions while considering the animal's

clinical and reproductive history (Brendemuehl, 2008).

Botriomycosis is a poorly reported condition in horses, being more common in the skin or related to orchiectomy's surgical wounds (Scott, 1988; Knottenbelt, 2009; Scott and Miller 2011). The occurrence in the mare's mammary gland has very few reports in the literature (Smiet *et al.*, 2012) and none in Brazil, making important the disclosure of the following case.

CASUISTRY

Two Brazilian mares of the Brasileiro de Hipismo breed, that were 7 and 9 years old and belonged to the Military Police of the state of São Paulo – Brazil, were treated at the Veterinary Hospital of the University of São Paulo, School of Veterinary Medicine and Animal Science. They had both been suffering from unilateral firm MG enlargement for 90 days. Both mares were nulliparous with no history of lactation, pregnancy, MG trauma, hormonal treatment, contact with foals or history of previous gynecological examinations.

On clinical examination, there were no changes in vital parameters, haematological evaluation or total thyroxine (T4), although the total T4 dosage does not adequately reflect the thyroid hormone profile in the animal. The right MG of Mare 1 (M1) had a firm mass of approximately 20cm, with areas of fluctuation (Figure 1). Mare 2 (M2) had a firm homogeneous enlargement of the left MG without nodules, accompanied by cranial edema, increased temperature and mild sensitivity.

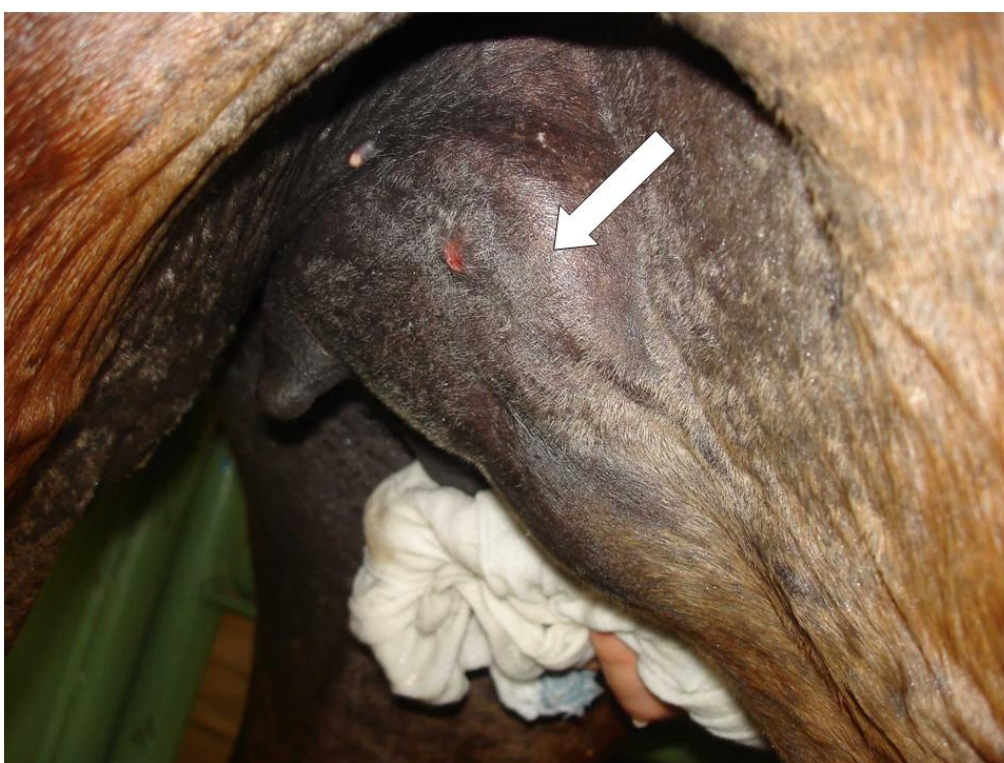

Figure 1. Mammary gland of the mare 1. Note the irregular area present in the inspection of right MG (arrow), corresponding to firm mass with floating areas identified on palpation.

In M1, the ultrasound revealed a dense and altered glandular tissue, that was considerably irrigated with vascular congestion and a delimited rounded structure indicative of abscess. M2 had caudally well-defined glandular tissue that was heterogeneous, swollen, with a lobular-shaped mass 3cm in diameter. The transrectal reproductive tract examination did not reveal any alterations.

In M1, cytology and culture of the aspirated material revealed a chronic inflammatory process containing high cellularity and bloody material associated with epithelial desquamation reaction with lymphocytic infiltration and presence of *Staphylococcus hyicus*. In M2, we observed material suggestive of lymphocytic liquid and the presence of *Staphylococcus cohnii*. In both mares, histopathology findings revealed fibrofatty connective tissue with diffuse and moderate perivascular infiltrate predominantly

consisting of mononuclear cells. M2 also had mild fibrosis involving the slightly dilated apocrine glands. A chronic bacterial infection was suspected.

Treatment consisted of systemic antibiotics, local compresses, cold hosing hydrotherapy and hand-walking. During treatment, M1 presented two fistulas in the right MG with purulent discharge. Most of the treatment was carried out on the property with improvement reported for both animals. Although neither experienced a complete recovery, there were no reported losses in work-related productivity.

Three months following cessation of treatment, M1 was euthanized due to a fractured limb. A

larger and more representative MG tissue sample was collected for a new histopathological examination which revealed a striking multifocal, coalescing inflammatory pyogranulomatous infiltrate associated with MG lobules. The infiltrate (composed mainly of intact and degenerated neutrophils), contained deposits of spiculated eosinophilic material intermingled with cellular debris and was suggestive of a Splendore-Hoeppli reaction (Figure 2). We also found lymphocytes, plasma cells, epithelioid macrophages and Langhans type giant cells associated with the neutrophils. Furthermore, we observed moderate fibrosis with sporadic localized necrosis on the periphery of the lesion and hemorrhage.

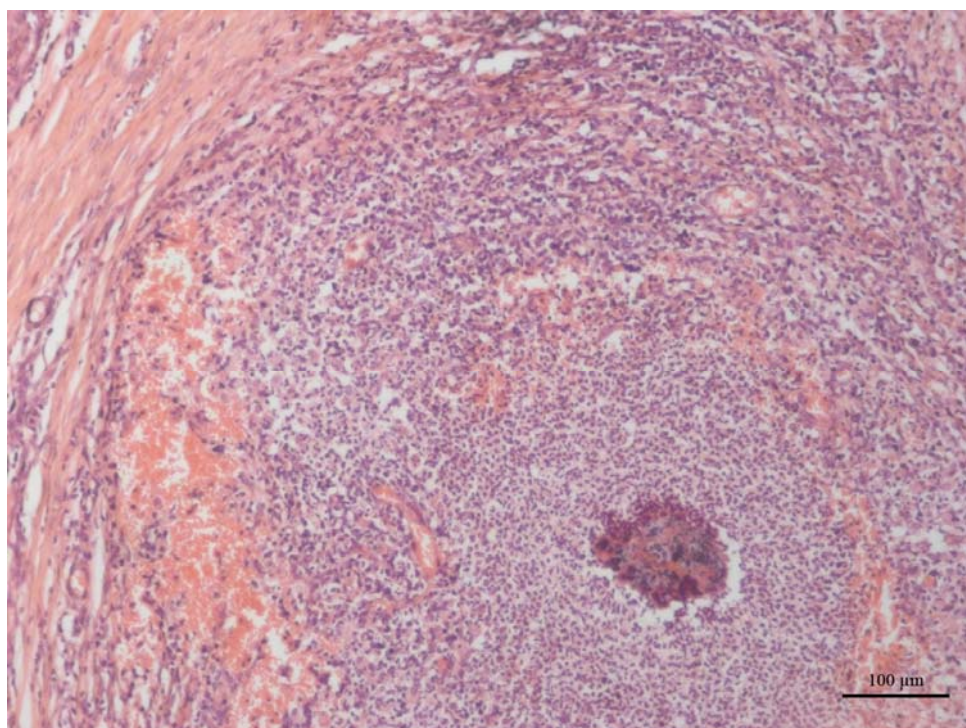


Figure 2. Mammary gland tissue. A pyogranulomatous inflammatory process associated with eosinophilic spiculate material around bacterial colonies (Splendore-Hoeppli reaction). H&E stain; magnification = 10x.

Thus, the diagnosis of chronic pyogranulomatous mastitis associated with the Splendore-Hoeppli reaction was indicative of botryomycosis, a rare, chronic suppurative disease with microabscess formation, characterized by the in vivo formation of eosinophilic materials around microorganisms or biologically inert material (Scott and Miller 2011; Smiet *et al.*, 2012).

DISCUSSION

Botryomycosis (or pseudomycetoma) is an aberrant host response to an infectious agent, in which the agent is isolated but not eliminated (Scott and Miller 2011). It is not a common differential diagnosis considered in cases of alteration of the mammary gland, since there is

no breed, age, or sexual predisposition to this disease (Scott 1988) and the cutaneous (not the visceral) form is most common in horses (Scott, 1988; Scott and Miller 2011; Smiet *et al.*, 2012).

Botryomycosis was first reported in horses in 1870 as a granulomatous lesion in the lung (Smiet *et al.*, 2012), but is more commonly found in the limbs or head after skin lacerations, or in the scrotum following castration (Knottenbelt, 2009). Botryomycosis lesions may be solitary or multiple, and often involve ulceration and fistulas (Scott, 1988; Cudmore *et al.*, 2012). Reports of botryomycosis in horses have included cases involving skin, spinal canal, and mammary gland (Scott, 1988; Ellenberger *et al.*, 2006; Cudmore *et al.*, 2012; Smiet *et al.*, 2012). Smiet *et al.* (2012) reported two cases in mammary gland tissue, both with a history of left MG abscess for over 3 months and the presence of *S. aureus* in the aspirated fluid, with a very similar clinical profile to the mares studied in the current report. These authors recommend surgical removal and returning to regular activities.

Histopathological findings confirm the diagnosis, as observed in M1. Histopathologically, in botryomycosis, the etiologic agent is encapsulated in granules, which likely impedes its elimination by inhibiting its response to antibiotics and leading to chronic infection. The main histopathological finding is Pyogranulomatous dermatitis and panniculitis with presence of granules in the tissue (Scott, 1988). The morphological phenomenon known as Splendore-Hoeppli may also be present, characterized by a pyogranulomatous reaction with eosinophilic granules around a necrotic area containing microorganisms or inert materials (Scott and Miller 2011; Smiet *et al.*, 2012).

The main differential diagnoses of these cases reported here would be simple abscesses or by *S. equi*, mastitis and neoplasia, which were not confirmed in any examination (evaluation of mammary secretion, culture, ultrasonography and cytology). The diagnosis for M1 was only completed after gathering additional material for histopathological examination. We believe the botryomycosis was not diagnosed earlier due to an insufficient quantity of collected material, a limitation that should be considered in future cases. Surgical excision of the affected tissue

combined with prolonged antibiotic therapy is the treatment of choice in botryomycosis (Scott and Miller, 2011), as recurrence is rarely observed when an aggressive and prolonged pretreatment is used (Knottenbelt, 2009).

After the definitive diagnosis of M1, a total mastectomy was recommended for M2. However, as animal's duties were not being affected, the individuals responsible for M2 opted not to perform surgery until there was an imminent need.

Even without definitive (histopathological) diagnosis of botryomycosis in M2, its other characteristics similar to those of M1 and the exclusion of the main differential diagnoses (mastitis, neoplasia, simple abscesses etc.) allow the placement of the two cases in a single report.

Little is known about what causes a predisposition to botryomycosis, and some suspect that small wounds or trauma may be the gateway for bacteria (Smiet *et al.*, 2012). In this report, the mares resided in neighboring stalls and were affected by the disease concomitantly and unilaterally, but the cause for this association is unknown. Botryomycosis has been shown to be more severe in horses with an impaired immune system (Knottenbelt, 2009). However, neither mare in this report showed evidence of immunosuppression or trauma, although the latter cannot be completely ruled out.

Various bacteria can cause botryomycosis in horses. The causative agent is most frequently *Staphylococcus* sp., particularly *S. aureus* (Knottenbelt, 2009; Cudmore *et al.*, 2012; Smiet *et al.*, 2012), although *Actinobacillus equi* has been implicated as well (Scott, 1988).

The bacteria isolated in the present report, *Staphylococcus hyicus* and *S. cohnii*, to the best of our knowledge, have not previously been associated with botryomycosis, but have been implicated in other disorders. *Staphylococcus hyicus* can be isolated from the skin of healthy horses but is more common in cases of infectious dermatoses such as pastern and coronary band dermatitis (Devriese *et al.*, 1985; Shimozawa *et al.*, 1997; Knottenbelt, 2009) and in subcutaneous abscesses, including those on the withers (Devriese *et al.*, 1985). It is considered the fourth most important bacteria in equine skin

lesions (Devriese *et al.*, 1985). *Staphylococcus cohnii* has been isolated from the skin and nostrils of healthy horses (Matsuo *et al.*, 2001) with few reports of skin lesions (Devriese *et al.*, 1985). Both strains have been isolated from cases of bovine mastitis in Brazil (Guimarães *et al.*, 2013) and *S. hyicus* has been reported to cause mastitis in a dog (Araújo *et al.*, 2011). Although, previously these bacteria were identified in horse's skin alterations and mammary glands of other species, in this case report the two situations were associated, leading to the mammary lesion in the mares.

The MG changes reported here are different from findings in the literature for several reasons: in our study, they occurred concomitantly in two mares (while single cases are more common), they showed MG inflammation without any secretions (different from other cases of classic mastitis, even when outside the lactation period), they developed abscesses (which, besides being rare in isolation, were not associated with specific agents such as *S. equi*) and histologically, they showed the formation of the Splendore-Hoeppli phenomenon characteristic of botryomycosis.

We therefore conclude that *Staphylococcus hyicus* and *Staphylococcus cohnii* can cause botryomycosis in horses. Furthermore, this is an uncommon disease, botryomycosis should be considered in cases where mares have enlarged mammary glands, especially when it is associated with abscessation. It may even occur concomitantly in several animals, but the reason for this association is still unknown.

Acknowledgements: São Paulo Research Foundation (FAPESP 2017/05425-0).

REFERENCES

- ARAÚJO, M.R.; PREIS, I.S.; FRANÇA, S.A., *et al.* Mastitis accompanied by lymphadenitis in a dog caused by *Staphylococcus hyicus*. *Braz. J. Vet. Pathol.*, v.4, p.52-57, 2001/2011.
- BRENDEMUEHL, J.P. Mammary gland enlargement in the mare. *Equine Vet. Educ.*, v.20, p.8-9. 2008.
- CUDMORE, L.A.; GROENENDYK, J.C.; HODGE, P. *et al.* Pyogranulomatous lesion causing neurological signs localized to the sacral region in a horse. *Aust. Vet. J.*, v.90, p.392-394, 2012.
- DEVRIESE, L.A.; NZUAMBE, D.; GODARD, C. Identification and characteristics of *Staphylococci* isolated from lesions and normal skin of horses. *Vet. Microbiol.*, v.10, p.269-277, 1985.
- ELLENBERGER, C.; SCHOON, D.; SCHOON, H.A. Exceptional diagnostic findings in uterine biopsies of the mare. *Pferdeheilkunde*, v.22, p.171-176, 2006.
- GUIMARÃES, F.F.; NÓBREGA, D.B.; RICHINI-PEREIRA, V.B. Enterotoxin genes in coagulase-negative and coagulase-positive staphylococci isolated from bovine milk. *J. Dairy Sci.*, v.96, p.2866-2872, 2013.
- KNOTTENBELT, D.C. Bacterial diseases. In: KNOTTENBELT, D.C. (Ed.). *Pascoe's principles & practice of equine dermatology*. 2.ed. [New York]: Saunders Elsevier, 2009. p.141-166.
- MATSUO, E.; KAWANO, J.; YASUDA, R. *et al.* Species distribution of *Staphylococci* in the nares and skin of horses. *J. Equine Sci.*, v.12, p.127-134, 2001.
- SCOTT, D. W. Bacterial pseudomycosis (botryomycosis) in the horse. *Equine Pract.*, v.10, p.15-19, 1988.
- SCOTT, D.W.; MILLER, W.H. Bacterial skin diseases. In: SCOTT, D.W., ; MILLER, W.H. (Eds.). *Equine Dermatology*. 2.ed. [New York]: . Saunders Elsevier, 2011. p.130-170.
- SHIMOZAWA, K.; ANZAI, T.; KAMADA, M. *et al.* Fungal and bacterial isolation from racehorses with infectious dermatosis. *J. Equine Sci.*, v.8, p.89-93, 1997
- SMIET, E.; GRINWIS, G.C.M.; VAN DEN TOP, J.G.B. *et al.* Equine mammary gland disease with a focus on botryomycosis: a review and case study. *Equine Vet. Educ.*, v.24, p.357-366, 2012.