

**Tracking viral particles in the intestinal contents of the American bullfrog,
Lithobates catesbeianus, by Transmission Electron Microscopy**

[Pesquisa de partículas virais em conteúdo intestinal de rãs-touro americanas, *Lithobates catesbeianus*, por meio da microscopia eletrônica de transmissão]

A.M. Antonucci¹, M.H. Catroxo², M. Hipolito², R.M. Takemoto¹, N.A. Melo², F.M. França³,
P.C. Teixeira³, C.M. Ferreira³

¹Universidade Estadual de Maringá – Maringá, PR

²Instituto Biológico do Estado de São Paulo – São Paulo, SP

³Instituto de Pesca, APTA, SAA. – São Paulo, SP

ABSTRACT

Feces are an important viral agent elimination route for infected carrier animals and in aquatic organisms these pathogenic agents can very rapidly propagate due to the habitation environment. The objective of this work is to track viral particles in the intestinal contents of bullfrogs (*Lithobates catesbeianus*) from five commercial frog farms in the region of Vale do Paraíba, in the State of São Paulo, Brazil, using negative contrast transmission electron microscopy (TEM). The *Coronaviridae*, *Paramyxoviridae*, *Parvoviridae* and *Herpesviridae* families were observed and photographed in specimens. This work emphasizes the importance of adopting sanitary measures in commercial farms and confirms that observing feces by TEM is an efficient and rapid diagnostic tool for detecting viral agents.

Keywords: amphibians, herpesvirus, coronavirus, paramixovirus, parvovirus

RESUMO

Sabendo-se que as fezes são uma importante via de eliminação de agentes virais pelos animais portadores e que, por estarem na água, os agentes patogênicos podem se propagar mais rapidamente, objetivou-se a pesquisa de vírus em conteúdo intestinal de rãs-touro (*Lithobates catesbeianus*) de cinco ranários comerciais na região do Vale do Paraíba, no estado de São Paulo, pela técnica de microscopia eletrônica de transmissão. As famílias *Coronaviridae*, *Paramixoviridae*, *Parvoviridae* e *Herpesviridae* foram observadas e fotografadas. Este trabalho ressalta a importância da adoção de medidas sanitárias nas criações, além da confirmação de que a observação de fezes pela microscopia eletrônica de transmissão é uma eficiente ferramenta de diagnóstico rápido para agentes virais.

Palavras-chave: anfíbios, herpesvírus, coronavírus, paramixovírus, parvovírus

INTRODUCTION

Viruses that infect amphibians have been described previously mainly in reports concerning zoo or wild animals (Hipolito *et al.*, 2003). The renal adenocarcinoma known as Lucke tumor, a neoplasia associated with infection by the *Herpesviridae* family and low temperatures, was initially described in *Rana pipiens* in North America (Williams *et al.*, 1996). In anurans, such as *Xenopus laevis* and *R.*

pipiens, the occurrence of lymphosarcoma associated with infection by the Iridovirus group has been described. Associations have already been established between wild amphibians, which may act as viral reservoirs, and the viruses that cause western equine and Japanese B encephalitis (Hipolito *et al.*, 2003).

In Brazil, frog raising is a very popular activity and this type of culture has occurred since the 1970s, with Brazilian production at 639 tons in

2006 (Dias *et al.*, 2009). The American bullfrog, recently reclassified as *Lithobates catesbeianus* (Frost *et al.*, 2006), is the main species used in frog farms and has an excellent capacity to adapt to different climates, as well as the distinct physical and feeding management used in the intensive culture systems (Ferreira *et al.*, 2002).

In Brazilian frog farms, there is a high incidence of animal mortality cases without a complete clarification of the cause. In some Brazilian farms, viral particles similar to the Iridovirus group have been detected in the liver of bullfrogs. The swelling of the tadpoles of this species has been associated with a group of polyhedral cytoplasmic deoxyribo viruses: the tadpole edema virus (TEV) and frog virus 3 (FV3) (Mazzoni *et al.*, 2009).

Viruses from the Togavirus group were observed in liquid from *L. catesbeianus* with asciti, and infection by viruses from the *Paramyxoviridae* family were described in the liver of tadpoles that had died from an unknown cause (Hipolito *et al.*, 2003). This same author described the presence of particles similar to the *Herpesviridae* family in hepatic injuries of frogs that had died from intoxication problems and in skeletal muscular nodules (Hipolito and Bach, 2002). The Ranavirus belongs to the Iridovirus group and is a viral agent that is primarily reported in amphibians. Currently the illness caused by this virus is of interest to the World Organization for Animal Health (OIE) due to its rapid propagation and high lethality. The diagnosis of these viral agents is determined by PCR and electron microscopic techniques, and by antibodies using the ELISA method and immuno-electron microscopy (Zupanovic *et al.*, 1998).

It is known that feces are an important route for viral agent transmission, along with contaminated food and water. However, to be a viable biological tool, the laboratory diagnosis must allow the identification of these agents in the applicable fecal material (Gregori *et al.*, 2004). The objective of this work was to identify, through transmission electron microscopy, the possible viral groups isolated in the intestinal contents of *Lithobates catesbeianus* following intensive cultivation.

MATERIALS AND METHODS

The present study was completed in five frog farms in different municipalities in the Vale do Paraíba region (an altitude of 500 to 670m), São Paulo, Brazil. These frog farms were denominated A, B, C, D and E and this region was chosen due to the presence of a large number of active frog farms.

Nine post-metamorphosis and asymptomatic bullfrogs were selected from each of the properties, a total of 45 individuals, between March and June (autumn in the Southern hemisphere).

The frogs were taken to the Aquatic Organisms Pathology Laboratory from the Fish Institute in São Paulo, where they were conditioned in vivarium boxes adapted for amphibians (Bueno-Guimarães, 1999) and remained in the same location for a maximum of four days. Water exchange and forced feeding of the animals with extruded ration I containing 40% crude protein was completed daily.

Due to the difficulty of collecting feces from living animals due to possible leaching of the feces by the water, tissue contamination and other substances from the animal itself, it was decided that the direct dissection of the large intestine would be performed (Mouriño and Stéfani, 2006).

Before euthanizing the animals, they were anesthetized by hypothermia, inspected to detect any injury and subsequently desensitized and sacrificed through medullary sectioning and bleeding at the height of the atlas bone in the cervical region. The necropsy was carried out under stereoscopic microscopy through an incision made with scissors at the cloaca, completely exposing the coelomic cavity and its viscera. The intestines were separated and dissected with scissors. The contents of the large intestine were removed with a spatula, placed in a polypropylene microtube, and duly identified. For each necropsied frog, the bench and the material used were sanitized with isopropyl alcohol (70%) to minimize the contamination risk.

Tracking viral particles...

After collection the fecal samples were immediately cooled to 5°C for a maximum of 24 hours until being taken to the Electron Microscopy Laboratory of the Biological Institute of São Paulo for processing and analysis. Intestine fragments which presented lesions macroscopically similar to enteritis were collected with the use of scissors to observe the viral particles associated with these organs.

The samples were processed for observation of the viral particles using negative contrast transmission electron microscopy. In this procedure, the samples are suspended in a 0.1 M phosphate buffer (pH 7.0), placed on metal grates covered with collodion and carbon film, drained with a paper filter, negatively contrasted with 2% ammonium molybdate (pH 5.0) and subsequently observed in a Philips EM 208 transmission electron microscope.

In order to extend the viral particle investigation in the intestinal contents of bullfrogs, two wild frogs were collected and analyzed in the same way. These two animals were bullfrogs that had fled from the frog farm and were living free in nature without any type of zootechnical, sanitary or food management. The American bullfrog (*L. catesbeianus*) is an alien species, introduced in Brazil in 1935 for zootechnical purposes. Nowadays it is the only species used in Brazilian commercial rearing. This husbandry is regulated and the release of these species is prohibited by the Agricultural and Environmental Department (IBAMA). We deduce that the species captured in lagoons resulted from accidental escapes, probably from this farm or another one in the same region.

RESULTS

In this study we identified that 42 out of 45 samples were positive for virus (91.3%), where two of the virus-negative frogs were from farm A and one was from farm B. The viral groups that were found in the intestinal content samples were *Paramyxoviridae* in 40 of the animals, *Coronaviridae* in 11, *Herpesviridae* in 7 and *Parvoviridae* in 1. (Table 1) indicates the prevalence of the encountered viral groups.

Table 1. Number of animals (*Lithobates catesbeianus*) and prevalence of each identified viral group

Viral Family	Number of animals	Prevalence (%)
<i>Paramyxoviridae</i>	40	87
<i>Coronaviridae</i>	11	24
<i>Herpesviridae</i>	7	15
<i>Parvoviridae</i>	1	2

Three animals that presented *Paramyxoviridae* infection (Fig. 1) in the intestinal contents also presented intestinal lesion injuries similar to enteritis. The presence of viral particles similar to the *Paramyxoviridae* and the *Herpesviridae* families were observed in the analysis of these fragments. Frog farm E presented five animals with intestinal injuries, whereas the presence of Herpesvirus infection was observed in only one animal (Fig. 2) and the presence of Coronavirus in another (Fig. 3) was associated with the presence of Paramyxovirus.

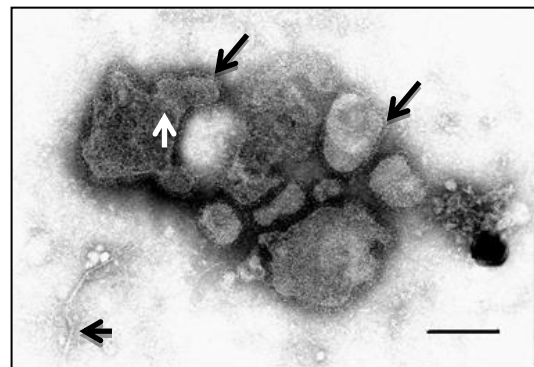


Fig 1. Electron photomicrograph of Paramyxovirus particles in intestinal contents of the bullfrog (*L. catesbeianus*), pleomorphic or roughly spherical, measuring 100 to 500nm in diameter containing an envelope covered by spikes (big arrow) measuring 8 nm long and internal "herring-bone" nucleocapsid, measuring 10nm in diameter (minor arrow). The bar represents 180nm.

One of the wild animals presented only Paramyxovirus infection in its intestinal contents and infection with the *Paramyxoviridae* and *Herpesviridae* families in the intestinal injury fragment. The second animal presented infection with the *Paramyxoviridae* and *Herpesviridae* families in its intestinal contents and the collected injury (Table 2).

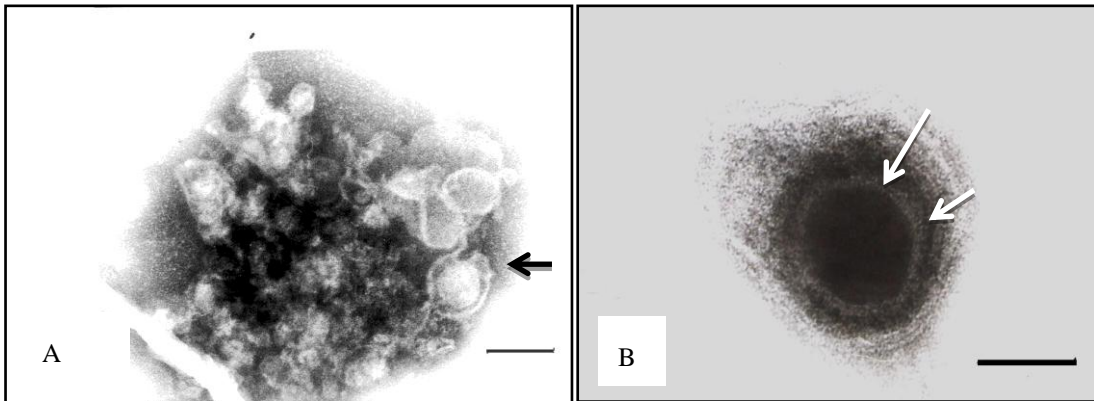


Fig. 2. A - Electron photomicrograph of Herpesvirus particles in intestinal contents of the bullfrog (*L. catesbeianus*), the bar represents 150nm. B - Herpesvirus particle measuring 190nm in diameter, showing icosahedral nucleocapsid structure, measuring 100nm in diameter (long arrow), containing individualized capsomers (short arrow) and a bi-layered outer envelope with fine surface projections 10nm long. The bar represents 35nm.

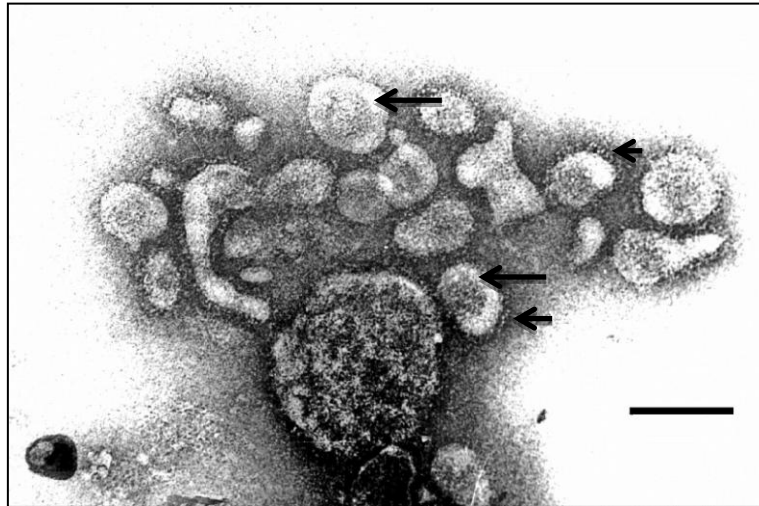


Fig 3. Electron photomicrograph of Coronavirus particles in intestinal contents of the bullfrog (*L. catesbeianus*) showing marked, rounded or elongated shaped pleomorphism, with characteristic radial projections forming a corona and mostly presenting a central electron dense corion (large arrow) and measuring 80-140nm in diameter. The club-shaped surface projections measure approximately 20 nm long (short arrow). The bar represents 130 nm.

Table 2. Viral groups present in intestinal lesion fragments macroscopically similar to enteritis in each analyzed animal containing these injuries

Animal Group	Number of Animals	Viral Family
Frog Fram B	1	<i>Paramixoviridae</i> and <i>Herpesviridae</i>
Frog Fram B	5	<i>Paramixoviridae</i> and <i>Herpesviridae</i>
Frog Fram B	6	<i>Paramixoviridae</i> and <i>Herpesviridae</i>
Frog Fram E	2	<i>Paramixoviridae</i> and <i>Coronaviridae</i>
Frog Fram E	3	<i>Paramixoviridae</i>
Frog Fram E	4	<i>Paramixoviridae</i> and <i>Herpesviridae</i>
Frog Fram E	5	<i>Paramixoviridae</i>
Frog Fram E	8	<i>Paramixoviridae</i>
Wild Animal	1	<i>Paramixoviridae</i> and <i>Herpesviridae</i>
Wild Animal	2	<i>Paramixoviridae</i> and <i>Herpesviridae</i>

DISCUSSION

Johnson and Wellehan (2005) reported that amphibians are a diverse group of species; much work remains to be done to elucidate the amphibians' viruses. Viral diseases may play an important role in wild and captive amphibian populations. The survival of a virus depends on its infectious capability. The elimination of viruses from an organism occurs via saliva, nasal secretion, urine, semen and feces (Kreutz, 2001). The lack of therapeutic processes or immunization for viruses confers an enormous importance on prophylactic measures, making viruses one of the most important pathogenic agents among aquatic organisms (Pavanelli *et al.*, 2002). Besides being one of the sources of elimination of viral agents from the host, it has already been determined that enteric viruses are frequently associated with food contamination, probably due to manipulation errors (Schmid *et al.*, 1977).

In amphibians, skin neoplasms are widely distributed and have already been described in Brazil, such as the occurrence of papillomas in bullfrogs commercially cultivated, but a concrete etiology has not been established to suggest a viral origin (Souza *et al.*, 1985).

Historically, the common development of secondary bacterial infections and misinterpretation of postmortem bacterial invasion were quite likely significant factors in the under diagnosis of viral diseases of amphibians. Now, however, viruses are frequently isolated from captive and wild amphibians and many of them are temperature dependent (Densmore and Green, 2007).

Infection by the *Paramyxoviridae* family is widely distributed among several animal species, such as bovine, swine, equine, birds (Catroxo *et al.*, 2000) and amphibians (Hipolito *et al.*, 2003), and in excrement from snails of the *Helix aspersa* species (Hipolito, *et al.* 2002). These viruses are characterized by the presence of pleomorphic particles measuring between 150 and 200 nm in diameter and envelopes covered by spicules. These viral particles were also observed in the liver from bullfrog tadpoles that died of unknown causes (Hipolito *et al.*, 2003). This viral group is well-known and causes serious illnesses in several animal species, such

as the serious enteric and respiratory syndrome that affects domestic and wild birds called Newcastle disease (Oliveira Júnior *et al.*, 2005).

The *Coronaviridae* is spread among mammals and is associated with enteritis and diarrhea, which are considered large etiological complexity syndromes (Gregori *et al.*, 2000) and are some of the main morbidity and mortality causes in animals. In frogs we were not able to define diarrhea, but we identified watery intestinal contents. In bovines, infection with *Coronaviridae* is involved in the etiology of severe enteritis with the presence of diarrhea (Brandão *et al.*, 2007). *Coronaviridae* are single stranded RNA viruses, pleomorphic, rounded or elongated, covered in bulbous features and, therefore, have the appearance of a crown, measuring an average of 140 nm in diameter and a total viral size of 160-175 nm (Catroxo *et al.*, 2000). These viruses are also associated with diarrhea in wild birds (Catroxo *et al.*, 2000).

The Herpes viral group is one of the most known and studied, and is widely distributed in production animal populations and in the human population. Genetic studies attribute the co-evolution of this viral group with its hosts where latent infections occur, without resulting in generally serious illnesses with high mortality, thus favoring the dissemination of the *Herpesviridae* (Franco and Roehe, 2007). However, *Herpesviridae* subfamilies are considered the main pathogens in bovines, goats and sheep, and seriously harm the reproduction of these animals, which generates economic damages to livestock industries (Dias *et al.*, 2008). In bovines, the *Herpesviridae* family is associated with neurological infections, such as meningitis, and severe respiratory problems. Thus, various studies describe the pathology associated with *Herpesviridae* infection and possible treatments, and immunization of production animals to combat this viral group (Flores *et al.*, 2009).

Herpesvirus are DNA viruses found in various well-known illnesses, such as Aujeszky's disease in swine (Pongillupi *et al.*, 2008), and are easily identified in cellular cultures due to their cytopathic effects (Flores *et al.*, 2009). Advanced genetic studies and PCR identification (Pongillupi *et al.*, 2007), as well as serological research for the *Herpesviridae* are also

widespread. In wild amphibians the *Herpesviridae* family is the only one of the observed groups which is associated with a determined pathological process, such as the development of Lucke tumors (Williams *et al.*, 1996). In bullfrogs from frog farms Hipolito *et al.*, 2003 identified Herpesvirus particles in the liver and ascitic liquid from dead animals.

Infection by Parvovirus is widespread among domestic animals such as dogs and causes severe gastroenteritis, mainly in puppies, with the development of a highly characteristic clinical profile (Strottmann *et al.*, 2008). These DNA viruses can be identified through serology, which is widely used for diagnosing these agents. Hemagglutination and PCR are used for differential diagnosis, since this infection has an endemic characteristic in the populations' possible hosts (Strottmann *et al.*, 2008).

The morphological features observed were also reported in other studies such as: birds (Catroxo *et al.*, 2012), frogs (Hipolito *et al.* 2002; 2003), mammals (Catroxo *et al.*, 2010) and ferrets (Gregori *et al.*, 2010).

Some animals can be asymptomatic carriers of viruses and, upon impairment of immunity, can initiate a viral process. The inability to confirm whether the presence of the virus was related to the animal's cause of death makes studying the pathology of such virus infections more difficult (Catroxo *et al.*, 2003).

As confirmed by Flores (2007), the viral groups discussed here affect many animals, not only domestic and wild animals, but also endothermic and ectothermic (Franco and Roehe, 2007). Therefore, the use of biosecurity principles is the best solution in animal cultivation to prevent sanitary problems and serious economic impacts (Bordin *et al.*, 2005) because the viruses are present among all animal groups. The confinement of large numbers of unfamiliar animals and non-implementation of basic cleanliness procedures can generate serious problems and economic damages, making the enterprises of aquatic organism cultivation impractical (Hipolito *et al.*, 2002). The adoption of these concepts that involve biosecurity is unquestionably indispensable, and some HACCP procedures (Hazard Analysis and Critical Control Points) and GMPs (Good Management

Practice) can be suggested to improve the productive performance of the commercial cultivation of frogs.

CONCLUSION

The use of the negative contrast technique for viral particle detection in intestinal contents should be disseminated and used for the quick diagnosis of virus infection.

ACKNOWLEDGMENTS

To the Electron Microscopy Laboratory of the Biological Institute for the use of their services, and CAPES from the Fisheries Institute of São Paulo for the stipend granted.

REFERENCES

- BORDIN, R.A.; PEREIRA, C.A.D.; EBOLI, M. *et al.* Biosseguridade aplicada nas granjas de aves e de suínos. *Rev. Cienc. Vet.*, v.3, p.11-16, 2005.
- BRANDÃO, P.E.; GREGORI, F.; SFORSIN, A.J. *et al.* Winter Dysentery in cows Associated with Bovine *Coronaviridae* (BCoV). *Arq. Bras. Med. Vet. Zootec.*, v.59, p.45-49, 2007.
- BUENO-GUIMARÃES, H.M. *Avaliação da resposta da Rana catesbeiana frente às variações ambientais: determinação das condições ideais de manutenção em biotério e da resposta aos poluentes aquáticos.* 1999. 180p Dissertação (Mestrado em Medicina) - Faculdade de Medicina, Universidade de São Paulo, São Paulo
- CATROXO, M.H.B.; GODOY, S.N.; MILANELO, L.; CURI, N.A. Detecção de Partículas Semelhantes ao Coronavírus em Intestino Delgado de Quati (*Nosua nosua*) por Microscopia Eletrônica de Transmissão. *Arq. Inst. Biol.*, v.70, p.544-548, 2003.
- CATROXO, M.H.B.; MARTINS, A.M.C.R.P.F.; PETRELLA, S. *et al.* Avian paramyxoviruses. Detection by transmission electron microscopy techniques. *Int. J. Morphol.*, v.30, p.723-730, 2012.

- CATROXO, M.H.B.; MIRANDA, L.B.; LAVORENTI, A. *et al.* Detection of Coronavirus in Capybaras (*Hydrochoeris hydrochaeris*) by transmission electron microscopy. *Int. J. Morphol.*, v.28, p.549-555, 2010.
- CATROXO, M.H.B.; SILVA, J.C.R.; MENEZES, A.C. Presença de Partículas Semelhantes a Corona e Paramixo Vírus em Fezes de Aves Silvestres (Passeriformes e Psittaciformes) In: SANTOS, M.A. (ed) *A ornitologia no Brasil: Pesquisa atual e Perspectivas*. EDUERJ, 2000. p.161-169.
- DENSMORE, C.L.; GREEN, D.L. Diseases of amphibians. *ILAR Journal*, v.48, p.235-254, 2007.
- DIAS, J.A.; ALFERI, A.A.; MEDICI, K.C. *et al.* Fatores de Risco Associados à Infecção pelo Herpesvírus Bovino 1 em Rebanhos bovinos da Região Oeste do estado do Paraná. *Pesq. Vet. Bras.*, v.28, p.161-168, 2008.
- DIAS, D.C.; STEFANI, M.V.; FERREIRA, C.M. *et al.* Haematological and immunological parameters of bullfrog, *Lithobates catesbeianus*, fed with probióticos. *Aquac. Res.* v.41, p.1064-1071, 2008.
- FERREIRA, C.M.; PIMENTA, A.G.C.; PAIVANETO, J.S. Introdução à Ranicultura. *Bol. Inst. Pesca*, v.33, p.1-15, 2002.
- FLORES, E.F. Estrutura e Composição dos Vírus. In: FLORES, E.F. (ed) *Virologia Veterinária*, Editora UFSM: Santa Maria. 2007. p.19-36.
- FLORES, E.F.; WEIBLEN, R.; VOGEL, F.S.F. *et al.* Neuropatogênese experimental da Infecção pelo Herpesvírus Bovino tipo 3 em Coelho. *Pesq. Vet. Bras.*, v.29, p. 1-16, 2009.
- FRANCO, A.C.; ROECHE, P.M. Herpesviridae. In: FLORES, E.F. (ed) *Virologia Veterinária*, UFSM Santa Maria, 2007. p.433-488.
- FROST, D.R.; GRANT, T.; FAIVOVICH, J. *et al.* The amphibian tree of life. *Bull. Am. Mus. Nat. Hist.*, v.297, p.1-370, 2006.
- GREGORI, F.; BRANDÃO, P.E.; ROSALES, C.A.R. *et al.* Desenvolvimento de um Método de ELISA para a Detecção de Rotavírus a partir de Material Fecal. *Arq. Inst. Biol.*, v.67, p.191-194, 2000.
- GREGORI, F.; CATROXO, M.H.B.; LOPES, V.S. *et al.* Occurrence of ferret enteric coronavirus in Brazil (Preliminary Report). *Braz. J. Vet. Res. Anim. Sci.*, v.47, p.156-158, 2010.
- GREGORI, F.; RUIZ, V.L.A.; BERSANO, J.G.; CENTOFANTI, T. Rotavírus em Criações de Suínos. *O Biológico*, v.66, p.11-12, 2004.
- HIPOLITO, M.; BACH, E.E. Patologias em rã-touro (*Rana catesbeiana*, Shaw, 1802) primeira revisão da bibliografia Brasileira. *Arq. Inst. Biol.*, v.69, p.113-115, 2002.
- HIPOLITO, M.; CATROXO, M.H.B.; CURI, N.A.; BACH, E.E. Detecção ao Microscópio Eletrônico de Transmissão de partículas virais Semelhantes aos Grupos Herpes, Toga e Paramixovírus em rãs-touro (*Rana catesbeiana* Shaw, 1802) criadas Comercialmente. Primeiras Observações no Brasil. *Arq. Inst. Biol.*, v.70, p.107-111, 2003.
- HIPOLITO, M.; CATROXO, M.H.B.; CURI, N.A.; SCHMICH, H. Detecção ao Microscópio Eletrônico de Transmissão de partículas virais do grupo Toga e Paramixovírus em Mollusca Gastropoda Pulmonata *Helix aspersa* (escargot) Helicidae e grupo Paramixovírus em lesma *Aginulus sp.* Veronicelidae. *Arq. Inst. Biol.*, v.69, p.113-115, 2002.
- JOHNSON, A.J.; WELLEHAN, J.F. Amphibian virology. *Vet. Clin. North Am. Exot. Anim. Pract.*, v.8, p.53-65, 2005.
- KREUTZ, L.C. Imunidade Contra Vírus. In: MADRUGA, C.R.; ARAÚJO, F.R.; SOARES, C.O. (Eds) *Imunodiagnóstico em Medicina Veterinária*, Embrapa, Campo Grande. 2001. p.19-46.
- MAZZONI, R.; MESQUITA, A.B.; FLEURY, L.F.F. *et al.* Mass mortality associated with a frog vírus 3-like Ranavírus infection in farmed tadpoles *Rana catesbeiana* from Brazil. *Dis. Aquat. Org.*, v.86, p.181-191, 2009.
- MOURIÑO, J.L.P.; STÉFANI, M.V. Avaliação de métodos de coleta de fezes para determinação de digestibilidade protéica em rã-touro (*Rana catesbeiana*). *Cienc. Rural*, v.36, p.1-7, 2006.
- OIE Organização Internacional de Epizotias. <<http://www.oie.int>> Accessed 18 September, 2010.

- OLIVEIRA JUNIOR, J.G.; SCHIAVO, P.A.; DORETTO JUNIOR, L. *et al.* Isolamento e Caracterização biológica da Amostra JAP99 do Vírus da Doença de Newcastle Isolada em Patos Domésticos (*Neta sp.*) no Rio de Janeiro. *Cienc. Rural*, v.35, p.948-951, 2005.
- PAVANELLI, G.C.; EIRAS, J.C.; TAKEMOTO, R.M. (eds) *Doenças de Peixes*. Universidade Estadual de Maringá, Maringá. 2002. p.311.
- PONGILUPPI, T.; BERSANO, J.G.; BOASAWAARGES, S.R.T. *et al.* Padronização da Técnica de Contrastação Negativa para a Identificação de paramixovírus em Sêmen de Suíno. *Laes & Haes*, v.172, p.126-140, 2008.
- PONGILUPPI, T.; BERSANO, J.G.; MORENO, A.M. *et al.* Pesquisa de agentes virais em semen de suínos pelas técnicas de microscopia eletrônica de transmissão e PCR (Reação em cadeia da Polimerase). *Laes & Haes*, v.166, p.108-127, 2007
- SCHMID, A.W.; STEWIEN, K.E.; CANDEIAS, J.A.N. Evidenciação de Vírus patogênico Humano em Filés de Peixe. *Rev. Saúde Pub.* v.11, p.405-409, 1977.
- SOUZA, C.W.O.; ARANTES, G.J.; COELHO, H.E. *et al.* Papiloma em Rãs-touro (*Rana catesbeiana*, Shaw, 1802). *Rev. C. Cienc. Biom. Univ. Fed. Uberlândia*, v.1, p.63-65, 1985.
- STROTTMANN, D.M.; SCORTEGAGNA, G.; KREUTZ, L.C. *et al.* Diagnóstico e estudo Sorológico da Infecção pelo Parvovírus canino em Cães de Passo Fundo, Rio Grande do Sul, Brasil. *Cienc. Rural*, v.38, p.400-405, 2008.
- WILLIAMS, J.W.; TWEEDELL, K.S.; STERLING, D. *et al.* Oncogenic herpesvírus DNA absence in Kidney cell lines established from the northern leopard frog *Rana pipiens*. *Dis. of Aqu. Org.*, v.27, p.1-4, 1996.
- ZUPANOVIC, Z.; LOPEZ, G.; HYATT, A.D. *et al.* Giant toads *Bufo marinus* in Australia and Venezuela have antibodies against 'ranaviruses'. *Dis. Aquat. Org.*, v.32, p.1-8, 1998.