



Comparison of two surgical approaches for Laparoscopic Ovum Pick Up in Ewes

[*Comparação de duas abordagens cirúrgicas para aspiração folicular laparoscópica em ovelhas*]

R.S.G. Mariano¹, R.A.R. Uscategui², R.P. Nociti¹, F.F.P.C. Barros³,
V.J.C. Santos¹, L.N. Coutinho⁴, L.C. Padilha-Nakaghi¹, P.D.A. Silva¹,
P.P.M. Teixeira⁵, W.R. R. Vicente¹

¹Universidade Estadual Paulista - Jaboticabal, SP

²Universidade Federal dos Vales do Jequitinhonha e Mucuri – Unaí, MG

³Universidade Federal Rural do Rio de Janeiro – Seropédica, RJ

⁴Universidade Federal Rural da Amazônia - Belém, PA

⁵Universidade Federal do Pará - Castanhal, PA

R.S.G. Mariano
<https://orcid.org/0000-0002-3826-5317>
R.A.R. Uscategui
<https://orcid.org/0000-0002-9760-8631>
R.P. Nociti
<https://orcid.org/0000-0002-0831-5264>
F.F.P.C. Barros
<https://orcid.org/0000-0003-2071-6930>
V.J.C. Santos
<https://orcid.org/0000-0001-6979-5380>
L.N. Coutinho
<https://orcid.org/0000-0002-9579-3052>
L.C. Padilha-Nakaghi
<https://orcid.org/0000-0002-6291-6183>
P.D.A. Silva
<https://orcid.org/0000-0002-5517-4644>
P.P.M. Teixeira
<https://orcid.org/0000-0001-8828-8675>
W.R. R. Vicente
<https://orcid.org/0000-0001-7696-0962>

ABSTRACT

The present study had as an aim to evaluate a right lateral access as an alternative method to laparoscopic ovum pick-up (LOPU) in sheep. Twenty-four Santa Ines ewes were randomly assigned in two groups with twelve animals each: RLD - positioned in right lateral decubitus, with 10° head-down tilt; and DD – positioned in dorsal decubitus with 35° head-down tilt. The following parameters were evaluated every 10 minutes during the procedure: total surgical time (ST), visualized follicles (VF), aspirated follicles (AF), recovered oocytes (RO), mean arterial pressure (MAP), heart rate (HR), respiratory rate (fR) and end tidal CO2 pressure (EtCO2). Pre and postoperative arterial hemogasometry parameters (PaO2, PaCO2, pH, CHCO3 and BE) were also evaluated; and serum fibrinogen levels (SFL) on postoperative period. The values of VF, AF, RO, fR, PaO2, pH, CHCO3, BE and SFL were similar between groups, although ST, HR, MAP, EtCO2 and PaCO2 were higher in LG. Regarding operative periods, PaO2 and pH were lower after surgery (PaO2: 79.1±16.4; 79.2±11.7mmHg; pH: 7.30±0.09; 7.32±0.08) in both groups when compared to preoperative (PaO2: 80.1±14.3; 83.4±10.5 mmHg; pH: 7.38±0.05; 7.39±0.05) while PaCO2 (43.6±4.6; 41.9±5.4mmHg) and CHCO3 (22.8±1.5; 22.7±3.0mmol/L) increased (PaCO2: 54.3±10.9; 46.9±6.3mmHg; CHCO3: 24.8±3.4; 24.4±2.7mmol/L) postoperative. This alternative decubitus presented is a viable procedure and did not differ in oocyte recovery rates in ewes. However, entails cardiorespiratory major alterations compared to conventional procedure, making its practical applicability limited.

Keywords: ovine, surgery, biotechnology, genitourinary

RESUMO

O presente estudo teve como objetivo avaliar o acesso lateral direito como um método alternativo para a recuperação de oócitos por laparoscopia (LOPU) em ovelha. Vinte e quatro ovelhas Santa Inês foram distribuídas aleatoriamente em dois grupos com 12 animais: grupo RLD – posicionado em decúbito lateral direito, cefalodeclive com 10° de inclinação; grupo DD – posicionado em decúbito dorsal em cefalodeclive, inclinação de 35°. Foram avaliados, a cada 10 minutos, durante o procedimento cirúrgico: tempo total da cirurgia (ST), folículos visualizados (VF), folículos aspirados (AF), oócitos recuperados (RO), pressão arterial média (MAP), frequência cardíaca (FC), frequência respiratória (fR) e pressão final de CO2 (EtCO2). Também foram avaliados os parâmetros de hemogasometria arterial pré-operatória e pós-operatória (PaO2, PaCO2, pH, CHCO3 e BE), bem como os níveis séricos de fibrinogênio (SFL) no período pós-operatório. Os valores de VF, AF, RO, fR, PaO2, pH, CHCO3, BE e

Recebido em 6 de outubro de 2017

Aceito em 25 de setembro de 2018

E-mail: renata_sgm@hotmail.com

SFL foram semelhantes entre os grupos, embora ST, FC, MAP, EtCO₂ e PaCO₂ tenham sido maiores em RLD. Os parâmetros PaO₂ e pH foram menores após a cirurgia (PaO₂: 79,1±16,4; 79,2±11,7mmHg; pH: 7,30±0,09; 7,32±0,08) em ambos os grupos em relação ao momento pré-cirúrgico (PaO₂: 80,1±14,3; 83,4±10,5mmHg; pH: 7,38±0,05; 7,39±0,05), enquanto PaCO₂ (43,6±4,6; 41,9±5,4mmHg) e CHCO₃ (22,8±1,5; 22,7±3,0mmol/L) aumentaram (PaCO₂: 54,3±10,9; 46,9±6,3mmHg; CHCO₃: 24,8±3,4; 24,4±2,7mmol/L) após a cirurgia. O decúbito lateral é uma alternativa viável para LOPU e não apresenta diferença para a taxa de recuperação oocitária em ovelhas. No entanto, promove alterações cardiorrespiratórias em comparação com o decúbito dorsal, tornando a sua aplicabilidade prática limitada.

Palavras-chave: ovino, cirurgia, biotecnologia, geniturinário

INTRODUCTION

Video-assisted laparoscopic ovum pick up (LOPU) is a minimally invasive procedure, with great importance in ovine and caprine reproductive biotechnologies. It allows oocytes recovery for *in vitro* embryo production and other techniques, enhancing herd reproduction (Cordeiro *et al.*, 2014; Teixeira *et al.*, 2013; Basso, 2008). Nevertheless, this procedure causes physiological alterations on cardiovascular and respiratory systems (Cohen *et al.*, 2003), due to tilt head-down positioning and abdomen insufflation necessary for ovaries visualization and manipulation (Fischer *et al.*, 1995).

Among physiological disorders related to this surgical technique it is worth mentioning the reduction of functional residual lung capacity and complacency, blood oxygenation, respiratory volume and cardiac output; increase in airway pressure, intra abdominal pressure (IAP), peripheral vascular resistance, central venous and arterial pressure, and imbalance on alveolar ventilation-perfusion relation (Chandrakanth and Talamini, 2001; Schauer, 2000; Kraut *et al.*, 1999; Struthers e Cuschieri, 1998; Jorisj *et al.*, 1993; Hayden e Cowman, 2011; Sharma *et al.*, 1996).

Therefore, trying to mitigate cardiorespiratory changes caused by traditional LOPU, an alternative laparoscopic approach was developed, where the animal stays in lateral recumbency with a lower head-down inclination angle, hypothesizing that it would be possible to recover the same amount of oocytes, reducing large vessels and thorax compression, and consequently cardiovascular and respiratory adverse effects.

MATERIAL AND METHODS

All animal procedures were approved by Animal Ethics and Welfare Committee of the Faculty of Agricultural and Veterinary Sciences, Univ. Estadual Paulista "Júlio de Mesquita Filho", Jaboticabal, Brazil (protocol N° 009761/13).

Animals were assigned to one of two groups: i) group RLD - positioned in right lateral decubitus, with 10° head-down tilt; ii) group DD - positioned in dorsal decubitus with 35° inclination.

Twenty-four adult multiparous Santa Ines ewes, aged 3.1±1.1 years, weighing 35.1±6.2kg and exhibiting a mean body score of 3 (scale 1-5, Jefferies, 1961), were selected for this study, following clinical examination, blood analysis (hemogram, total proteins, fibrinogen and parasite control) and ultrasonography of the reproductive tract.

Briefly, animals were fasted then sedated with intramuscularly (IM) administration of chlorpromazine hydrochloride (0.5mg/kg - Clorpromazina®, Uniao Quimica, Sao Paulo, Brazil) and tramadol hydrochloride 4mg/kg (Cloridrato de Tramadol®, Hipolabor, Sabara, Brazil) combination. After 10min, jugular vein was catheterized using a 16G catheter (Angiocath-N®, BD, Brazil) and general anesthesia induced intravenously (IV) with ketamine 5mg/kg (Dopalen® Sespo, Paulinia, Brazil) and midazolam 0.2mg/kg (Dormire®, Cristalia, Itapira, Brazil). Orotracheal intubation using a Magill 7,5F endotracheal tube was performed and anesthesia maintenance using ketamine 10mg/kg/h and midazolam 0.2mg/kg/h diluted in NaCl 0,9% in constant infusion at 5mg/kg/h.

Surgical area was clipped and aseptically prepared using chlorhexidine gluconate 2%. Surgical time was divided into five stages: skin incision (IN); first (P1), second (P2) and third (P3) laparoscopic portals introduction; right (O1) and left (O2) ovaries manipulation and aspiration; final cavity inspection, pneumoperitoneum withdrawal and dermorrhaphy (D). At each stage, times and complications were recorded.

In animals of DD, the surgical procedure was performed according to description of Mariano *et al.*, 2015 (Figure 1 C e D), whereas in RLD surgical approach was made according to pilot study reported by Uscategui *et al.*, 2014 (Figure 1 A e B). CO₂ pneumoperitoneum was established with 5mmHg intra-abdominal pressure (IAP) at 5L/min flow rate. Atraumatic forceps (Babcock Forceps, 5mm, 36cm, Bho Supply®, Esteio-RS, Brazil) were used for uterus, tubes, ovarian bursas, and ovaries manipulation.

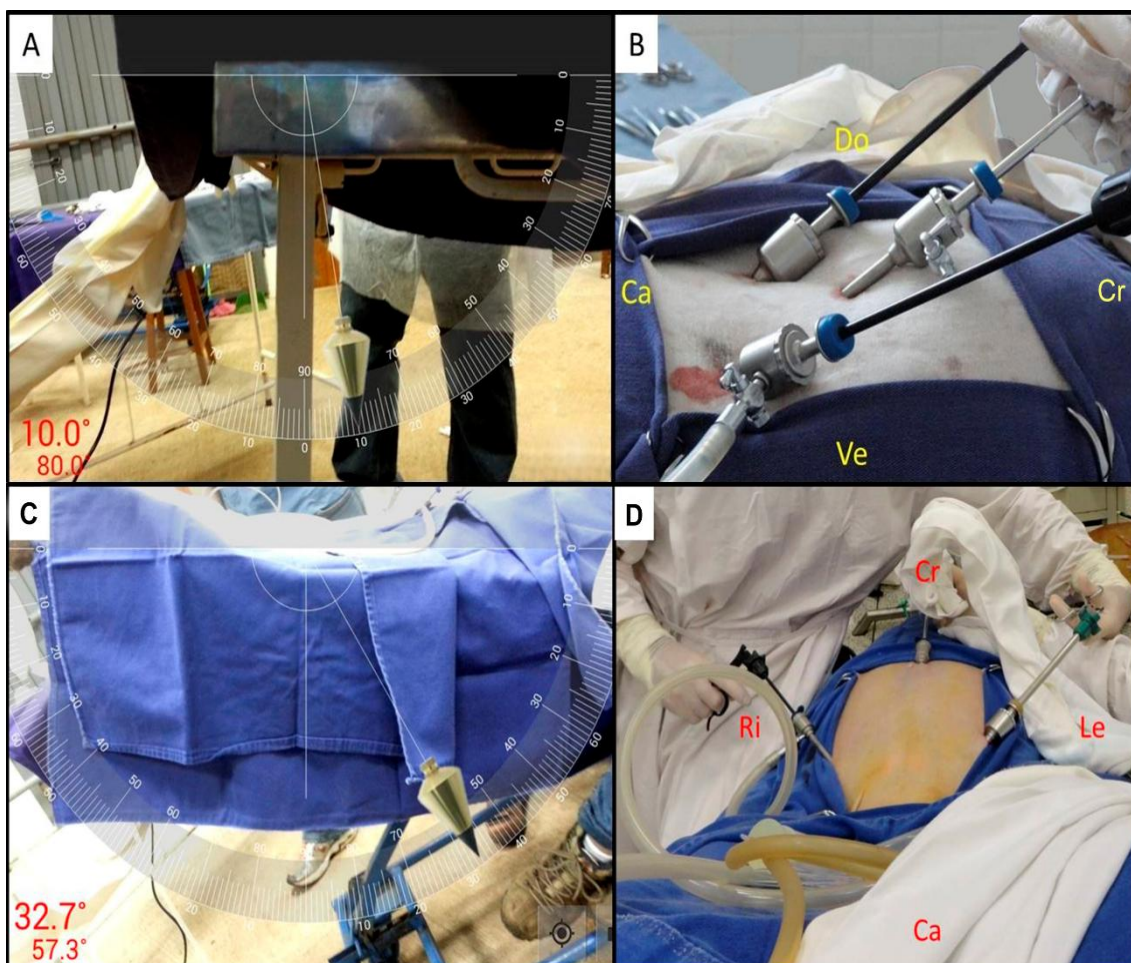


Figure 1. Laparoscopic ovum-pick up (LOPU) in Santa Ines ewe. In (A) and (B) patient positioning in lateral right decubitus and external view of the arrangement of laparoscopic portals in the caudal-cranial direction with the animal in supine position (10°). In (C) and (D), patient in dorsal position with the three laparoscopic portals and the animal in supine position (32.7°).

Prior to follicular aspiration, ovaries were examined and number of follicles measuring 2 to 8mm in diameter were recorded. Visualized follicles (VF), aspirated follicles (AF) and oocytes recovery (OR) were recorded as well. Retrieved oocytes were maintained in harvesting media (PBS supplemented with 10IU/mL heparin at 36°C) and conducted immediately to the laboratory, for observation and oocytes recovered counting in stereo microscope 40x magnification.

At LOPU final stages, ovaries were rinsed with sterile saline solution to remove clots from the ovarian surface in order to avoid the formation of postoperative adhesions. The trocars were removed, pneumoperitoneum completely drained and skin sutured. Surgical wounds were treated with chlorhexidine gluconate 2% followed repellent ointment application (Unguento Plus®, Pearson, Brazil). Post-surgical management was conventionally performed with antibiotics and painkillers use. Following surgery, animals were placed at a recovery room, observed until they were able to stand up unassisted. Furthermore, allocated at an experimental pen, with daily inspection, until clinical discharge.

Blood samples for hemogasometric evaluation were drawn from auricular artery through a puncture and heparinized syringe, which were immediately inserted into the hemogasometer (Omni-CTM® Roche Diagnostics GmbH, Germany) after anesthesia induction and at the end of surgery. Partial pressure of oxygen (PaO₂ in mmHg), partial pressure of carbon dioxide (PaCO₂ mmHg), oxyhemoglobin saturation (SaO₂ in %), base excess (BE in mmol/L), bicarbonate concentration (HCO₃ in mmol/L) and hydrogen potential (pH) were analyzed as well.

Arterial pressure (MAP in mmHg), heart (HR in bpm) and respiratory rate (fR in rpm), end tidal CO₂ tension (EtCO₂ in mmHg) and rectal temperature (T °C) were measured every 10 minutes throughout the surgery.

Systemic inflammatory response was assessed by plasma fibrinogen concentration (mg/dL) measured by heat precipitation (56°C) using a

manual refractometer, during the preoperative period, immediately after and at 2, 4, 6, 8, 10, 12, 14 and 16 days following surgery.

Data were analyzed using R Software® (R Foundation for Statistical Computing version 3.2.1, Vienna, Austria). Foundation for Statistical Computing, Austria). Normality distribution (Shapiro wilk test) and homoscedasticity of variance (Bartlett test) were tested for all variables. Surgical times, VF, AF, and OR were compared between groups by Student's test. Serum fibrinogen concentration, hematological and hemogasometric values and cardiorespiratory parameters were compared between groups by ANOVA and Tukey post-hoc. Statistical significance was declared at P < 0.05.

RESULTS

Number of VF, AF and OR did not differ between groups (P > 0.05). However, surgical time was longer in RLD, and throughout RLD procedure, ovarian manipulation was the most prolonged surgical step (Table 1).

Concerning to cardiorespiratory parameters was also observed that the lateral positioning resulted in an increased heart rate; mean arterial pressure and EtCO₂, whereas there was no respiratory rate or surgical time by groups difference (Table 2).

No differences in PaO₂, SaO₂, pH, HCO₃ and BE were found between groups. However, PaO₂ and pH decreased after surgery ended for both groups, resulting in below species normal range. An increase in PaCO₂ and CHCO₃ during postoperative period was observed, and PaCO₂ was higher in RLD than DD at the same time (Table 3).

Serum levels of plasma fibrinogen were within the normal range for sheep, with no groups or surgical moment difference evaluated (P > 0.05). Furthermore, all animals had a satisfactory recovery from anesthesia and surgery, no complications were observed during postoperative monitoring until clinical discharge.

Table 1. Mean \pm SE of the surgery time, VF, AF, CL and RO of Santa Inês ewes subjected to LOPU under general anesthesia, assessing surgical positioning in groups: DD and RLD

Parameters	Surgical positioning		P-Value
	DD	RLD	
Duration of surgery (min)	42 \pm 2.0	52 \pm 4.0	0.040
First ovary manipulation (min)	14 \pm 1.9	18 \pm 2.6	0.049
Second ovary manipulation (min)	23 \pm 2.2	31 \pm 3.0	0.043
VF	11 \pm 1.2	9 \pm 1.5	0.250
AF	9 \pm 1.0	8 \pm 1.5	0.554
CL	0.8 \pm 0.2	0.5 \pm 0.2	0.294
OR	3.0 \pm 0.6	28 \pm 0.7	0.787

Table 2. Mean \pm SE of cardiorespiratory parameters: HR, fR, MAP, EtCO₂ and T of Santa Inês ewes subjected to LOPU under general anesthesia, evaluating the surgical positioning in groups: DD and RLD

Parameters	Experimental groups		P-value
	DD	RLD	
HR (bpm)	98.3 \pm 3.3	111 \pm 3.6	0.013
fR (rpm)	36.7 \pm 2	40.9 \pm 2.1	0.176
MAP (mmHg)	78 \pm 2.3	87.4 \pm 2.6	0.009
EtCO ₂ (mmHg)	37.3 \pm 1.2	42.5 \pm 1	0.001
T (°C)	37.4 \pm 0.1	37.2 \pm 0.1	0.230

Table 3. Mean \pm SE of arterial hemogasometric parameters: PaO₂, PaCO₂, SaO₂, BE, HCO₃ and pH of Santa Inês ewes submitted to LOPU under general anesthesia, assessing the surgical positioning in groups: DD and RLD

Parameter	RLD		DD		P-value Group	P-value Moment
	Pre	Pos	Pre	Pos		
pH	7.38 \pm 0.05	7.30 \pm 0.09	7.39 \pm 0.05	7.32 \pm 0.08	0.695	<0.001
PaO ₂ (mmHg)	80.1 \pm 14.3	79.1 \pm 16.4	83.4 \pm 10.5	79.2 \pm 11.7	0.691	0.557
PaCO ₂ (mmHg)	43.6 \pm 4.6	54.3 \pm 10.9	41.9 \pm 5.4	46.9 \pm 6.3	0.032	<0.001
CHCO ₃ (mmol/L)	22.8 \pm 1.5	24.8 \pm 3.4	22.7 \pm 3.0	24.4 \pm 2.7	0.797	0.033
SaO ₂ (%)	92.7 \pm 3.5	91.5 \pm 3.7	92.1 \pm 2.2	91.6 \pm 2.6	0.752	0.341
BE (mmol/L)	-0.81 \pm 1.4	-0.37 \pm 2.5	-1.84 \pm 2.2	-0.99 \pm 2.3	0.216	0.344

DISCUSSION

The alternative laparoscopic approach provided an excellent reproductive organs access, manipulation and visualization. Number of follicles aspirated and oocytes recovered, which are crucial of this technique, did not differ

between groups similarly as data reported by Stangl *et al.* (1999) in sheep hormonally untreated. Preliminary studies were conducted to evaluate the viability of laparoscopic side access to the uterus and ovaries in lateral decubitus position (Uscategui *et al.*, 2014). Initially, the procedure were tried to perform in horizontal

position with no inclination, although compromising reproductive organs manipulation, mainly due to rumen position, which strenuous uterine horns and ovaries visualization. The head-down 10° inclination of animals was enough for side access LOPU performance (Figure 1A), as described by Allen (1996) who also emphasizes in reduction of iatrogenic injury risk during trocars introduction.

Normal cardiorespiratory function may be impacted because of recumbency positioning, head-down tilt, and pneumoperitoneum (Clarke *et al.*, 2014; Hayden and Cowman, 2011). Furthermore, acidosis, hypercapnia, hypoxia, and bicarbonate concentration spurt were observed in both experimental groups as a procedure consequence. Induced pneumoperitoneum limits diaphragm movement, raises intrathoracic pressure (ITP), reduces complaisance and residual functional lung capacity, increases CO₂ absorption and may results in atelectasis, ventilation-perfusion relationship imbalance, hypoxia and hypercapnia (Joris, 2009; Ferrão, 2016; Lemos *et al.*, 2003; Duke *et al.*, 1996).

Therefore, PaCO₂ elevation is an expected result in this type of intervention (Hayden e Cowman, 2011; Gudmundsson e Heltné, 2004; Donaldson *et al.*, 1998;) leading to respiratory acidosis (O'Learly *et al.*, 1996; Hirvonen *et al.*, 1995). HCO₃ arterial blood concentration upsurge results from changes in blood pH and PaCO₂ and was considered as compensatory measure of acid-basic imbalance (Haskins, 2015; Clarke *et al.*, 2014), moreover similar results have been reported in sheep and humans who underwent to laparoscopy procedures (Lopes, 2014; Córrea *et al.*, 2008; Oliveira, 2005). Additionally, alteration described in spontaneous ventilated anesthetized ruminants was hypoventilation with hypercapnia (Campos and Roll, 2003; Wilson *et al.*, 2000) and these effects could be controlled with positive pressure ventilation, however, studies are needed to confirm this assertion in lateral recumbency animals, moreover this measure is considered impractical to field in this type of patients.

We believe that performing side access LOPU needs head-down inclination and CO₂ pneumoperitoneum, a slight inclination and lateral recumbency positioning can reduce diaphragmatic and great vessels compression,

and consequently cardiorespiratory alterations. However, the animals in RLD showed greater alterations than DD (MAP, HR, PaCO₂ and EtCO₂ elevation).

Although only few studies evaluating lateral position for laparoscopic procedures are available (Hazebroek e Bonjer, 2006; Fujise *et al.*, 1998; Mullet *et al.*, 1993), in humans, scientific evidences suggest that laparoscopic procedures in lateral recumbency causes increased CO₂ absorption, due to a higher amount of soft tissue exposed to gas. Consequently, vasodilation and sympathetic stimulation, tachycardia and hypertension occurs (Rasmussen *et al.* 1978), as evidenced in our results. Studies also reported that IAP increase causes vasoactive factors release, which leads hypertension and tachycardia, including normal partial arterial pressure values of CO₂ (Punnonrn and Viinaniaki, 1982). Nevertheless, IAP established in both groups were the same, hemodynamic changes notable in RLD.

Lateral approach resulted in longer surgery time, caused by digestive tract presence in the surgical field. However, training and experience reduces surgery times (Teixeira *et al.*, 2013), in this study initial phase side access LOPU took up to 74 minutes and at final stage this time fell to 34 minutes.

Some complications were observed, and there were no significant associations between position-related injuries. One ewe from the DG group died due to cardiorespiratory collapse, possibly by inadvertent intravenous CO₂ insufflation, since autopsy revealed pulmonary ischemic injury. In LG, one rumen perforation during first trocar blind introduction, in this case surgical repair was performed without clinical consequences. Hayden and Cowman (2011) have described laparoscopic complications as common interurrences.

As described by Meyer *et al.* (1995), high levels of fibrinogen indicate the existence of an inflammatory process, however, plasma fibrinogen levels were within the normal set values in sheep (Jain, 1993). Thus, we do not consider that the laparoscopic procedure induced inflammatory response, corroborating Teixeira *et al.* (2015) results in lambs subjected to laparoscopy.

CONCLUSION

Side access LOPU technique is a viable procedure for oocyte recovery in Santa Inês ewes. However, entails cardiorespiratory major alterations compared to conventional procedure, making the practical applicability limited.

ACKNOWLEDGEMENT

The authors would like to thank São Paulo Research Foundation (FAPESP) [process 2013/09053-0] to the financial support. This study was financed in part by the Coordenação de Aperfeiçoamento de Pessoal de Nível Superior - Brasil (CAPES) - Finance Code 001.

REFERENCES

- ALLEN, P.D. Anesthesia for minimally invasive surgery. In: LOUGHLIN, K.R.; BROOKS, D.C. *Principles of endosurgery*. Cambridge: Blackwell Science, 1996. p.54-71.
- BASSO, A.C.; MARTINS, J.F.P.; FERREIRA, C.R. *et al.* Produção *in vitro* de embriões ovinos: aspectos da técnica de aspiração folicular e do tratamento hormonal de doadoras. *Embrião*, v.38, p.8-11, 2008.
- CAMPOS, F.G.C.M.; ROLL, S. Complicações do acesso abdominal e do pneumoperitônio em cirurgia laparoscópica. Causas, prevenção e tratamento. *Rev. Bras. Videocir.*, v.1, p.21-28, 2003.
- CHANDRAKANTH, A.; TALAMINI, M.A. Current knowledge regarding the biology of pneumoperitoneum-based surgery. In: SOPER, N.J. *Problems in general surgery*. Philadelphia: Lippincott Williams & Wilkins, 2001. p.52-63.
- CLARKE, K.W.; TRIM, C.M.; HALL, L.W. *Veterinary anaesthesia*. 11.ed. London: Elsevier, 2014. p.135-137.
- COHEN, R.V.; PINHEIRO FILHO, J.C.; SCHIAVON, C.A.; COFREIA, J.L.L. Alterações sistêmicas e metabólicas da cirurgia laparoscópica. *Rev. Bras. Videocir.*, v.2, p.77-81, 2003.
- CORDEIRO, M.F.; TEIXEIRA, P.P.M.; OLIVEIRA, M.E.F. *et al.* Reproductive efficiency of adult and prepurbetal goats subjected to repeated follicular aspiration. *Arq. Bras. Med. Vet. Zootec.*, v.66, p.137-144, 2014.
- CORREA, C.M.O.; BRANDAO, M.J.N.; HIRATA, E.S.; UDESLSMANN, A. Considerações anestésicas na cirurgia laparoscópica. *Arq. Bras. Cir. Dig.*, v.21, p.136-138, 2008.
- DONALDSON, L.L.; TROSTLE, S.S.; WHITE, N.A. Cardiopulmonary changes associated with abdominal insufflation of carbon dioxide in mechanically ventilated, dorsally recumbent, halotane anaesthetized horses. *Equine Vet. J.*, v.30, p.144-151, 1998.
- DUKE, T.; STEINACHER, S.L.; REMEDIOS, A.M. Cardiopulmonary effects of using carbon dioxide for laparoscopic surgery in dogs. *Vet. Surg.*, v.25, p.77-82, 1996.
- FERRÃO, I.M.R.D. *Estabelecimento do pneumoperitoneu para laparoscopia em canídeos: estudo comparativo de três técnicas*. 2016. Dissertação (Mestrado em Integrado em Medicina Veterinária) - Faculdade de Medicina Veterinária, Universidade de Lisboa, Lisboa, POR.
- FISCHER, A.T.J.R.; VACHON, A.M.; KLEIN, S.R. Laparoscopic inguinal herniorrhaphy in two stallions. *J. Am. Vet. Med. Assoc.*, v.207, p.1599-601, 1995.
- FUJISE, K.; SHINGU, K.; MATSUMOTO, S. *et al.* The effects of the lateral position on cardiopulmonary function during laparoscopic urological surgery. *Anaesth. Anal.*, v.87, p.925-930, 1998.
- GUDMUNDSSON, F.F.; HELTNE, J.K. Respiratory changes during prolonged increased intra-abdominal pressure in pigs. *Acta Anaesthesiol. Scand.*, v.48, p.463-468, 2004.
- HASKINS, S.C. Monitoring anesthetized patients. In: LUMB & JONES *Veterinary anesthesia and analgesia*. Ames, Iowa: Wiley-Blackwell, 2015. p.86-113.

- HAYDEN P.; COWMAN S. Anaesthesia for laparoscopic surgery. *Cont. Educ. Anesth. Critical Care Pain*, v.11, p.177-180, 2011.
- HAZEBROEK, E.J.; BONJER, H.J. Effect of patient position on cardiovascular and pulmonary function. In: WHELAN, R.L.; FLESHMAN, J.W.; FOWLER, D.L. (Eds.). *The sages perioperative care in minimally invasive surgery*. New York: Springer, 2006. 410p.
- HIRVONEN, E.A.; NUUTINEN, L.S.; KAUKO, M. Hemodynamic changes due to Trendelenburg positioning and pneumoperitoneum during laparoscopic hysterectomy. *Acta Anaesthesiol. Scand.*, v.39, p.949-995, 1995.
- JAIN, N.C. *Essentials of veterinary hematology*. Philadelphia: Lea & Febiger, 1993. 417p.
- JORIS, J.L.; NOIROT, D.P.; LEGRAND, M.I.; JACQUET, N.J.; LAMY, M.L. Hemodynamic changes during laparoscopic cholecystectomy. *Anesth. Analg.*, v.76, p.1067-1071, 1993.
- JORIS JL. Anaesthesia for laparoscopic surgery. In: *Text Book of Anaesthesia*. 7th ed. Elsevier Health Sciences. p. 2185–2202, 2009.
- KRAUT, J.K.; ANDERSON, J.T.; SAFWAT, A.; BARBOSA, R.; WOLFE, B.M. Impairment of cardiac performance by laparoscopy in patients receiving positive end expiratory pressure. *Arch. Surg.*, v.134, 76-80, 1999.
- LEMOS, S.L.S., VINHA, J.M., SILVA, I.S. *et al.* Efeitos do pneumoperitônio com ar e CO₂ na gasometria de suínos. *Acta Cir. Bras.*, v.18, 445-451, 2003.
- LOPES, M.C.S. *Achados clínicos, hemodinâmicos e hemogasométricos da infusão contínua de propofol associado ou não ao tramadol em ovelhas submetidas à videolaparoscopia*. 2014. 108f. Tese (Doutorado Cirurgia Veterinária) - Universidade Estadual Paulista Júlio de Mesquita Filho, Faculdade de Ciências Agrárias e Veterinárias de Jaboticabal, Jaboticabal, SP.
- MARIANO, R.S.G.; USCATEGUI, R.A.R.; NOCITI, R.P. *et al.* Intraperitoneal lidocaine hydrochloride for prevention of intraperitoneal adhesions following laparoscopic genitourinary tract surgery in ewes. *Vet. Med.*, v.60, p.403-406, 2015.
- MEYER, D.J.; COLES, E.H.; RICH, L.J. *Medicina de laboratorio veterinária: interpretação e diagnóstico*. São Paulo: Roca, 1995. p.47-61.
- MULLETT, C.E.; VIALE, J.P.; SAGNARD, P.E. *et al.* Pulmonary CO₂ elimination during surgical procedures using intra- or extraperitoneal CO₂ insufflation. *Anaesth. Analg.*, 1993, v.76, p.622-626.
- O'LEARY, E.; HUBBARD, K.; TORMEY, W.; CUNNINGHAM, A.J. Laparoscopic cholecystectomy: hemodynamic and neuroendocrine responses after pneumoperitoneum and changes in position. *Br. J. Anaesth.*, v.77, p.640-644, 1996.
- OLIVEIRA, C.R.D. Anestesia para cirurgia videolaparoscópica. *Rev. Bras. Videocir.*, v.3, p.32-42, 2005.
- PUNNONRN, R.; VIINANIAKI, O. Vasopressin release during laparoscopy: role of increased intra-abdominal pressure. *Lancet*, v.1, p.175-176, 1982.
- RASMUSSEN, J.P.; DAUCHOT, P.J.; DEPALMA, R.G. *et al.* Cardiac function and hypercarbia. *Arch. Surg.*, v.113, p.1196-2000, 1978.
- SCHAUER, P.R. Physiologic consequences of laparoscopic surgery. In: EUBANKS, W.S.; SWANSTROM, L.L.; SOPER, N.J. *Mastery of laparoscopic surgery*. Philadelphia: Lippincott Williams & Wilkins, 2000. p.22-38.
- SHARMA, K.C.; BRANDSTETTER, R.D.; BRENSILVER, J.M. Cardiopulmonary physiology and pathophysiology as a consequence of laparoscopic surgery. *Chest*, v.110, p.810-815, 1996.
- STANGL, M.; KÜHHOLZER, B.; BESENFELDER, U.; BREM, G. Repeated endoscopic ovum pick-up in sheep. *Theriogenology*, v.52, p.709-716, 1999.
- STRUTHERS, A.D.; CUSCHIERI, A. Cardiovascular consequences of laparoscopic surgery. *Lancet*, v.15, p.568-570, 1998.

TEIXEIRA, P.P.M.; PADILHA, L.C.; LIMA DA SILVA, A.S. *et al.* Ovum pick-up technique in recently weaned ewe lambs subjected to ovarian stimulation. *Acta Sci. Vet.*, v.43, p.1-9, 2015.

TEIXEIRA, P.P.M.; PADILHA, L.C.; MARIANO, R.S. *et al.* Aspiração folicular. In: OLIVEIRA, M.E.F.; TEIXEIRA, P.P.M.; VICENTE W.R.R. *Biotécnicas reprodutivas em ovinos e caprinos*. São Paulo: MedVet, 2013. 305p.

USCATEGUI, R.; GOMES MARIANO R. S.; PERECIN NOCITI, R. *et al.* Side access lopus in sheep-pilot study. *Reprod. Dom. Anim.*, v.49, p.90-90, 2014.

WILSON D.V., KANTROWITZ A., PACHOLEWICZ J. Perioperative management of calves undergoing implantation of a left ventricular assist device. *Vet. Surg.*, v.29, p.106-118, 2000.