

# Choroidal changes in pre-eclampsia during pregnancy and the postpartum period: comparison with healthy pregnancy

## *Alterações da coróide na pré-eclâmpsia durante a gravidez e período pós-parto: comparação com a gravidez saudável*

NECATI DURU<sup>1</sup>, DÖNDÜ MELEK ULUSOY<sup>1</sup>, AYŞE ÖZKÖSE<sup>1</sup>, MUSTAFA ATAŞ<sup>1</sup>, ARZU SEYHAN KARATEPE<sup>1</sup>, FATMA ATAŞ<sup>2</sup>, HASAN BASRI ARIFOĞLU<sup>1</sup>, UĞUR YILMAZ<sup>3</sup>

### ABSTRACT

**Purpose:** To investigate subfoveal choroidal thickness (SFCT) in patients with pre-eclampsia using enhanced depth imaging optical coherence tomography (EDI-OCT).

**Methods:** A sample of 73 pregnant women was studied over 28 weeks of gestation. The sample was divided into two groups: one comprising pre-eclamptic pregnant women (n=32), and the other comprising healthy pregnant women (n=41). The SFCT was determined for all patients using EDI-OCT during pregnancy and at the third month of the postpartum period.

**Results:** The SFCTs in pre-eclamptic pregnant women were  $351.97 \pm 22.44$  and  $332.28 \pm 20.32 \mu\text{m}$  during the pregnancy and postpartum periods ( $p < 0.001$ ), respectively, whereas these values in healthy pregnant women were  $389.73 \pm 49.64$  and  $329.78 \pm 22.36 \mu\text{m}$  ( $p < 0.001$ ), respectively. During pregnancy SFCT in pre-eclamptic pregnant women was significantly thinner than that in healthy pregnant women ( $p < 0.001$ ). However, there was no statistically significant difference during the postpartum period ( $p = 0.623$ ).

**Conclusions:** The results suggest that SFCT is significantly decreased in pre-eclamptic pregnant women than in healthy pregnant women, despite no statistically significant difference in SFCT existing between the groups during the postpartum period.

**Keywords:** Choroid; Choroid diseases/diagnosis; Tomography, Optical coherence; Pre-eclampsia; Fovea centralis; Axial length; eye; Pregnancy

### RESUMO

**Objetivo:** Investigar espessura subfoveal coroidal (SFCT) em pacientes com pré-eclâmpsia usando imagens de tomografia de coerência óptica de profundidade otimizada (EDI-OCT).

**Método:** Uma amostra de 73 mulheres grávidas foi estudado ao longo de 28 semanas de gestação. A amostra foi dividida em dois grupos: um com mulheres grávidas com pré-eclâmpsia (n=32), o outro com as mulheres grávidas saudáveis (n=41). SFCT foi determinada em todos os pacientes utilizando EDI-OCT durante a gravidez e no terceiro mês do período pós-parto.

**Resultados:** Os SFCTs em gestantes com pré-eclâmpsia foram  $351,97 \pm 22,44 \mu\text{m}$  e  $332,28 \pm 20,32 \mu\text{m}$  durante o período de gravidez e pós-parto ( $p < 0,001$ ), respectivamente. Estes valores em mulheres grávidas saudáveis foram  $389,73 \pm 49,64 \mu\text{m}$  e  $329,78 \pm 22,36 \mu\text{m}$  ( $p < 0,001$ ), respectivamente. Durante a gravidez o SFCT foi significativamente mais fino em mulheres com pré-eclâmpsia quando comparado com as mulheres saudáveis ( $p < 0,001$ ). No entanto, não houve diferença estatisticamente significante no período pós-parto ( $p = 0,623$ ).

**Conclusões:** Os resultados sugerem que SFCT é significativamente mais fino em gestantes com pré-eclâmpsia do que nas mulheres grávidas saudáveis, apesar de não haver diferença estatisticamente significativa na SFCT entre os grupos durante o período pós-parto.

**Descritores:** Coróide; Doenças da coróide/diagnóstico; Tomografia de coerência óptica; Pré-eclâmpsia; Fovea centralis; Comprimento axial do olho; Gravidez

### INTRODUCTION

Pre-eclampsia is a disorder characterized by widespread vasospasm and pathologic lesions in multiple organ systems, including the uteroplacental vascular bed. Observed in 5%-10% of all pregnancies, pre-eclampsia is a major cause of both maternal and fetal mortality and morbidity. It is typically seen after week 20 of gestation and frequently in first pregnancies<sup>(1)</sup>. In the pathophysiology of pre-eclampsia, although endothelial cell damage and impaired endothelial cell function play an important role, the cause of vascular endothelial cell dysfunction remains unknown<sup>(2)</sup>. Numerous organs, including the liver, eye, kidney, and those of the central nervous system, can be affected by pre-eclampsia due to increased systemic blood pressure and vascular endothelial damage<sup>(3)</sup>. Visual loss was reported in 30%-100% of patients with pre-eclampsia and associated with disorders of the choroidal and retinal circulation<sup>(4,5)</sup>. The presentation of the disorder involves lesions caused by ischemia in the retina pigment epithelium (RPE) and the choroid, as well as cotton wool

spots, retinal hemorrhage and edema, papilledema, serous retinal detachment, and Elschnig spots<sup>(6)</sup>.

As such, assessment of the choroid is crucial in ophthalmologic practice for the management of pre-eclampsia, which primarily affects the vascular system. Although indocyanine green angiography and B-scan ultrasonography are usually performed in the clinical assessment of the choroid, neither permits accurate cross-sectional imaging. Consequently, the recently developed optical coherence tomography (OCT) has proven valuable for observing changes in the retina and RPE. Furthermore, a new modality in choroidal imaging with OCT called enhanced depth imaging (EDI) has recently been increasingly used, enabling the acquisition of detailed images of tissues behind the RPE.

This study aimed to investigate subfoveal choroidal thickness (SFCT) in patients with pre-eclampsia during pregnancy and the postpartum period compared with that in healthy pregnant women using EDI-OCT.

Submitted for publication: October 25, 2015

Accepted for publication: February 10, 2016

<sup>1</sup> Department of Ophthalmology, Kayseri Education and Research Hospital, Kayseri, Turkey.

<sup>2</sup> Department of Obstetrics and Gynecology, Kayseri Education and Research Hospital, Kayseri, Turkey.

<sup>3</sup> Department of Ophthalmology, Niğde State Hospital, Niğde, Turkey.

**Funding:** No specific financial support was available for this study.

**Disclosure of potential conflicts of interest:** None of the authors have any potential conflict of interest to disclose.

**Corresponding author:** Necati Duru. Kayseri Education and Research Hospital. Department of Ophthalmology. Kayseri - Turkey - E-mail: necatiduru@gmail.com

## METHODS

### STUDY POPULATION AND DESIGN

This cross-sectional study was conducted in the Ophthalmology and Gynecology Departments at Kayseri Education and Research Hospital in Kayseri, Turkey. The study adhered to the tenets of the Declaration of Helsinki and was approved by the local ethics committee. All participants received oral and written information about the study, and each participant provided written, informed consent.

A sample of 73 pregnant women was examined over a period of 28 weeks during gestation. Gestational age was based on the precise date of the woman's last period and ultrasound measurement of the crown-rump length during the first trimester. Pre-eclampsia was defined as hypertension (blood pressure of  $\geq 140/90$  on at least two occasions  $>4$  h apart after 20 weeks of gestation) and new onset of proteinuria ( $\geq 2+$  on dipstick reading,  $\geq 0.3$  g/d by 24-h urine collection, or  $\geq 30$  mg/mmol by protein-to-creatinine ratio). The study involved two groups: one of pre-eclamptic pregnant women ( $n=32$ ) and another of healthy pregnant women ( $n=41$ ). In cases in which both eyes of the patient were eligible for inclusion, only the right eye was included.

### EXAMINATION PROTOCOL AND STUDY MEASUREMENTS

Each participant received a comprehensive ophthalmologic examination involving best-corrected visual acuity (BCVA), slit lamp biomicroscopy, dilated stereoscopic fundus examination, intraocular pressure (IOP) measured using Goldmann applanation tonometry, as well as axial length (AL) and OCT measurements. All examinations were performed by an experienced clinician (MU). AL was measured using IOL Master 500 (Carl Zeiss Meditec Inc, Jena, Germany). To assess SFCT, OCT (version 5.6.3.0; Spectralis OCT Heidelberg Engineering, Dossenheim, Germany) was used. All measurements were repeated at the third month of the postpartum period. Moreover, to avoid diurnal fluctuation, all examinations were performed between 10 a.m. and 12 a.m.

### EXCLUSION CRITERIA

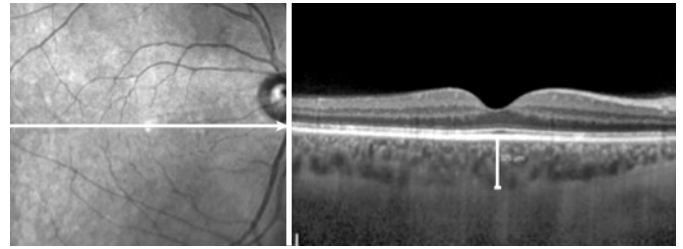
Ocular exclusion criteria for this study included more than two diopters of cylindrical and/or spherical refractive error, a BCVA of less than 20/20, IOP readings  $>21$  mmHg, glaucoma, uveitis, retinal disease, ocular trauma, dense media opacities, or a history of previous intraocular surgery, laser therapy, or significant ocular disease. Participants reporting a history of any medical or obstetrical problems (except pre-eclampsia) were excluded from the study.

### EDI-OCT MEASUREMENT

The method used for obtaining EDI-OCT images was previously reported<sup>(7,8)</sup>. SFCT was measured from the outer portion of the hyper-reflective line corresponding to the RPE to the inner surface of the sclera. Images were acquired by an experienced clinician (MU) and assessed by an experienced clinician (MA), the later was blinded to group identity. A representative EDI-OCT choroidal image in a pregnant woman is seen in figure 1.

### STATISTICAL ANALYSIS

All statistical tests were performed using the Statistical Package for the Social Sciences v.20. Measurements of ocular parameters from the right eyes were used for analyses. For each continuous variable, normality was checked using the Kolmogorov-Smirnov test. Variables between pre-eclamptic pregnant and healthy pregnant women were compared using an independent Student's *t* test, and a paired *t* test was used to compare variables between the pregnancy and postpartum periods in each group. Probability (*p*) values of  $<0.05$  were considered statistically significant.



**Figure 1.** Measurement of subfoveal choroidal thickness performed in a pre-eclamptic pregnant women.

## RESULTS

Table 1 summarizes the demographical and clinical features of the participants. No statistically significant differences were detected in terms of gestational week, age, AL, or IOP between groups ( $p=0.836$ ,  $p=0.106$ ,  $p=0.726$ , and  $p=0.936$ , respectively).

SFCT measurements and *p* values are shown in table 2. SFCT in pre-eclamptic pregnant women was  $351.97 \pm 22.44$   $\mu\text{m}$  (range, 309-403) and  $332.28 \pm 20.32$   $\mu\text{m}$  (range, 301-381) during the pregnancy and postpartum periods, respectively. In healthy pregnant women, these values were  $389.73 \pm 49.64$   $\mu\text{m}$  (range, 320-473) and  $329.78 \pm 22.36$   $\mu\text{m}$  (range, 299-399), respectively. A significant decrease in SFCT during the postpartum period compared with that during the pregnancy period was found in both groups ( $p<0.001$ ), but the decrease in choroidal thickness (CT) was more prominent in healthy pregnant women. SFCT in pre-eclamptic pregnant women during pregnancy was significantly thinner than that in healthy pregnant women ( $p<0.001$ ). However, there was no statistically significant difference in SFCT between the two groups during the postpartum period ( $p=0.623$ ).

## DISCUSSION

Although described as hypertension and proteinuria emerging during the second half of pregnancy, pre-eclampsia is a systemic, complex syndrome involving all body systems, not merely reflected by proteinuria and hypertension. Although its etiology is not entirely known, it is thought to consist of common endothelial damage, increased systemic vascular resistance, and generalized vasospasm caused by inadequate trophoblastic invasion and placentation<sup>(9,10)</sup>.

Traditional methods used for assessing ocular findings in pre-eclampsia have, until recently, included indocyanine green angiography, ocular fluorophotometry and angiography, and Doppler ultrasonography<sup>(11-16)</sup>. Low image resolution, low validity ratio in measurements, and differences between observers are disadvantages of these methods. For these reasons, objective, reliable, quantitative, and highly sensitive imaging methods are required for the diagnosis and follow-up of ophthalmic disease in pregnant women. Appropriate imaging technologies were recently developed, one of which is OCT with a high-resolution tomographic section of the optic nerve head, retinal nerve fiber layer, and retina by using 800-840 nm wavelength light in a non-contact, non-invasive manner. More recently, EDI-OCT was developed for users to observe the morphology, thickness, and anatomy of the choroid.

A structurally and functionally normal choroid is critical to retinal functions. Oxygen and glucose are provided to the RPE and outer layers of the retina by choroidal circulation. The choroid also protects the thermal stability of the ocular tissues and removes ocular waste<sup>(17)</sup>. The structure and thickness of the choroid can be affected by several factors, different ocular pathologies, and systemic diseases<sup>(18-22)</sup>. Ocular pathologies such as choroidal neovascular membrane, uveal effusion syndrome, central serous chorioretinopa-

**Table 1. Demographical and clinical features of healthy and pre-eclamptic pregnant women included in the study**

Variables	Healthy pregnant women (control group)	Pre-eclamptic pregnant women (study group)	p*
Number of eyes/patients	41/41	32/32	
Age (year)			0.106
Average $\pm$ SD	27.54 $\pm$ 5.25	29.59 $\pm$ 5.43	
Range	18-38	18-43	
Gestational week			0.836
Average $\pm$ SD	31.98 $\pm$ 3.82	31.81 $\pm$ 2.89	
Range	28-39	28-37	
Axial length (mm)			0.726
Average $\pm$ SD	23.04 $\pm$ 0.77	23.11 $\pm$ 0.90	
Range	21.13-24.16	21.34-24.67	
Intraocular pressure (mmHg)			0.936
Average $\pm$ SD	13.37 $\pm$ 2.79	13.31 $\pm$ 2.87	
Range	9-19	9-21	

SD= standard deviation; \*= independent Student's t test.

**Table 2. The choroidal thicknesses in healthy and pre-eclamptic pregnant women at pre- and postpartum time points**

	Prepartum (3 <sup>rd</sup> trimester)	Postpartum (3 <sup>rd</sup> month)	p <sup>†</sup>
<b>Healthy pregnant women (SFCT) (<math>\mu</math>m)</b>			
<b>N=41 eyes</b>			
Average $\pm$ SD	389.73 $\pm$ 49.64	329.78 $\pm$ 22.36	<0.001
Range	320-473	299-399	
<b>Pre-eclamptic pregnant women (SFCT) (<math>\mu</math>m)</b>			
<b>N=32 eyes</b>			
Average $\pm$ SD	351.97 $\pm$ 22.44	332.28 $\pm$ 20.32	<0.001
Range	309-403	301-381	
p*	<0.001	0.623	

SFCT= subfoveal choroidal thickness; SD= standard deviation; <sup>†</sup>= paired t test; \* = independent Student's t test.

thy, Vogt-Koyanagi-Harada disease, angioid streaks, and polypoidal choroidal vasculopathy, as well as systemic diseases, including diabetes mellitus, can also affect the choroid<sup>(18-22)</sup>. Other studies have reported decreased CT in correlation with increased refractive errors, AL<sup>(23-25)</sup>, or age<sup>(26)</sup>. Several studies have shown the effect of pregnancy on CT. Takahashi et al. compared CT in 30 healthy and 30 pregnant women and found no statistically significant difference between the groups<sup>(27)</sup>. Kara et al. found SFCT to be significantly increased in pregnant women than in healthy women in their study of 100 pregnant and 100 healthy non-pregnant women. They attributed this result to physiological hemodynamic changes occurring in pregnancy, such as increased cardiac output, arterial compliance, and decreased total vascular resistance<sup>(28)</sup>. Meanwhile, Sayin et al. found CT to be decreased in pre-eclamptic pregnant women than in healthy pregnant women<sup>(29)</sup>. Garg et al. assessed CT during the postpartum period in their study of 15 pre-eclamptic pregnant, 15 healthy pregnant, and 19 healthy non-pregnant women. They found that CT was significantly higher in pre-eclamptic women than in the other groups; a result that they attributed to increased vascular endothelial growth<sup>(30)</sup>. Nevertheless, until now, no study has compared CT in pre-eclamptic pregnant women between the pregnancy and postpartum periods. As such, to the best of our knowledge, the present study is the first to assess SFCT in pre-eclamptic pregnant women during and after pregnancy.

In this study, SFCT was found to be significantly thicker in healthy pregnant women than in pre-eclamptic pregnant women. CT decreased by a statistically significant margin, and both groups had similar values by the third month of the postpartum period. As such, it is possible that choroidal thinning in the pre-eclamptic group was caused by vascular vasospasm. Vascular vasospasm narrows choroidal vascular structures, resulting in decreased choroidal blood supply and, in turn, possible choroidal thinning.

In summary, vasoconstriction and the activation of thrombosis occurring with pre-eclampsia impair choroidal microcirculation by causing endothelial cell dysfunction. As a result, increased permeability and/or impairment of the normal blood-retina barrier may occur. Changes in choroidal structure should, therefore, be remembered in the differential diagnosis of visual loss in pre-eclamptic pregnant women. Future prospective studies with more patients are required, nevertheless, to establish the chorioretinal effects of pre-eclampsia.

## REFERENCES

- Perloff D. Hypertension and pregnancy-related hypertension. *Cardiol Clin.* 1998; 6(1):79-101.
- Ober RR. Pregnancy-induced hypertension (preeclampsia-eclampsia). In: Ryan SJ, editor. *Retina.* St Louis, MO: CV Mosby; 1994. p.1393-403. Vol. 2.
- Magee LA, Helewa M, Moutquin JM, von Dadelzen P; Hypertension Guideline Committee; Strategic Training Initiative in Research in the Reproductive Health Sciences (STIRRH) Scholars. Diagnosis, evaluation, and management of the hypertensive disorders of pregnancy. *J Obstet Gynaecol Can.* 2008;30(3Suppl):S1-48.
- Sheth BP, Mielier WF. Ocular complications of pregnancy. *Curr Opin Ophthalmol.* 2001;12(6):455-63.
- Wagner HP. Arterioles of the retina in toxemia of pregnancy. *JAMA.* 1933;101:1380-4.
- Errera MH, Kohly RP, Cruz L. Pregnancy-associated retinal diseases and their management. *Surv Ophthalmol.* 2013;58:127-42.
- Spaide RF, Koizumi H, Pozzoni MC. Enhanced depth imaging spectral-domain optical coherence tomography. *Am J Ophthalmol.* 2008;146(4):496-500.
- Margolis R, Spaide RF. A pilot study of enhanced depth imaging optical coherence tomography of the choroid in normal eyes. *Am J Ophthalmol.* 2009;147(5):811-5.
- Dieti J. The pathogenesis of pre-eclampsia: new aspects. *J Perinat Med.* 2000;28(6): 464-71.
- Redman CW, Sargent IL. Pre-eclampsia, the placenta and the maternal systemic inflammatory response: a review. *Placenta.* 2003;24(Suppl A):21-7.
- Valluri S, Adelberg DA, Curtis RS, Olk RJ. Diagnostic indocyanine green angiography in preeclampsia. *Am J Ophthalmol.* 1996;122(5):672-7.
- Chaine G, Attali P, Gaudric A, Colin MC, Quentel G, Coscas G. Ocular fluorophotometric and angiographic findings in toxemia of pregnancy. *Arch Ophthalmol.* 1986; 104(11):1632-5.
- Fastenberg DM, Fetkenhour CL, Choromokos E, Schoch DE. Choroidal vascular changes in toxemia of pregnancy. *Am J Ophthalmol.* 1980;89(3):362-8.

14. Mabie WC, Ober RR. Fluorescein angiography in toxemia of pregnancy. *Br J Ophthalmol.* 1980;64(9):666-71.
15. Jaffe G, Schatz H. Ocular manifestations of preeclampsia. *Am J Ophthalmol.* 1987; 103(3 Pt 1):309-15.
16. Belfort MA, Saade GR. Retinal vasospasm associated with visual disturbance in preeclampsia: colour flow Doppler findings. *Am J Obstet Gynecol.* 1993;169(3):523-5.
17. Nickla DL, Wallman J. The multifunctional choroid. *Prog Retin Eye Res.* 2010;29(2): 144-68.
18. Maruko I, Iida T, Sugano Y, Ojima A, Sekiryu T. Subfoveal choroidal thickness in fellow eyes of patients with central serous chorioretinopathy. *Retina.* 2011;31(8):1603-8.
19. Imamura Y, Fujiwara T, Margolis R, Spaide RF. Enhanced depth imaging optical coherence tomography of the choroid in central serous chorioretinopathy. *Retina.* 2009;29(10):1469-73.
20. Manjunath V, Goren J, Fujimoto JG, Duker JS. Analysis of choroidal thickness in age-related macular degeneration using spectral-domain optical coherence tomography. *Am J Ophthalmol.* 2011;152(4):663-8.
21. Kim SW, Oh J, Kwon SS, Yoo J, Huh K. Comparison of choroidal thickness among patients with healthy eyes, early age-related maculopathy, neovascular age-related macular degeneration, central serous chorioretinopathy, and polypoidal choroidal vasculopathy. *Retina.* 2011;31(9):1904-11.
22. Harada T, Machida S, Fujiwara T, Nishida Y, Kurosaka D. Choroidal findings in idiopathic uveal effusion syndrome. *Clin Ophthalmol.* 2011;5:1599-601.
23. Maruko I, Iida T, Sugano Y, Oyama H, Sekiryu T, Fujiwara T, et al. Subfoveal choroidal thickness after treatment of Vogt-Koyanagi-Harada disease. *Retina.* 2011;31(3):510-7.
24. Esmaeelpour M, Považay B, Hermann B, Hofer B, Kajic V, Hale SL, et al. Mapping choroidal and retinal thickness variation in type 2 diabetes using three-dimensional 1060-nm optical coherence tomography. *Invest Ophthalmol Vis Sci.* 2011;52(8):5311-6.
25. Nishida Y, Fujiwara T, Imamura Y, Lima LH, Kurosaka D, Spaide RF. Choroidal thickness and visual acuity in highly myopic eyes. *Retina.* 2012;32(7):1229-36.
26. Ikuno Y, Kawauchi K, Nouchi T, Yasuno Y. Choroidal thickness in healthy Japanese subjects. *Invest Ophthalmol Vis Sci.* 2010;51(4):2173-6.
27. Takahashi J, Kado M, Mizumoto K, Igarashi S, Kojo T. Choroidal thickness in pregnant women measured by enhanced depth imaging optical coherence tomography. *Jpn J Ophthalmol.* 2013;57(5):435-9.
28. Kara N, Sayin N, Pirhan D, Vural AD, Araz-Ersan HB, Tekirdag AI, et al. Evaluation of subfoveal choroidal thickness in pregnant women using enhanced depth imaging optical coherence tomography. *Curr Eye Res.* 2014;39(6):642-7.
29. Sayin N, Kara N, Pirhan D, Vural A, Araz-Ersan HB, Tekirdag AI, et al. Subfoveal choroidal thickness in preeclampsia: comparison with normal pregnant and nonpregnant women. *Semin Ophthalmol.* 2014;29(1):11-7.
30. Garg A, Wapner RJ, Ananth CV, Dale E, Tsang SH, Lee W, et al. Choroidal and retinal thickening in severe preeclampsia. *Invest Ophthalmol Vis Sci.* 2014;55(9):5723-9.

## 23º Simpósio Internacional de Atualização em Oftalmologia da Santa Casa de São Paulo

22 a 25 de junho de 2016

Clube Hebraica  
São Paulo - SP

### Informações:

Tels.: (11) 5084-9174 / 5082-3030 / 5084-5281  
Site: [www.jdeeventos.com.br](http://www.jdeeventos.com.br)