

Retinal detachment and gyrate atrophy of the choroid and retina: case report

Descolamento de retina e atrofia girata da coroide e retina: relato de caso

RODRIGO FABRI BERBEL¹, PAULO IGOR RAUEN², RAPHAEL FRANGIOTE PALLONE², ANTÔNIO MARCELO BARBANTE CASELLA¹

ABSTRACT

To report a case of gyrate atrophy of the choroid and retina associated with retinal detachment. Hyperornithinemia confirmed the diagnosis of gyrate atrophy. Pars plana vitrectomy with silicone oil infusion was performed with good anatomical results, despite the persistence of low visual acuity. Retinal detachment is a rare complication of gyrate atrophy and can be managed with pars plana vitrectomy and silicone oil. We discuss the possible mechanisms that led to low visual acuity.

Keywords: Gyrate atrophy; Vitamin B 6/metabolism; Retinal degeneration/surgery; Retinal detachment/surgery; Vitrectomy/methods; Silicone oils/administration & dosage; Visual acuity; Case reports; Humans; Female; Adult.

RESUMO

Descrever um caso de atrofia girata da coroide e retina associado com descolamento de retina. Altos níveis de ornitina sérica confirmaram o diagnóstico de atrofia girata. Vitrectomia via pars plana com infusão de óleo de silicone foi realizada, com bom resultado anatômico, apesar da baixa acuidade visual persistente. Descolamento de retina é uma rara complicação da atrofia girata e pode ser manejada com vitrectomia via pars plana e óleo de silicone. Discutiremos os possíveis mecanismos que levaram à baixa acuidade visual.

Descritores: Atrofia girata; Vitamina B 6/metabolismo; Degeneração retiniana/cirurgia; Descolamento retiniano/cirurgia; Vitrectomia/métodos; Óleos de silicone/administração & dosagem; Acuidade visual; Relatos de casos; Humanos; Feminino; Adulto

INTRODUCTION

Gyrate atrophy (GA) of the choroid and retina is a rare autosomal recessive disorder characterized by progressive metabolic retinal and choroidal degeneration due to a deficiency of the pyridoxal phosphate-dependent mitochondrial matrix enzyme ornithine delta(δ)-aminotransferase (OAT)⁽¹⁾. Hyperornithinemia is the primary biochemical manifestation of OAT deficiency, with a 10- to 20-fold higher systemic level of ornithine in plasma, urine, spinal fluid, and aqueous humor. The cDNA and genomic locus for OAT has been isolated and assigned to chromosome 10⁽²⁾.

Areas of progressive atrophy of the choroid and retina can be observed in the mid-periphery with exposure of the sclera and reduced visual acuity, as poor as 20/200 or worse. The low visual acuity may be related to subcapsular cataract, optic atrophy, macular edema or vasculitis^(3,4). Only sporadic cases associating GA with retinal detachment (RD) have been observed in the literature⁽³⁾.

CASE REPORT

A 32-year-old Brazilian housewife complained of long-term low visual acuity with noticeable worsening in the right eye (OD) over the last 20 days. She had a history of high myopia and cataract surgery with an intraocular lens implant in the OD five years ago and presented with visual acuity of light perception (LP) in the OD and no LP in the left eye. Normal intraocular pressure was found. Confluent areas of atrophy of the retina and choroid with exposure of the sclera

were observed in the retinal mapping examination. Furthermore, a flat detachment of the inferior retina was revealed. Elevated levels of plasma ornithine were also detected (430 micromol/L).

With a diagnostic hypothesis of gyrate atrophy of the choroid and retina, the patient was submitted to a surgical treatment that consisted of retinopexy with scleral introflexion, pars plana vitrectomy, membranectomy, infusion of liquid perfluorocarbons, endolaser and silicone oil instillation. Laser photocoagulation was quite difficult to perform due to extensive areas of atrophy, which made good adherence of the retina to the choroid impossible. Currently, five months after surgery, the patient has hand motion vision in the OD with attached retina. She is currently being followed up by a nutritionist and a clinical physician for the control of plasma ornithine levels.

DISCUSSION

A GA treatment protocol has not yet been established but could involve lowering ornithine levels by nutritional means, such as restricting the intake of arginine, the precursor of ornithine⁽⁵⁻⁷⁾. Another measure taken, in an attempt to increase OAT activity, has been the use of pyridoxine. Patients who respond to the administration of vitamin B6 with a reduction in plasma ornithine levels generally have a milder clinical course. Studies using nutritional methods with long-term follow up have demonstrated a slower progression but not regression⁽⁷⁾.

In our case, normal levels of ornithine have not been achieved, and promising results related to visual acuity are still sought.

Submitted for publication: October 1, 2010

Accepted for publication: August 10, 2011

Study carried out at the Department of Ophthalmology, Universidade Estadual de Londrina - Londrina - Brazil.

¹ Physician, Ophthalmology Department, Universidade Estadual de Londrina - UEL - Londrina (PR), Brazil.

² Physician, Hospital de Olhos de Londrina, Londrina (PR), Brazil.

Funding: No specific financial support was available for this study.

Disclosure of potential conflicts of interest: R.F.Berbel, None; P.I.Rauen, None; R.F.Pallone, None; A.M.B.Casella, None.

Correspondence address: Rodrigo Fabri Berbel, Universidade Estadual de Londrina, Av. Bandeirantes, 500 - Office 110. Londrina (PR) - 86010-010 - Brazil - E-mail: rfabriberbel@gmail.com

Editorial Note: After completing the confidential analysis of the manuscript, ABO discloses, with her agreement, the name Dr. Rosane da Cruz Ferreira as a reviewer. We thank her effort and expertise in participating in this process.

The patient presented with pseudophakia with rounded, atrophic alterations in the mid-periphery with retinal detachment in both eyes. It was decided to proceed with pars plana vitrectomy and infusion of silicone oil, seeing that besides the patient's pseudophakia, the same alterations of the illness that led to atrophy of the retina and choroid would also impede laser scarring in the periphery, hindering the adherence of the retinal pigment epithelium to the choroid. Silicone oil, therefore, was left in place for a longer postoperative period to avoid new retinal detachment (Figure 1).

In the current literature worldwide, there is only one case of GACR with RD, where silicone oil was also used to maintain the application of the retina³. We discovered no reason why the patient developed

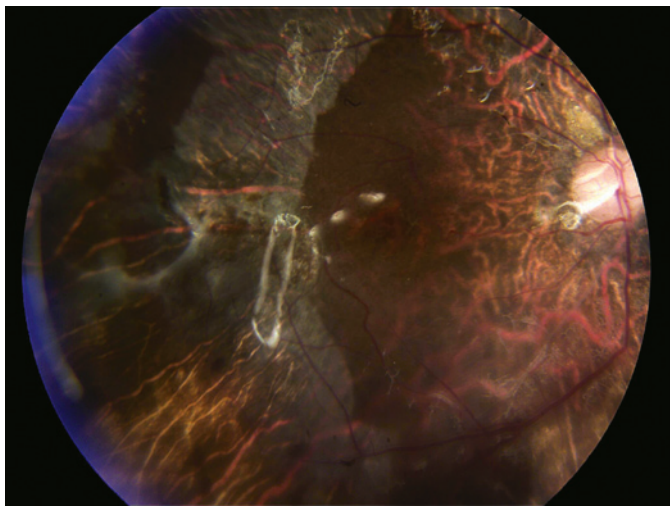


Figure 1. Retina appearance after surgery, showing retina in position, areas of retinal atrophy and the reflection of the silicone oil.

such a low visual acuity (VA), despite retinal positioning. We find it plausible, then, that the retinas of patients with this disease could have a natural outcome that often leads to very low VA, or they could be more sensitive to factors such as intraocular pressure, the height of the infusion bottle during vitrectomy surgery or contact with silicone oil. Some studies have reported silicone oil toxicity to the optic nerve⁽⁸⁾, causing atrophy as well as having a damaging effect on the retinal pigment epithelium (RPE)⁽⁹⁾ and an inflammatory action. Comparing this with a histopathologic study⁽¹⁰⁾ that demonstrated alterations at the RPE level by GA could explain, at least in part, the low VA.

REFERENCES

1. Carr RE. Hereditary choroidal disease. In: Ryan SJ, editor. Retina. St Louis; Mosby; 1989. p.447-56.
2. Ohkubo Y, Ueta A, Ito T, Sumi S, Yamada M, Ozawa K, et al. Vitamin B6-responsive ornithine aminotransferase deficiency with a novel mutation G237D. *Tohoku J Exp Med.* 2005;205(4):335-42.
3. Engelmann K, Richard G, Kohlschütter A, Bialasiewicz AA. [Rhegmatogenous retinal detachment in atrophía gyrata: pars plana vitrectomy with silicone oil instillation]. *Klin Monatsbl Augenheilkd.* 1996;209(6):373-5. German.
4. Vasconcelos-Santos DV, Magalhães EP, Nehemy MB. Macular edema associated with gyrate atrophy managed with intravitreal triamcinolone: a case report. *Arq Bras Oftalmol.* 2007;70(5):858-61.
5. Oyamaguchi EK, Lucena DR, Madur IP, Jorge R. Atrofia girata de coróide e retina: relato de caso. *Arq Bras Oftalmol.* 2003;66(4):515-8.
6. Kaiser-Kupfer MI, Caruso RC, Valle D, Reed GF. Use of an arginine-restricted diet to slow progression of visual loss in patients with gyrate atrophy. *Arch Ophthalmol.* 2004; 122(7):982-4.
7. Santinelli R, Costagliola C, Tolone C, D'Alòia A, D'Avanzo A, Prisco F, et al. Low-protein diet and progression of retinal degeneration in gyrate atrophy of the choroid and retina: a twenty-six-year follow-up. *J Inherit Metab Dis.* 2004;27(2):187-96.
8. Papp A, Kiss EB, Timár O, Szabó E, Berecki A, Tóth J, et al. Long-term exposure of the rabbit eye to silicone oil causes optic nerve atrophy. *Brain Res Bull.* 2007;74(1-3):130-3.
9. Inoue M, Iriyama A, Kadonosono K, Tamaki Y, Yanagi Y. Effects of perfluorocarbon liquids and silicone oil on human retinal pigment epithelial cells and retinal ganglion cells. *Retina.* 2009;29(5):677-81. Comment in: *Retina.* 2010;30(3):534-5; author reply 535-6.
10. Noble KG. Choroidal dystrophies. In: Guyer DR, Yannuzzi LA, Chang S, Shields JA, Green RW. Retina, vitreous, macula. Philadelphia; WB Saunders; 1999. p.960-74.