

# Ophthalmologic findings in hepatitis C patients treated with pegylated interferon $\alpha$ -2b and ribavirin

## *Achados oftalmológicos nos pacientes portadores de hepatite C em tratamento com interferon peguilado $\alpha$ -2b e ribavirina*

FERNANDO JOSÉ DE NOVELLI<sup>1</sup>, ANDRÉ PRZYSIEZNY<sup>1</sup>, EVANDRO LUIS ROSA<sup>1</sup>, RAQUEL FRANCINE LIERMANN GARCIA<sup>2</sup>, MÁRIO JUNQUEIRA NÓBREGA<sup>1</sup>

### ABSTRACT

**Purpose:** To identify the effect of pegylated interferon  $\alpha$ -2b and ribavirin treatment in the ocular fundus examination, visual acuity, and visual field.

**Methods:** Prospective observational study was performed at the Hepatology Clinic of São José Regional Hospital and at the Vitreoretinal Department at the Sadalla Amin Ghanem Eye Hospital in patients with chronic hepatitis C before and during treatment with pegylated interferon  $\alpha$ -2b together with ribavirin.

**Results:** Six (37.5%) of 16 patients developed retinopathy during the treatment, two of which (12.5%) presented retinal hemorrhage, and four patients (6 eyes) presented cotton-wool spots (25%) that regressed during the treatment. One patient (6.25%) presented transient decrease in visual acuity during the treatment and recovered spontaneously without specific therapy.

**Conclusion:** Recommended treatment methods for hepatitis C may cause transient retinopathy, commonly without any damage to visual function in most patients. Although ocular involvement is rare, follow-up with an ophthalmologist is recommended during the course of the hepatitis C medication.

**Keywords:** Antiviral agents/adverse effects; Hepatitis C, chronic/drug therapy; Interferon-alpha/adverse effects; Retinal diseases/chemically induced; Ribavirin/adverse effects

### RESUMO

**Objetivo:** Identificar possíveis mudanças no exame de fundo de olho após o início do tratamento, bem como alterações na acuidade visual e campo visual.

**Métodos:** Estudo observacional prospectivo realizado na Clínica de Hepatologia do Hospital Regional de São José e no Departamento de Vitreo e Retina do Hospital de Olhos Sadalla Amin Ghanem, em pacientes com hepatite C crônica antes e durante o tratamento com interferon peguilado  $\alpha$ -2b associado à ribavirina.

**Resultados:** Six (37,5%) dos 16 participantes desenvolveram retinopatia durante o tratamento, dois dos quais (12,5%) apresentaram hemorragia retiniana unilateral, e quatro pacientes com exsudatos algodoados (25%), seis olhos, que regrediu durante o tratamento. Um participante (6,25%) apresentou diminuição transitória da acuidade visual durante o tratamento com recuperação espontaneamente sem tratamento específico.

**Conclusão:** O tratamento recomendado para a hepatite C pode estar associado com o desenvolvimento de retinopatia transitória, geralmente sem dano à função visual na maioria dos pacientes. Embora o envolvimento ocular seja raro, o acompanhamento com o médico oftalmologista é recomendado durante todo o uso da medicação.

**Descritores:** Agentes antivirais/efeitos adversos; Hepatite C crônica/quimioterapia; Interferon-alfa/efeitos adversos; Doenças retinianas/quimicamente induzido; Ribavirina/efeitos adversos

### INTRODUCTION

The hepatitis C virus infection is a severe disease that can become chronic and progress to hepatic decompensation, cirrhosis, and in 20% of the cases to hepatocellular carcinoma<sup>(1)</sup>. Around 3% of the world's population (170 million people) is estimated to be the chronic carrier of the hepatitis C virus<sup>(2)</sup>. In Brazil, prevalence of this disease ranges from 0.9% to 1.9%, proportionate to the population of each state<sup>(3)</sup>.

The current FDA approved and recommended treatment for hepatitis C is the interferon-alpha monotherapy, which includes pegylated interferon  $\alpha$ -2b or along with ribavirin. Interferon is an immunomodulatory compound with direct antiviral and antiproliferative properties; it has been used as a therapeutic for hepatitis C, B, and D, cancer, and multiple sclerosis. In vitro, interferon alpha inhibits viral replication<sup>(4)</sup>. Ribavirin is an immunomodulatory compound that inhibits viral DNA and RNA. When used alone it has no effect on hepatitis C viral replication<sup>(5)</sup>. However, when combined with interferon, viral and biochemical response is sustained, when compared to the stand-alone use of interferon alpha<sup>(6)</sup>. The treatment duration of 24 to 48 weeks has been recommended<sup>(6)</sup>.

The use of interferon as the treatment for hepatitis C in patients might lead to systemic changes, such as myalgia, fever, erythema, weakness, loss of appetite, anemia, and thrombocytopenia<sup>(1)</sup>. Ribavirin has a fewer side effects among which hemolytic anemia being the most frequent one<sup>(7)</sup>. Studies have reported an association of these compounds with optic neuropathy<sup>(7)</sup>, retinopathy<sup>(8-14)</sup>, subconjunctival hemorrhage<sup>(8)</sup>, cystoid macular edema<sup>(15)</sup>, and retinal and choroidal perfusion deficiency<sup>(16)</sup>.

The objective of this study is to identify possible alterations in ocular fundus examination upon start of the treatment, as well as to analyze the changes in visual acuity and visual field.

### METHODS

This was a prospective observational study performed at the Hepatology Clinic of the São José Regional Hospital and at the Vitreoretinal Department at the Sadalla Amin Ghanem Eye Hospital. The study was conducted in the patients with chronic hepatitis C immediately commencing a standard 48-week treatment regimen of pegylated interferon  $\alpha$ -2b (1.5 mcg/kg/week) subcutaneous injections

Submitted for publication: May 29, 2013  
Accepted for publication: March 16, 2014

Study conducted at Hepatology Clinic of São José Regional Hospital and at the Vitreoretinal Department at the Sadalla Amin Ghanem Eye Hospital.

<sup>1</sup> Sadalla Amin Ghanem Eye Hospital.

<sup>2</sup> City Program of Viral Hepatitis Control, Joinville, SC, Brazil.

**Funding:** No specific financial support was available for this study.

**Disclosure of potential conflicts of interest:** None of the authors have any potential conflicts of interest to disclose.

**Corresponding author:** Fernando José de Novelli. Joinville - SC - 89216-222 - Brazil  
E-mail: fernando.novelli@gmail.com

and ribavirin twice daily dosage of 800 mg. The study was approved by the Ethics Board under number 196824. All patients signed the informed consent form.

All the patients were interviewed regarding systemic diseases and were evaluated with the following ophthalmologic evaluation items before starting the treatment, after one month and quarterly up to twelve months. Examination consisted of best corrected visual acuity (subjective refraction); biomicroscopy; intraocular pressure (Goldmann applanation tonometry); retinal mapping with indirect ophthalmoscope (using a 20D lens); direct and consensual pupillary light reflex test; visual field analysis with automated perimetry (Humphrey Field Analyzer II 750i, HFA 750i), with 24-2 SITA-standard strategy (Swedish Interactive Threshold Algorithm). Patients with concomitant diabetes mellitus underwent to fluorescein angiography exam (Topcon, TRC-50IX system, IMAGENet 2000, intravenous 2.5 ml of 20% sodium fluorescein solution) before starting the treatment, after one month, and once in three months for up to twelve months. The glycosylated hemoglobin dosage was monitored in the same periods.

Patients with the following characteristics were excluded: age below 18 years; diabetic retinopathy with changes in retinal perfusion at fluorescein angiography exam on initial evaluation or uncontrolled clinical diabetes upon follow-up (such as glycosylated hemoglobin-HbA1c over 8%) retinopathy; central or brain retinal vein occlusion; systemic arterial hypertension with retinopathy upon initial evaluation, or uncontrolled clinical systemic arterial hypertension upon follow-up during the existence of retinopathy; other type of retinal vasculopathy arising due to non-infectious (Behçet's disease, Wegener granulomatosis, systemic lupus erythematosus, polyarthritis nodosa, Crohn's disease, sarcoidosis, multiple sclerosis), infectious (syphilis, Lyme's disease, toxoplasmosis, toxocarasis, tuberculosis, herpes, mononucleosis, leptospirosis), and ocular concomitant diseases (Birdshot chorioretinopathy, pars planitis, Eales disease, IRVAN syndrome, multifocal choroiditis).

## RESULTS

Nineteen patients, 7 females and 12 males of 21 to 65 years of age were enrolled in the study (mean, 46 years). The duration of follow-up varied from 4 to 48 weeks. Three patients missed the follow up after first examination and were excluded. Out of sixteen patients two were followed up to one month (12.5%), three patients for 3 to 6 months (18.75%), three patients for 6 to 9 months (18.75%), and eight from 9 to 12 months (50%). One patient was followed for 24 months. Average follow-up time was 8.18 months.

Retinopathy developed in six patients (37.5%) and among these two patients (12.5%) showed unilateral retinal hemorrhage presenting with a small and isolated hemorrhage; cotton-wool spots characterized by small, isolated whitish spots, not associated with changes in visual function (Figure 1) were observed in four patients (25%) or six eyes (18.75%).

Out of 16 patients, a group of patients were diagnosed with the following systemic diseases: HIV, 1 (6.25%); diabetes, 3 (18.75%); 3 patients had known treated hypertension (18.75%); and liver failure, 1 (6.25%). After the beginning of treatment, 66.6% of the patients developed diabetic retinopathy and the same occurred with hypertensive patients. Of the total of detected retinopathy, hypertension accounted for 33.3%. The same was true for patients with diabetes.

These patients were instructed to continue systemic treatment with an ophthalmologic evaluation every two months and return if any ophthalmologic signal was detected. All patients adequately completed the treatment without any interruption due to the severity of ophthalmic associated findings.

Upon completion of the treatment and terminating the medication the patients showed no signs of retinopathy or visual damage (Figure 2).

One of the patient, patient number 6 presented bilateral decrease of visual acuity during the treatment (6.25% of patients), associated with cotton wool spots on the right eye. However, this condition

was not connected with that pegylated interferon  $\alpha$ -2b and ribavirin treatment as the condition persisted even in absence of the medication. The patient recovered after one year of interruption of the treatment (Table 1). In the initial tests, patient also showed bilateral nonspecific disturbances on peripheral visual field at 30-2 strategy, without disc edema and not compatible with retinal manifestation on the right eye.

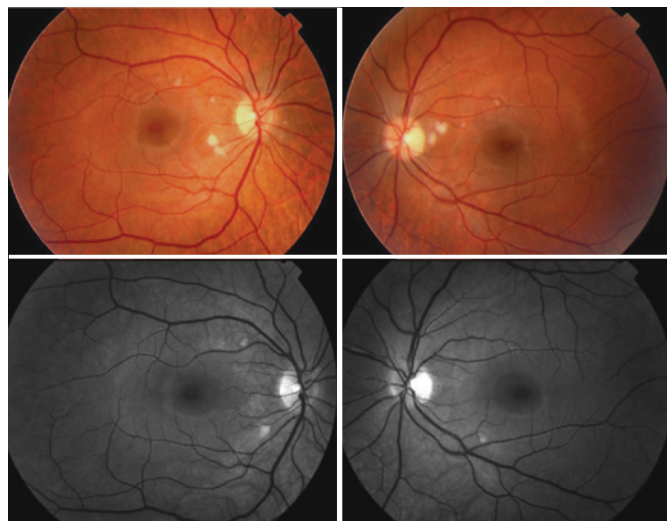
No color vision damage was found in any patient throughout the systemic treatment.

## DISCUSSION

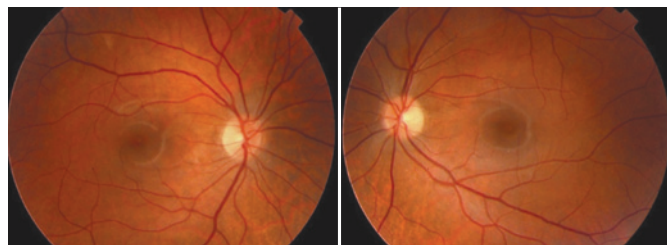
Physiopathology of retinopathy has not been clearly understood. Guyer et al.<sup>(11)</sup> suggested that immune-complex deposition and leucocyte infiltration in the retinal vasculature would lead to ischemic episodes. Earlier studies<sup>(17,18)</sup> have shown that the increase in plasma complement levels and plasma aggregation would facilitate capillary infarction, thus explaining the ischemic alterations of retinopathy.

Although treatment with pegylated interferon  $\alpha$ -2b associated with ribavirin might lead to ocular side effects, the associated use seems to bring a few side effects<sup>(19)</sup>. Irritability and eye discomfort are most commonly reported due to the drug-induced conjunctivitis as the drug is secreted along with tear<sup>(20)</sup>.

The incidence of retinopathy related to pegylated interferon  $\alpha$ -2b has been widely reported in the literature. In a systematic review from Raza et al.<sup>(21)</sup>, the overall incidence of retinopathy during the treatment was around 27%. In a prospective study Vujosevic et al.<sup>(22)</sup> reported 30% of retinopathy in 97 patients. In another prospective



**Figure 1.** Color (upper) and red-free retinograph (below) of both eyes of patient 1 at 6-month follow-up treatment for hepatitis C, presenting with multiple cotton-wool spots without associated hemorrhage, smaller in the superior papillomacular bundle area and bigger in the inferior one.



**Figure 2.** Color retinography of both eyes of patient 1 showing no retinal lesions at one year follow-up.

**Table 1. Profile of patients that underwent follow-up during the treatment for hepatitis C**

Age (years)	Associated disease	Ocular changes	Time of detection of ocular changes	BCVA* before treatment		BCVA* last query		
				Right	Left	Right	Left	
1	21	-	Bilateral cotton wool spots	month 6	1.0	1.0	1.0	1.0
2	62	Hypertension	Bilateral cotton wool spots	month 3	1.0	1.0	1.0	1.0
3	42	-	-	-	1.0	1.0	1.0	1.0
4	47	Diabetes	Retinal hemorrhage in OS	week 3	1.0	1.0	1.0	1.0
5	47	-	-	-	1.0	1.0	1.0	1.0
6	58	-	Cotton wool spots in OD	month 5	1.0	1.0	1.0	1.0
7	44	Diabetes and hypertension	Retinal hemorrhage in OS	month 6	1.0	0.5	1.0	0.5
8	33	-	-	-	1.0	1.0	1.0	1.0
9	46	-	-	-	1.0	1.0	1.0	1.0
10	51	Diabetes and hypertension	-	-	0.9	0.9	1.0	0.9
11	40	-	-	-	1.0	1.0	1.0	1.0
12	44	HIV**	-	-	1.0	1.0	1.0	1.0
13	36	-	-	-	1.0	1.0	1.0	1.0
14	54	-	-	-	1.0	1.0	1.0	1.0
15	42	-	Left eye cotton wool spots	month 7	1.0	1.0	1.0	1.0
16	44	Liver failure	-	-	1.0	1.0	1.0	1.0

\*BCVA= best corrected visual acuity; \*\*HIV= human immunodeficiency virus.

study, Kim et al.<sup>(23)</sup> evaluated 32 patients (64 eyes) and 11 of them developed retinopathy (34.4%). Cotton-wool spots were found in six patients, both eyes (18.7%); retinal hemorrhages in four (12.5%), both eyes. Panetta et al.<sup>(24)</sup> reported in a retrospective study a very low incidence (3.8%) of retinopathy among 183 patients with chronic hepatitis C treated with pegylated interferon  $\alpha$ -2b and ribavirin. However, only symptomatic patients were included in this study.

It is likely that the incidence of retinopathy could be under represented. The cotton-wool spots were transient, often asymptomatic with no visual acuity, so it is possible that they were not always detected, especially when the patients missed or were irregular with the follow-up. Most patients showed full resolution without visual sequelae.

Schulman et al.<sup>(25)</sup> showed among 42 patients (7%) treated with interferon and ribavirin, three patients had to be stopped the treatment due to retinopathy (two) and disc edema (one) with low visual acuity. The patients regressed spontaneously after stopping the treatment, without sequelae.

Nagaoka et al.<sup>(26)</sup> suggested endothelial dysfunction as a cause of interferon-associated retinopathy, with increased manifestation within 2 weeks of treatment initiation. Schulman et al.<sup>(25)</sup> reported a 67% chance of development of retinopathy among hypertensive patients. Similar to the findings of Vujosevic et al.<sup>(22)</sup> that reported a frequency of 68% Kim et al.<sup>(23)</sup> also claimed hypertension to be a risk factor for retinopathy.

## CONCLUSION

In our study, we diagnosed retinopathy in a considerable number of cases, but most patients showed no changes in visual acuity and quality. Only one patient showed a transient visual loss without loss of term impairing of the visual function. We conclude that according to our study and in agreement with studies published in literature, the treatment for hepatitis C with pegylated interferon  $\alpha$ -2b associated with ribavirin although can cause retinal changes, usually do not lead to damages to visual function, and has a transitional character with complete anatomical and functional recovery. Although ocular involvement is rare, follow-up with an ophthalmologist is recommended throughout the course of the medication, especially if symptoms are detected.

## REFERENCES

- Alexander G, Walsh K. Chronic viral hepatitis. *Int J of Clin Pract.* 2000;54(7):450-6.
- World Health Organization. Hepatitis C: Fact Sheet No 164. [Internet]. Geneva: World Health Organization; 2011. [cited 2014 May 21]. Available from: [HTTP://WWW.who.int/mediacentre/factsheets/fs164/em/index.html](http://www.who.int/mediacentre/factsheets/fs164/em/index.html)
- Szabo SM, Bibby M, Yuan Y, Donato BM, Jiménez-Mendez R, Castañeda-Hernández G, Rodríguez-Torres M, Levy AR. The epidemiologic burden of hepatitis C virus infection in Latin America. *Ann Hepatol.* 2012;11(5):623-35.
- Blight KJ, Kolykhalov AA, Rice CM. Efficient initiation of HCV RNA replication in cell culture. *Science.* 2000;290(5498):1972-4.
- Cheney CP, Chopra S, Graham C. Hepatitis C. *Infect Dis Clin North Am.* 2000;14(3):633-67.
- Pianko S, McHutchison JG. Treatment of hepatitis C with interferon and ribavirin. *J Gastroenterol Hepatol.* 2000;15(6):581-6.
- Purvin VA. Anterior ischemic optic neuropathy secondary to interferon alfa. *Arch Ophthalmol.* 1995;113(8):1041-4.
- Hayasaka S, Fujii M, Yamamoto Y, et al. Retinopathy and subconjunctival haemorrhage in patients with chronic viral hepatitis receiving interferon alfa. *Br J Ophthalmol.* 1995;79(2):150-2.
- Kadayifilar S, Boyacioglu S, Kart H, et al. Ocular complications with high-dose interferon alpha in chronic active hepatitis. *Eye (Lond).* 1999;13(Pt 2):241-6.
- Hayasaka S, Nagaki Y, Matsumoto M, Sato S. Interferon associated retinopathy. *Br J Ophthalmol.* 1998;82(3):323-5.
- Guyer DR, Tiedeman J, Yannuzzi LA, et al. Interferon-associated retinopathy. *Arch Ophthalmol.* 1993;111(3):350-6.
- Esmaeli B, Koller C, Papadopoulos N, Romaguera J. Interferon-induced retinopathy in asymptomatic cancer patients. *Ophthalmology.* 2001;108(5):858-60.
- Hejny C, Sternberg P Jr, Lawson DH, et al. Retinopathy associated with high-dose interferon alfa-2b therapy. *Am J Ophthalmol.* 2001;131(6):782-7.
- Jain K, Lam WC, Waheeb S, et al. Retinopathy in chronic hepatitis C patients during interferon treatment with ribavirin. *Br J Ophthalmol.* 2001;85(10):1171-3.
- Tokai R, Ikeda T, Miyaura T, Sato K. Interferon-associated retinopathy and cystoid macular edema. *Arch Ophthalmol.* 2001;119(7):1077-9.
- Hoerauf H, Schmidt-Erfurth U, Asiyovogel M, Laqua H. Combined choroidal and retinal ischemia during interferon therapy: indocyanine green angiographic and microperimetric findings. *Arch Ophthalmol.* 2000;118(4):580-2.
- Sugano S, Suzuki T, Watanabe M. Retinal complications and plasma C5a levels during interferon alpha therapy for chronic hepatitis C. *Am J Gastroenterol.* 1998;93(12):2441-4.
- Sugano S, Yanagimoto M, Suzuki T. Retinal complications with elevated circulating plasma C5a associated with interferon-alpha therapy for chronic active hepatitis C. *Am J Gastroenterol.* 1994;89(11):2054-6.
- Schalm SW, Hansen BE, Chemello L, et al. Ribavirin enhances the efficacy but not the adverse effects of interferon in chronic hepatitis C. Meta-analysis of individual patient data from European centers. *J Hepatol.* 1997;26(5):961-6.
- Fraunfelder FT, Fraunfelder FW, Chambers WA. *Clinical ocular toxicology.* Philadelphia, PA: Saunders. 2008;212-4.
- Raza A, Mittal S, Sood GK. Interferon-Associated Retinopathy During the Treatment of Chronic Hepatitis C. *J Viral Hepat.* 2013;20(9):593-9.

22. Vujosevic S, Tempesta D, Noventa F, Midená E, Sebastiani G. Pegylated interferon-associated retinopathy is frequent in hepatitis C virus patients with hypertension and justifies ophthalmologic screening. *Hepatology*. 2012;56(2):455-63.
23. Kim ET, Kim LH, Lee JI, Chin HS. Retinopathy in hepatitis C patients due to combination therapy with pegylated interferon and ribavirin. *Jpn J Ophthalmol*. 2009;53(6):598-602.
24. Panetta JD, Gilani N. Interferon-induced retinopathy and its risk in patients with diabetes and hypertension undergoing treatment for chronic hepatitis C virus infection. *Aliment Pharmacol Ther*. 2009;30(6):597-602.
25. Schulman JA, Liang C, Kooragayala LM, King J. Posterior segment complication in patients with Hepatitis C treated with interferon and ribavirin. *Ophthalmology*. 2003;110(2):437-42.
26. Nagaoka T, Sato E, Takahashi A, Yokohama S, Yoshida A. Retinal circulatory changes associated with interferon-induced retinopathy in patients with hepatitis C. *Invest Ophthalmol Vis Sci*. 2007;48(1):368-75.

## **17º Congresso de Oftalmologia USP**

### **16º Congresso de Auxiliar de Oftalmologia USP**

**28 e 29 de novembro de 2014**

**Centro de Convenções Rebouças**

São Paulo - SP

#### **Informações:**

Tels.: (11) 5084-9174 / 5082-3030

E-mail: [secretariausp@jdeeventos.com.br](mailto:secretariausp@jdeeventos.com.br)

Site: [www.ofthalmologiausp.com.br](http://www.ofthalmologiausp.com.br)