

Effects of hemodialysis on corneal and anterior chamber morphometry and intraocular pressure in patients with end-stage renal disease

Efeitos da hemodiálise na morfometria da córnea e da câmara anterior, e na pressão intraocular em pacientes no estágio final da doença renal

MEHTAP CAGLAYAN¹, PINAR KOSEKAHYA², TAMER TAKMAZ¹, ALPASLAN ALTUNOGLU³, BERNA AYAN¹, CEMILE UCGUL ATILGAN², BETUL SEHER UYSAL¹

ABSTRACT

Purpose: To evaluate the effects of hemodialysis (HD) on corneal and anterior chamber morphometry, as well as intraocular pressure (IOP) in patients with end-stage renal disease.

Methods: Fifty right eyes were examined 30 minutes before and after HD. IOP was measured with a Goldmann applanation tonometer, and Ehlers' formula was used to calculate the corrected IOP values. The central corneal thickness (CCT), corneal volume (CV), keratometric values, anterior chamber depth (ACD), aqueous depth (AQD), anterior chamber volume (ACV), and anterior chamber angle (ACA) in the nasal and temporal quadrants were measured with a Sirius anterior segment analysis system. Blood urea nitrogen levels, body mass, and systolic and diastolic arterial pressure were also measured before and after HD.

Results: The mean age was 60.80 ± 13.38 (range: 35-80) years. The mean uncorrected and corrected IOP values decreased from 18.06 ± 3.91 and 18.31 ± 4.83 mmHg to 16.94 ± 3.87 and 16.95 ± 4.74 mmHg after HD, respectively ($p=0.011$ and $p=0.003$, respectively). The mean CCT decreased from 536.38 ± 24.73 to 533.18 ± 27.25 μm ($p=0.002$), and the mean CV decreased from 57.52 ± 3.15 to 55.68 ± 3.55 mm^3 ($p<0.001$) after HD. There were no significant changes in ACD, AQD, ACV, ACA, or the keratometric values ($p>0.05$ for all values). There were no significant correlations between the ocular and systemic parameters ($p>0.05$ for all correlations).

Conclusions: Uncorrected IOP, corrected IOP, CCT, and CV values decreased after HD, whereas the anterior chamber morphometry values remained similar between the measurements performed before and after HD.

Keywords: Renal dialysis; Cornea; Anterior chamber; Intraocular pressure; Kidney failure, chronic; Vision disorders

RESUMO

Objetivo: Avaliar os efeitos da hemodiálise (HD) na morfometria da córnea e da câmara anterior e da pressão intraocular (PIO) em pacientes com doença renal terminal.

Métodos: Cinquenta olhos direitos foram examinados 30 minutos antes e após hemodiálise. A pressão intraocular foi medida com um tonômetro de aplanção de Goldmann, e a fórmula de Ehlers foi utilizada para calcular os valores de pressão intraocular corrigidos. Mediram-se a espessura corneana central (CCT), o volume corneano (CV), os valores ceratométricos, a profundidade da câmara anterior (ACD), a profundidade aquosa (AQD), o volume da câmara anterior (ACV) e o ângulo da câmara anterior (ACA) nos quadrantes nasais e temporais com um sistema de análise de segmento Sirius anterior. Os níveis de nitrogênio ureico no sangue (BUN), peso corporal e pressão arterial sistólica e diastólica também foram medidos antes e após a HD.

Resultados: A média de idade foi de $60,80 \pm 13,38$ (35-80) anos. Os valores médios não corrigidos e corrigidos da pressão intraocular diminuíram de $18,06 \pm 3,91$ e $18,31 \pm 4,83$ mmHg para $16,94 \pm 3,87$ e $16,95 \pm 4,74$ mmHg após hemodiálise ($p=0,011$ e $p=0,003$, respectivamente). A espessura corneana central média diminuiu de $536,38 \pm 24,73$ para $533,18 \pm 27,25$ μm ($p=0,002$), e o volume corneano médio diminuiu de $57,52 \pm 3,15$ para $55,68 \pm 3,55$ mm^3 ($p<0,001$) após hemodiálise. Não houve alteração significativa nos valores de profundidade da câmara anterior, profundidade aquosa, volume da câmara anterior, ângulo da câmara anterior e ceratométricos ($p>0,05$ para todos os valores). Não houve correlação significativa entre os parâmetros oculares e sistêmicos ($p>0,05$ para todas as correlações).

Conclusão: A pressão intraocular não corrigida, a pressão intraocular corrigida, a espessura corneana central e os valores de volume corneano diminuíram após hemodiálise, enquanto os valores de morfometria da câmara anterior foram semelhantes entre as medidas realizadas antes e após a hemodiálise.

Descritores: Diálise renal; Córnea; Câmara anterior; Pressão intraocular; Falência renal crônica; Transtornos da visão

INTRODUCTION

Hemodialysis (HD) is the main treatment for end-stage renal disease (ESRD). However, acute and chronic complications can occur after HD, the most common of which are hypovolemia and sudden changes in hemodynamic parameters, which may cause organ dysfunctions⁽¹⁾. Fluid dynamic changes after HD can also affect ocular tissues that receive a high volume of blood flow. There are many ocular disorders associated with HD, including refractive changes, dry

eye, corneal and conjunctival epithelial erosions, perilimbal calcium deposits, band keratopathy, intraocular pressure (IOP) fluctuations, posterior subcapsular cataract, ischemic optic neuropathy, choroidal perfusion delay, corneal endothelium alterations, and thickness changes in the central cornea, retinal nerve fiber layer, and choroid⁽²⁻¹⁵⁾.

Among the various studies investigating the relationships between ocular alterations and HD, IOP is the most commonly investigated parameter, and conflicting results have been reported⁽¹⁶⁾. This

Submitted for publication: August 23, 2016
Accepted for publication: January 16, 2017

¹ Department of Ophthalmology, Ataturk Research and Training Hospital, Ankara, Turkey.
² Ulucanlar Eye Research and Training Hospital, Ankara, Turkey.
³ Department of Nephrology, Ataturk Research and Training Hospital, Ankara, Turkey.

Funding: No specific financial support was available for this study.

Disclosure of potential conflicts of interest: None of the authors have any potential conflict of interest to disclose.

Corresponding author: Mehtap Caglayan. Department of Ophthalmology, Ataturk Research and Training Hospital - Ankara, Turkey - E-mail: drmehtap85@hotmail.com

Approved by the following research ethics committee: Yildirim Beyazıt University Ethics Committee (# 26379996-89).

conflicting data has been explained as being due to different sample sizes, HD type and duration, fluid dynamic changes, arterial blood pressure changes, IOP measurement times, and IOP measurement techniques^(5,16). Although the Goldmann applanation tonometer is the gold standard in the measurement of IOP, it can be affected by central corneal thickness (CCT)⁽¹⁷⁾. Jung et al.⁽⁵⁾ reported that IOP and CCT both tend to decrease after HD, and they also suggested that the decrease in IOP is caused by the decrease in CCT.

Apart from IOP, important ocular problems for HD patients include changes in ocular perfusion and the iridocorneal angle. Several epidemiological studies have revealed a strong correlation between glaucoma damage and low diastolic arterial pressure, which results in increased inadequate ocular perfusion pressure (OPP)^(18,19). HD can change vascular resistance because of the rheological properties of the arteries, so this can change arterial pressure. Hu et al.⁽²⁰⁾ evaluated IOP and OPP during HD, and they reported increased IOP and decreased OPP during HD. However, Barbosa et al.⁽²¹⁾ did not find significant changes in IOP or OPP during HD. They emphasized that some patients exhibit lower diastolic perfusion pressures, which could be a poor prognostic factor for patients with glaucoma. Moreover, in eyes with glaucoma, impaired aqueous outflow, or those that are predisposed to narrow angles, the possibility of acute IOP rise during HD could be much more frequent and/or higher than in normal subjects^(22,23). Anterior chamber depth (ACD) and axial length alterations after HD have also been reported; however, ACD was defined as the diameter between the corneal epithelium and the lens as measured by contact methods in these studies^(24,25). Since CCT decreases after HD, it may be more reliable to evaluate the before and after HD values of ACD and IOP by eradicating CCT.

The Sirius anterior segment analysis system (Costruzione Strumenti Oftalmici, Florence, Italy) is a non-contact anterior segment tomography device. It provides anterior and posterior corneal topography, wavefront analysis, complete corneal pachymetry, and anterior chamber morphometry. Additionally, the device can correct IOP values using various formulas, such as Ehlers' formula, which eradicates the effect of CCT on IOP.

The aim of this study was to evaluate the short-term effects of HD on corneal and anterior chamber morphometry and IOP with the Sirius 3D Rotating Scheimpflug Camera topography system and the Goldmann applanation tonometer. In addition, we investigated the relationships between changes in ocular and systemic parameters.

METHODS

DESIGN AND STUDY POPULATION

This cross-sectional study was conducted in compliance with institutional and government review board regulations, informed consent regulations, and the Declaration of Helsinki. Written informed consent approved by the Yildirim Beyazit University Ethics Committee was obtained from all patients.

Fifty patients receiving HD treatment at the Ataturk Research and Training Hospital participated in this study. HD patients were randomly chosen from patients that had received dialysis therapy with bicarbonate dialysate for at least 3 months, three times a week, for 3-5 hours per session. All patients had arteriovenous fistulae and used a polysulfone hollow-fiber dialyzer (F8; Fresenius, Bad Homburg vor der Höhe, Germany). Only results from the right eyes of the patients were included in this study. All patients underwent visual acuity measurements with a Snellen chart, slit-lamp biomicroscopic examination, undilated funduscopy, and IOP measurement with a Goldmann applanation tonometer.

The exclusion criteria were corneal pathologies, iridotomy, pseudoexfoliative material, cataracts resulting in media opacity and preventing undilated funduscopy, IOP readings >22 mmHg, patients with glaucoma who had asymmetrically cupped optic discs with any neuroretinal rim abnormality such as peripapillary hemorrhage,

notch, or focal thinning, prior ocular surgery, topical medication use 6 months prior to the study, ocular trauma, ocular inflammatory disease, or inability to cooperate with the study protocol.

EXAMINATION PROTOCOL AND MEASUREMENTS

Before and 30 minutes after HD, all patients underwent a detailed ophthalmologic examination, which involved measuring the best-corrected visual acuity, slit-lamp biomicroscopy, and funduscopy. Corneal and anterior chamber measurements were obtained using a Scheimpflug camera with a Placido disk topographer (Sirius; Costruzione Strumenti Oftalmici). CCT, corneal volume (CV), and the flattest, steepest, and maximum keratometric values were noted as the corneal morphometry parameters, and ACD, aqueous depth (AQD), anterior chamber volume (ACV), and anterior chamber angle (ACA) in the nasal and temporal quadrants were noted as the anterior chamber morphometry parameters. IOP was measured with a Goldmann applanation tonometer, and corrected IOP was calculated with Ehlers' formula, an automatic step performed by the Sirius device. Ehlers' formula [Corrected IOP=Uncorrected IOP-(CCT-520) × (5/70)] corrects IOP using CCT. The blood urea nitrogen (BUN) levels, body mass, and systolic and diastolic arterial pressure values were also measured and recorded immediately before and after HD.

DATA ANALYSES

Statistical analysis was performed with SPSS (version 18.0 for Windows; SPSS, Inc., Chicago, IL, USA). The normality of the data was analyzed with the Kolmogorov-Smirnov test. Descriptive statistics were presented as the mean ± standard deviation. Changes in the parameters measured before and after HD were evaluated with paired samples *t*-tests for normally distributed data and the Wilcoxon signed-rank test for non-normally distributed data. The mean change was calculated for all values, and correlation analysis was performed by Pearson correlation analysis for normally distributed data and Spearman's correlation analysis for non-normally distributed data. In this study, *p*<0.05 was considered statistically significant, and *p*<0.004 was considered significant for correlation tests after Bonferroni correction.

RESULTS

DEMOGRAPHIC CHARACTERISTICS OF THE STUDY GROUP

There were 18 (36%) female and 32 (64%) male patients, with a mean age of 60.80 ± 13.38 (range: 35-80) years. The predominant ESRD etiologies in the patients were diabetes mellitus (26/50, 52%), hypertension (16/50, 32%), and glomerulonephritis (8/50, 16%). The mean duration of HD treatment was 3.6 ± 2.7 (1-13) years.

EFFECTS OF HD ON SYSTEMIC PARAMETERS

The mean changes in the BUN levels, body mass, and systolic and diastolic pressure after HD were -95.12 ± 34.98 mg/dl, -2.63 ± 0.66 kg, -19.60 ± 9.24 mmHg, and -10.40 ± 12.28 mmHg, respectively. All of these parameters decreased significantly after HD (*p*<0.001) (Table 1).

EFFECTS OF HD ON IOP

The mean uncorrected and corrected IOP values decreased from 18.06 ± 3.91 and 18.31 ± 4.83 to 16.94 ± 3.87 and 16.95 ± 4.74 mmHg after HD, respectively. This decline was statistically significant, with a mean reduction of -1.12 ± 3.00 mmHg for the uncorrected IOP and -1.38 ± 3.02 mmHg for the corrected IOP (*p*=0.011 and *p*=0.003, respectively) (Table 2) (Figure 1).

EFFECTS OF HD ON CORNEAL AND ANTERIOR CHAMBER MORPHOMETRY

The mean changes in CCT and CV were -3.26 ± 7.03 μm and -0.90 ± 1.23 mm³, respectively (*p*=0.002 and *p*<0.001, respectively) (Table 2).

Table 1. Mean blood urea nitrogen, body mass, and systolic and diastolic pressure immediately before and after hemodialysis in 50 patients with end-stage renal disease

	Before HD	After HD	Δ^*	P value [†]
BUN (mg/dl)	139.54 ± 40.27	44.42 ± 15.46	-95.12 ± 34.98	<0.001
Mean ± SD				
Body mass (kg)	66.91 ± 10.09	64.27 ± 10.11	-2.63 ± 0.66	<0.001
Mean ± SD				
Systolic pressure (mmHg)	136.00 ± 20.60	117.20 ± 15.78	-19.60 ± 9.24	<0.001
Mean ± SD				
Diastolic pressure (mmHg)	78.00 ± 10.30	67.20 ± 12.62	-10.40 ± 12.28	<0.001
Mean ± SD				

HD= hemodialysis; BUN= blood urea nitrogen; SD= standard deviation; Bold face= significant values, $p < 0.05$.

*= change in value after HD; [†]= paired samples t-test.

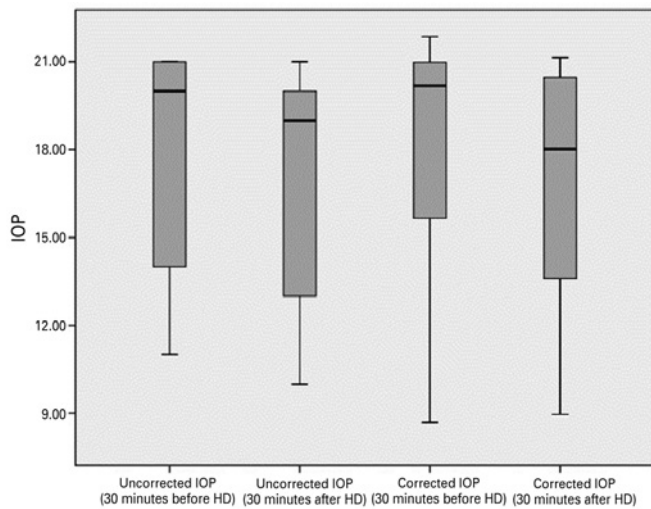


Figure 1. Boxplot of the uncorrected and corrected intraocular pressure values 30 minutes before and 30 minutes after hemodialysis.

The flattest, steepest, and maximum keratometric values were similar before and after HD ($p=0.313$, $p=0.829$, and $p=0.119$, respectively) (Table 2). The mean values of the anterior chamber parameters before and after HD are summarized in table 2. As shown in the table, ACD, AQD, ACV, and ACA in the nasal and temporal quadrants were similar before and after HD ($p > 0.05$ for all variables).

CORRELATIONS BETWEEN THE CHANGES IN OCULAR AND SYSTEMIC PARAMETERS

The changes in the uncorrected and corrected IOP and corneal and anterior chamber morphometry values were not significantly correlated with the changes in the systemic hemodynamic parameters ($p > 0.004$) (Table 3).

DISCUSSION

In this study, we investigated the short-term effects of HD on corneal and anterior chamber morphometry and IOP, as well as the relationships between changes in ocular and systemic parameters in patients with ESRD. Uncorrected and corrected IOP, CCT, and CV values significantly decreased after HD, whereas anterior chamber

Table 2. Intraocular pressure and corneal and anterior chamber parameters 30 minutes before and 30 minutes after hemodialysis in 50 patients with end-stage renal disease

	Before HD	After HD	Δ^*	P value
Uncorrected IOP (mmHg)	18.06 ± 3.91	16.94 ± 3.87	-1.12 ± 3.00	0.011[†]
Mean ± SD				
Corrected IOP (mmHg)	18.31 ± 4.83	16.95 ± 4.74	-1.38 ± 3.02	0.003[†]
Mean ± SD				
CCT (μm)	536.38 ± 24.73	533.18 ± 27.25	-3.26 ± 7.03	0.002^{††}
Mean ± SD				
CV (mm ³)	57.52 ± 3.15	55.68 ± 3.55	-0.90 ± 1.23	<0.001^{††}
Mean ± SD				
Flattest K (D)	43.93 ± 1.45	43.88 ± 1.50	-0.04 ± 0.30	0.313 ^{††}
Mean ± SD				
Steepest K (D)	44.65 ± 1.46	44.65 ± 1.50	0.06 ± 0.42	0.829 ^{††}
Mean ± SD				
Maximum K (D)	46.76 ± 1.77	46.41 ± 1.75	-0.37 ± 1.22	0.119 ^{††}
Mean ± SD				
AQD (mm)	2.87 ± 0.46	2.91 ± 0.46	0.03 ± 0.22	0.250 ^{††}
Mean ± SD				
ACD (mm)	3.41 ± 0.46	3.44 ± 0.48	0.03 ± 0.13	0.288 ^{††}
Mean ± SD				
ACA (°) (nasal quadrant)	45.90 ± 9.42	46.18 ± 9.02	1.06 ± 2.66	0.655 [†]
Mean ± SD				
ACA (°) (temporal quadrant)	46.38 ± 12.42	45.88 ± 13.91	0.76 ± 8.05	0.571 ^{††}
Mean ± SD				

HD= hemodialysis; IOP= Intraocular pressure; CCT= central corneal thickness; CV= corneal volume; D= diopter; K= keratometry; AQD= aqueous depth; ACD= anterior chamber depth; ACV= anterior chamber volume; ACA= anterior chamber angle; SD= standard deviation; Bold face= significant values, $p < 0.05$.

*= change in value after HD; [†]= Wilcoxon signed-rank test; ^{††}= paired samples t-test.

morphometry values did not significantly change. No significant correlations were found between the changes in the ocular and systemic parameters.

Many conflicting results concerning the effects of HD on IOP values have been reported. In a review published in 2005, studies in this field were discussed in three main groups: those showing an increase, those showing a decrease, and those showing no significant

Table 3. Correlation analyses between changes in intraocular pressure, cornea and anterior chamber parameters, and systemic parameters in 50 patients with end-stage renal disease after hemodialysis

	BUN r/p	Body mass r/p	Systolic pressure r/p	Diastolic pressure r/p
Uncorrected IOP (mmHg)	0.030/0.834*	0.234/0.102*	0.119/0.409*	-0.101/0.485*
Corrected IOP (mmHg)	0.056/0.702*	0.222/0.121*	0.031/0.829*	-0.099/0.494*
CCT (µm)	-0.177/0.218 [†]	0.309/0.029 [†]	0.114/0.429 [†]	0.081/0.574 [†]
CV (mm ³)	0.002/0.987*	-0.115/0.457*	0.224/0.144*	0.240/0.116*
Flattest K (D)	-0.039/0.825*	-0.150/0.396*	0.218/0.215*	0.082/0.644*
Steepest K (D)	-0.127/0.473*	0.088/0.619*	0.077/0.664*	0.035/0.844*
Maximum K (D)	0.097/0.585*	-0.252/0.150*	-0.215/0.222*	-0.066/0.711*
AQD (mm)	0.085/0.556*	0.111/0.444*	-0.095/0.513*	0.011/0.937*
ACD (mm)	0.081/0.578*	0.102/0.481*	-0.092/0.526*	0.014/0.921*
ACV (mm ³)	-0.063/0.664*	0.188/0.199*	0.035/0.809*	0.028/0.848*
ACA (°) (nasal quadrant)	0.167/0.247 [†]	0.046/0.750 [†]	-0.125/0.386 [†]	0.076/0.601 [†]
ACA (°) (temporal quadrant)	-0.107/0.459*	-0.139/0.325*	-0.053/0.712*	-0.160/0.267*

BUN= blood urea nitrogen; IOP= intraocular pressure; CCT= central corneal thickness; CV= corneal volume; D= diopter; K= Keratometry; AQD= aqueous depth; ACD= anterior chamber depth; ACV= anterior chamber volume; ACA= anterior chamber angle; Bold face= significant values, $p < 0.004$; r= correlation coefficient.

*= Pearson correlation test; [†]= Spearman's correlation test.

change in IOP⁽¹⁶⁾. Recent studies have noted that IOP values either do not change or decrease after HD, and these studies explained these results as being due to improved HD techniques^(5,8,25,26). A few studies reported significant decreases in IOP and CCT values, and suggested that total body fluid loss and increased plasma colloid osmotic pressure after HD cause an efflux of water from the eye to the plasma, resulting in a decrease in the CCT and IOP values^(5,8). Jung et al.⁽⁵⁾ reported a correlation between the changes in IOP and those of body mass, whereas Dinc et al.⁽⁸⁾ did not find this correlation. In the present study, the mean uncorrected IOP decreased significantly after HD, with a mean reduction of -1.12 ± 3.00 mmHg. Similar to Dinc et al.'s study, no correlations were found between IOP changes and systemic changes. Two of the studies reported a positive correlation between the change in CCT and total body fluid loss^(5,8). In the present study, CCT and CV decreased significantly after HD, but these changes were not correlated with any systemic changes including body fluid loss. In terms of the relationship between IOP and CCT, Jung et al.⁽⁵⁾ found a positive correlation between IOP and CCT changes, whereas Dinc et al.⁽⁸⁾ did not find such a relationship. In the present study, we did not evaluate the correlation between IOP and CCT; however, we investigated the effect of CCT on IOP using Ehlers' formula, and corrected the IOP values according to CCT. The corrected IOP values also decreased after HD, meaning the IOP values decreased separately from the corneal thickness. However, the data did not reveal any factors that were related to the decrease in IOP after HD.

Several studies have attempted to characterize the effects of postural changes and water intake on IOP⁽²⁷⁻³²⁾. The postural change test and the water-drinking test are two classic provocative tests used to change IOP. Research shows that IOP is lower in the sitting position than in the supine position⁽²⁷⁻²⁹⁾. In our study, the patients generally stayed in the supine position during HD, and we measured IOP after

the patients had been in the sitting position for a while. IOP increases with water ingestion and decreases with fasting, so the total body fluid volume is important in IOP measurement⁽³⁰⁻³³⁾. HD patients experience increased water load before HD, restricted water ingestion during HD, and decreased water load after HD. Although we did not find a significant correlation between IOP and body fluid loss, we believe that changes in body fluid volume and the positioning of the patients may have affected our IOP results.

The concentration of aqueous humor, a kind of extracellular fluid, can be affected by blood fluid volume changes after HD. Evaluating anterior chamber parameters is important when defining ocular pharmacokinetics, aqueous humor dynamics, and the pathophysiology of primary open-angle glaucoma, angle-closure glaucoma, and pigmentary glaucoma. Anterior chamber parameters are also crucial in intraocular lens measurement, piggyback and phakic intraocular lens implantation, and cataract surgeries^(34,35). The timing of preoperative measurements, phakic intraocular lens implantation, and cataract surgeries in HD patients is important. Therefore, it is crucial to define anterior segment morphometry changes in these patients and, if there are changes, to evaluate the most appropriate time for preoperative measurements and surgeries.

ACD changes during HD have also been investigated in previous studies^(24,25). In a study researching the ocular effects of acetate HD, ACD was found to decrease after acetate HD, whereas it did not change after bicarbonate HD⁽²⁴⁾. The authors of the study suggested that the explanation for these findings may be similar to that for dialysis disequilibrium syndrome: As urea is removed from the intracellular compartment, idiogenic osmoles may be generated, resulting in a lower intraocular pH, which may in turn have a local effect on the formation of aqueous humor⁽²⁴⁾. Acetate HD may result in a longer period of acidosis. On the other hand, bicarbonate HD, which is associated with a steady rise in blood pH levels, may more rapidly correct the intraocular acidosis, thus permitting normal aqueous dynamics to proceed⁽²⁴⁾. In another study, Gracitelli et al.⁽²⁵⁾ investigated ACD and axial length changes after bicarbonate HD, reporting that ACD decreased and axial length did not change after HD. However, an ultrasonic biometer was used in both of these studies, and measurements taken using these devices can be inaccurate because of numerous factors, such as corneal impression, excess fluid on the probe, and a thick layer of tear film^(36,37). ACD is the distance between the corneal epithelium and the lens, and may be misinterpreted in HD patients as resulting from CCT changes. Therefore, in the present study, we measured ACD with a 3D rotating Schleimflug topography system, which allows rapid, non-contact anterior segment evaluation. Despite changes in CCT, the ACD values did not change after bicarbonate HD. AQD was also measured, and is defined as the distance between the corneal endothelium and the lens. After eliminating the effects of the CCT changes, the AQD values did not show a significant change after HD. The other anterior chamber parameters, ACV and ACA in the nasal and temporal quadrants, were also similar to the control measurements after HD.

Our study has some limitations. The first limitation is the difference between the timing of the systemic and ocular measurements. The systemic parameters were measured immediately before and after HD, whereas IOP and the anterior segment parameters were measured 30 minutes before and 30 minutes after HD. During this 30 minutes, the patients were transferred to another room for ophthalmologic examination, and it is unclear if the systemic parameters changed over this period. The second limitation is that we did not perform a visual field test or optical coherence tomography to exclude glaucoma; further, we did not perform gonioscopy, and the anterior segment angle was evaluated with the Sirius device only. The third limitation is that we did not use a cataract grading system for the cataract evaluation, so mild cataracts could have been included in the study, which could have resulted in inaccurate measurements of the anterior segment parameters. Other limitations are that the

ocular parameters were not measured during HD, OPP was not measured, systemic medication use was allowed, and we did not include a control group.

In conclusion, we found that HD treatment has significant effects on uncorrected and corrected IOP, CCT, and CV. HD likely causes underestimation of IOP and corneal morphometry changes, and these changes may be important when planning corneal or lenticular surgeries in HD patients.

REFERENCES

- Himmelfarb J, Ikizler TA. Hemodialysis. *N Engl J Med*. 2010;363(19):1833-45. Comment in: *N Engl J Med*. 2011;364(6):584; author reply 585.
- Tomazzoli L, De Natale R, Lupo A, Parolini B. Visual acuity disturbances in chronic renal failure. *Ophthalmologica*. 2000;214(6):403-5.
- Mullaem G, Rosner MH. Ocular problems in the patient with end-stage renal disease. *Semin Dial*. 2012;25(4):403-7.
- Aktas Z, Ozdek S, Asli Dinc U, Akyürek N, Atalay V, Güz G, et al. Alterations in ocular surface and corneal thickness in relation to metabolic control in patients with chronic renal failure. *Nephrology (Carlton)*. 2007;12(4):380-5.
- Jung JW, Yoon MH, Lee SW, Chin HS. Effect of hemodialysis (HD) on intraocular pressure, ocular surface, and macular change in patients with chronic renal failure. Effect of hemodialysis on the ophthalmologic findings. *Graefes Arch Clin Exp Ophthalmol*. 2013;251(1):153-62.
- Nagaoka T, Takeyama Y, Kanagawa S, Sakagami K, Mori F, Yoshida A. Effect of haemodialysis on retinal circulation in patients with end stage renal disease. *Br J Ophthalmol*. 2004;88(8):1026-9.
- Yang SJ, Han YH, Song GI, Lee CH, Sohn SW. Changes of choroidal thickness, intraocular pressure and other optical coherence tomographic parameters after haemodialysis. *Clin Exp Optom*. 2013; 96(5):494-9.
- Dinc UA, Ozdek S, Aktas Z, Guz G, Onol M. Changes in intraocular pressure, and corneal and retinal nerve fiber layer thickness during hemodialysis. *Int Ophthalmol*. 2010; 30(4):337-40.
- Gass JD. Bullous retinal detachment and multiple retinal pigment epithelial detachments in patients receiving hemodialysis. *Graefes Arch Clin Exp Ophthalmol*. 1992; 230(5):454-8.
- Sitprija V, Holmes JH, Ellis PP. Changes in intraocular pressure during hemodialysis. *Invest Ophthalmol*. 1964;3:273-83.
- Sitprija V, Holmes JH, Ellis PP. Intraocular pressure changes during artificial kidney therapy. *Arch Ophthalmol*. 1964;72(5):626-31.
- Gafter U, Pinkas M, Hirsch J, Levi J, Savir H. Intraocular pressure in uremic patients on chronic hemodialysis. *Nephron*. 1985;40(1):74-5.
- Cecchin E, De Marchi S, Tesio F. Intraocular pressure and hemodialysis. *Nephron*. 1986;43(1):73-4.
- Leiba H, Oliver M, Shimshoni M, Bar-Khayim Y. Intraocular pressure fluctuations during regular hemodialysis and ultrafiltration. *Acta Ophthalmol (Copenh)*. 1990;68(3):320-2.
- Ulas F, Dogan U, Keles A, Ertlav M, Tekçe H, Celebi S. Evaluation of choroidal and retinal thickness measurements using optical coherence tomography in non-diabetic haemodialysis patients. *Int Ophthalmol*. 2013;33(5):533-9.
- Levy J, Tovbin D, Lifshitz T, Zlotnik M, Tessler Z. Intraocular pressure during haemodialysis: a review. *Eye (Lond)*. 2005;19(12):1249-56.
- Brandt JD, Beiser JA, Gordon MO, Kass MA; Ocular Hypertension Treatment Study (OHTS) Group. Central corneal thickness and measured IOP response to topical ocular hypotensive medication in the Ocular Hypertension Treatment Study. *Am J Ophthalmol*. 2004;138(5):717-22. Comment in: *Am J Ophthalmol*. 2004;138(5):847-8; *Am J Ophthalmol*. 2005;139(6):1148; author reply 1148-9.
- Tielsch JM, Katz J, Sommer A, Quigley HA, Javitt JC. Hypertension, perfusion pressure, and primary open-angle glaucoma. A population-based assessment. *Arch Ophthalmol*. 1995;113(2):216-21.
- Leske MC, Connell AM, Wu SY, Hyman LG, Schachat AP. Risk factors for open-angle glaucoma. The Barbados Eye Study. *Arch Ophthalmol*. 1995;113(7):918-924. Comment in: *Arch Ophthalmol*. 1996;114(2):235.
- Hu J, Bui KM, Patel KH, Kim H, Arruda JA, Wilensky JT, et al. Effect of hemodialysis on intraocular pressure and ocular perfusion pressure. *JAMA Ophthalmol*. 2013;131(12):1525-31.
- Barbosa CP, Stefanini FR, Penha F, Góes MA, Draibe SA, Canziani ME, et al. Intraocular pressure and ocular perfusion during hemodialysis. *Arq Bras Oftalmol*. 2011;74(2):106-9.
- De Marchi S, Cechin E, Tesio F. Intraocular pressure changes during hemodialysis: prevention of excessive dialytic rise and development of severe metabolic acidosis following acetazolamide therapy. *Renal Fail*. 1989;11(2-3):117-24.
- Jaeger P, Morisod L, Wauters JP, Faggioni R. Prevention of glaucoma during hemodialysis by mannitol and acetazolamide. *N Engl J Med* 1980;303(12):702.
- Rever B, Fox L, Christensen R, Bar-Khayim Y, Nissenson AR. Adverse ocular effects of acetate hemodialysis. *Am J Nephrol*. 1983;3(4):199-204.
- Gracitelli CP, Stefanini FR, Penha F, Góes MA, Draibe SA, Canziani ME, et al. Anterior chamber depth during hemodialysis. *Clin Ophthalmol*. 2013;7:1635-9.
- Samsudin A, Mimiwati Z, Soong T, Fauzi MS, Zabri K. Effect of haemodialysis on intraocular pressure. *Eye (Lond)* 2010;24(1):70-3.
- Weber AK, Price J. Pressure differential of intraocular pressure measured between supine and sitting position. *Ann Ophthalmol*. 1981;13(3):323-6.
- Kothe AC. The effect of posture on intraocular pressure and pulsatile ocular blood flow in normal and glaucomatous eyes. *Surv Ophthalmol*. 1994;38:191-7.
- Prata TS, De Moraes CG, Kanadani FN, Ritch R, Paranhos A Jr. Posture-induced intraocular pressure changes: considerations regarding body position in glaucoma patients. *Surv Ophthalmol*. 2010;55(5):445-53.
- Kronfeld PC. Water drinking and outflow facility. *Invest Ophthalmol*. 1975;14(1):49-52.
- Bruculeri M, Hammel T, Harris A, Malinovsky V, Martin B. Regulation of intraocular pressure after water drinking. *J Glaucoma*. 1999;8(2):111-6.
- Read SA, Collins MJ. Water drinking influences eye length and IOP in young healthy subjects. *Exp Eye Res*. 2010; 91(2):180-5.
- Oltulu R, Satirtav G, Ersan I, Soylu E, Okka M, Zengin N. The effect of dehydration and fasting on corneal biomechanical properties and intraocular pressure. *Eye Contact Lens*. 2016;42(6):392-4.
- Palamar M, Egrilmez S, Uretmen O, Yagci A, Kose S. Influences of cyclopentolate hydrochloride on anterior segment parameters with pentacam in children. *Acta Ophthalmol*. 2011;89(5):461-5.
- Palamar M, Egrilmez S, Uretmen O, Kose S. Evaluation of cornea and anterior chamber using pentacam in pediatric cases. *Turk J Ophthalmol*. 2011;41(3):133-7.
- Stainert RF. A-scan biometry and intraocular lens power calculation. In: Alber DM, Jacobiec FA, editors. *Principles and practice of ophthalmology*. Philadelphia: WB Saunders; 1994. p. 603-6.
- Olsen T, Olesen H, Thim K, Corydon L. Prediction of pseudophakic anterior chamber depth with the newer IOL calculation formulas. *J Cataract Refract Surg* 1992;18(3):280-5.