

Arterial diameter of the celiac trunk and its branches. Anatomical study¹

Diâmetro arterial do tronco celíaco e seus ramos. Estudo anatômico

Luís Augusto da Silveira¹, Fernando Braga Cassiano Silveira^{II}, Valéria Paula Sassoli Fazan^{III}

¹ MS, Assistant Professor, Human Anatomy, Barao de Maua University Center, Ribeirao Preto-SP, Brazil.

^{II} Graduate Student, Department of Surgery and Anatomy, School of Medicine, USP, Ribeirao Preto-SP, Brazil.

^{III} PhD, Assistant Professor, Human Anatomy, Department of Surgery and Anatomy, School of Medicine, USP, Ribeirao Preto-SP, Brazil.

ABSTRACT

Purpose: Despite the fact that anatomical variations of the celiac trunk are well explored in the literature, information on these vessels diameters is scanty. The aims of the present study were to describe the arterial diameters of the celiac trunk and its main branches, and to investigate if these diameters are altered in those cases presenting anatomical variations of these vessels. **Methods:** Twenty-one formalin fixed adult male cadavers were appropriately dissected for the celiac trunk identification and arterial diameter measurements. Arteries measured included the celiac trunk and its main branches (splenic artery, left gastric artery and common hepatic artery), as the proper hepatic artery, right gastric artery, the left and right hepatic arteries and the gastroduodenal artery. **Results:** From the 21 cadavers, 6 presented anatomical variations of, at least, one of the above mentioned branches. The average arterial diameter comparisons between groups (normal and variable) clearly showed smaller diameters for variable vessels, but with no significant difference. **Conclusion:** Our data indicates the possibility of a diameter reduction of the celiac trunk main branches in the presence of anatomical variations. This should be taken into account on the selection for the liver transplantation donors.

Key words: Celiac Trunk. Celiac Artery. Anatomy. Aorta, Abdominal. Cadaver.

RESUMO

Objetivo: Embora as variações arteriais do tronco celíaco e seus ramos estejam bem documentadas na literatura, o mesmo não ocorre com as descrições dos diâmetros dessas artérias. O presente estudo tem por objetivo descrever os diâmetros arteriais do tronco celíaco e seus ramos em indivíduos normais, bem como investigar se esses diâmetros se apresentam alterados em indivíduos com variação anatômica desses vasos. **Métodos:** Utilizamos 21 cadáveres adultos, do sexo masculino, previamente fixados em formol a 10% que foram dissecados apropriadamente para a exposição do tronco celíaco e seus ramos. Com o auxílio de um paquímetro digital, foram obtidos os diâmetros externos dos seguintes vasos: tronco celíaco, artéria hepática comum, artéria gástrica direita, artéria esplênica, artéria gástrica esquerda, artéria gastroduodenal, artéria hepática própria e artérias hepáticas direita e esquerda. **Resultados:** Dos 21 cadáveres avaliados, 6 apresentaram variação anatômica de pelo menos um dos ramos acima mencionados. Ao compararmos os diâmetros arteriais dos vasos normais com os que apresentaram variação, os variáveis apresentaram diâmetros menores, sem, entretanto alcançar níveis de significância. **Conclusão:** Nossos dados apontam para a possibilidade de uma diferença de diâmetros entre artérias abdominais normais e variáveis, sendo esse dado de implicância clínica para os transplantes hepáticos de doadores vivos.

Descritores: Tronco Celíaco. Artéria Celíaca. Anatomia. Aorta Abdominal. Cadaver.

¹Research performed at Department of Surgery and Anatomy, School of Medicine, Sao Paulo University (USP), Ribeirao Preto-SP, Brazil.

Introduction

Despite that the celiac trunk anatomical variations are well explored in the literature, information on the arterial diameter of its main branches is still scanty. Arterial diameter of celiac trunk hepatic branches has gained importance especially due to development of techniques for liver transplantation. Vascular and biliary reconstructions are technically difficult in living-related liver transplantation¹ because of the use of a partial graft with small-diameter vessels and ducts. Hepatic artery thrombosis is one of the most devastating postoperative living-related liver transplantation complication and this risk is related to the use

of small diameter arteries (< 2 mm)¹. In fact, the necessity for vascular reconstruction has led some authors to exclude donors with < 3mm arteries². The right lobe grafts have been the main type of partial liver grafts for adult-to-adult living donor liver transplantation and the anatomy of the right liver must be intensively investigate to assure safety to the donor and prevention of recipient complications³. However, there are only few articles dealing specifically with the right hepatic artery anatomy. As a sufficient supply of arterial blood is indispensable for survival of a right lobe graft, special attention must be paid to the anatomy of the right hepatic artery, including the number and diameter of the vessels³. Usually, based on the arterial diameters, different surgical

techniques must be used and small-sized arteries discrepant from the host are related to unfavorable outcomes³. The post-operative ischemic damage to the liver graft as a result of hepatic artery stenosis is another serious complication after liver transplantation. In these cases, surgical re-anastomosis is often difficult and the angioplasty of the stenotic artery might be an option. Nevertheless, knowledge of the arterial diameter is mandatory for the correct choice of the catheter. Another situation that involves mandatory knowledge of the hepatic arteries diameters is the hepatic arterial infusion chemotherapy for treatment of hepatic metastatic tumors⁴, so the correct size of the catheter can be safely chosen.

Patients with cirrhosis and portal hypertension are at risk for developing splenic artery aneurysms⁵ and its incidence is reported to be 7 – 10% in these cases⁶. These patients may also be at higher risk for splenic artery aneurysm rupture in the post-transplant period⁵. Thus, the preoperative diagnosis of splenic artery aneurysm (including the arterial diameter) is crucial because this area is not routinely explored during transplantation surgery.

For the gastric arteries diameters, information is rare and available in the literature only for the left gastric artery. Importance of this knowledge has been associated with studies of the abdominal segment of the esophagus and the lower esophageal sphincter vascularization⁷, as well as on angiographic studies of the left gastric artery aneurysms⁸.

Despite some sparse information on the celiac trunk and its branches diameters, as well as a wide and well explored arterial variation descriptions literature, there is not, to the best of our knowledge, a study on the association between the anatomical variations and arterial diameters. Thus, the aims of the present study were to describe the arterial diameters of the celiac trunk and its main branches, and to investigate if these diameters are altered in those cases with anatomical variations of these vessels.

Methods

Male embalmed human cadavers (fixed in 10% formaldehyde solution) were included in the present study. The abdominal cavities and retroperitoneal spaces have been partially dissected by medical students during the previous years and further dissections were performed by the authors, with the aid of a D. F. Vasconcellos M-90 surgical microscope. Anomalous tortuosities, dilatations, aneurysms or atheromatous/occlusive disease tissues were discarded at the beginning of the study. A meticulous evaluation was done in each cadaver and, when arteries were not in good condition for obtainment of accurate measurements, they were not included in the study. The study ended up with 21 celiac trunks. An anatomically normal branching of the celiac trunk was accepted as defined by Lipert and Pabst⁹. Quantification and description of anatomical variations were carried out for the celiac trunk and its main branches (left gastric artery, splenic artery and common hepatic artery). Also, the proper hepatic artery, the right gastric artery, the left and right hepatic arteries and the gastroduodenal artery diameters were investigated. A complete diagram of the arterial arrangements was made for each sample, before measurements and photo-documentation. With the aid of an electronic digital caliper (range of 0–300 mm, resolution 0.01 mm, Gehaka, SP, Brazil), the celiac trunk and its main branches diameters were measured as previously described¹⁰, as were the proper hepatic artery, right gastric, right and left hepatic, and

gastroduodenal arteries. Arterial diameter data was plotted on scatter graphs (Figure 1), so the variation between the normal and variable values are clearly represented. Mean arterial diameters were compared between normal and variable arteries. For this comparison, data were tested for normal distribution by the Kolmogorov–Smirnov normality test. If the data presented a normal distribution, comparisons were made by the unpaired Student's *t*-test. Otherwise, comparisons were made by the Mann–Whitney test. Differences were considered significant if $P < 0.05$.

Results

Thirty cadavers were evaluated in total. Four female cadavers, despite the presence of normal arteries, were discarded due to the small number of female samples in this study. Five other cadavers were discarded due to loss or major damage to the large arteries under investigation.

From the 21 cadavers included in this study, 6 presented anatomical variations (approximately 29 %) of, at least, one of the arteries under investigation. None of the variations presented the same pattern between two or more cadavers.

Variation descriptions

Type 1: Normal origins of left gastric artery, common hepatic artery and splenic artery from the celiac trunk. The common hepatic artery trifurcates into right and left hepatic arteries and gastroduodenal artery. No proper hepatic artery is present.

Type 2: A middle colic artery (0.26 cm in diameter) originates from the celiac trunk, together with the left gastric artery, common hepatic artery and splenic artery. Associated to this variation, the right gastric artery originated from the gastroduodenal artery.

Type 3: Origin of the left gastric artery from the abdominal aorta and the celiac trunk giving off only the common hepatic and splenic arteries (hepatosplenic trunk formation). The left gastric artery gives off the inferior phrenic artery (with 0.25 cm in diameter) and the right gastric artery originates from the gastroduodenal artery.

Type 4: The right hepatic artery originates from the superior mesenteric artery. Two left hepatic arteries were observed, both originating on the common hepatic artery. Absence of the proper hepatic artery and the cystic artery (0.20 cm in diameter) originating from the gastroduodenal artery.

Type 5: Two separate arterial trunks coming off the abdominal aorta: a gastrosplenic trunk and a hepatomesenteric trunk. The hepatomesenteric trunk gives off the common hepatic artery.

Type 6: The right hepatic artery originates from the superior mesenteric artery. The proper hepatic artery is absent.

Arterial diameter

Mean arterial diameters of normal and variable arteries are shown on Table 1. Except for the splenic and common hepatic arteries, all variable arteries showed smaller mean diameter compared to normal arteries, but these differences did not reach statistical significance. Figure 1 shows a scatter plot of the normal and variable arterial diameters for all arteries included in the present study. It is evident that the variable arteries show smaller diameters than the normal ones, specially the hepatic arteries.

TABLE 1 - Average arterial diameters (cm) of the celiac trunk and main braches, in the presence of normal and variable anatomy

Artery	Normal	Variable
Celiac trunk	0.79 ± 0.04	0.71 ± 0.06
Splenic	0.53 ± 0.03	0.53 ± 0.04
Left gastric	0.38 ± 0.03	0.33 ± 0.03
Right gastric	0.19 ± 0.01	0.14 ± 0.01
Common hepatic	0.50 ± 0.04	0.52 ± 0.05
Proper hepatic	0.45 ± 0.03	0.38 ± 0.01
Left hepatic	0.30 ± 0.03	0.28 ± 0.03
Right hepatic	0.36 ± 0.04	0.32 ± 0.03
Gastroduodenal	0.40 ± 0.03	0.31 ± 0.02

Note that most of the variable arteries show a smaller diameter compared to normal. No significant differences were found between groups. Data expressed as cm ± standard deviation of mean.

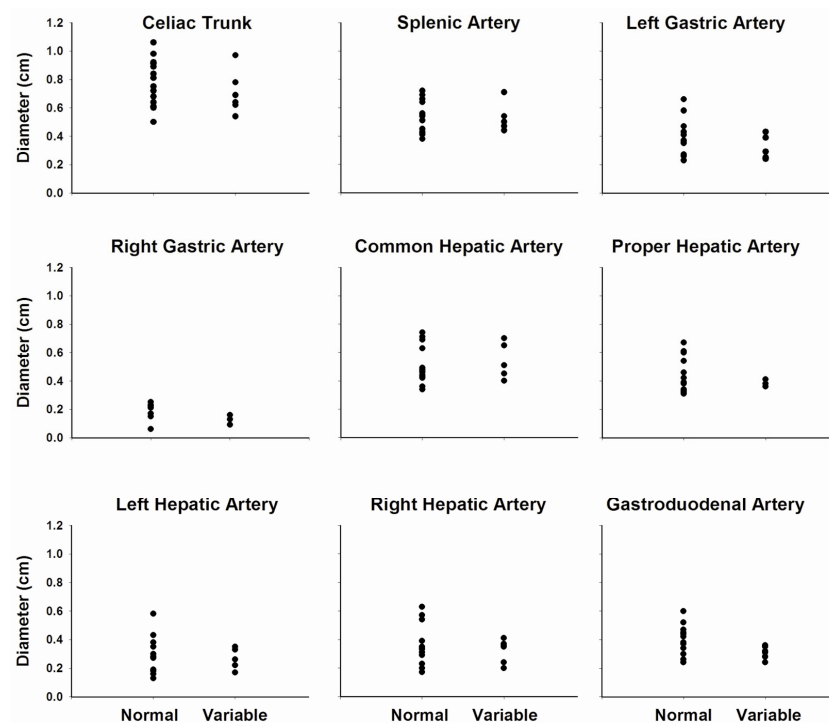


FIGURE 1 - Scatter plot graphs showing individual arterial diameter values of the celiac trunk, splenic artery, left and right gastric arteries, common hepatic artery, proper hepatic artery, left and right hepatic arteries and gastroduodenal artery, in normal and variable individuals. Note that the variable arteries usually showed smaller arterial diameter values than the normal arteries. Also, normal arteries showed a wider range of diameters compared to variable arteries. No significant differences were observed between groups for any of the arteries studied

Discussion

In the present study, from 21 cadavers, six presented anatomical variations of the celiac trunk and its branches, being no variation with the same patterns in two or more cadavers. In this way, approximately 29 % of our sample showed anatomical variations, being each type represented by 4.8 % individually. In spite of the relatively small sample in the present study, our data is not different from the literature that describes 70 % of normal main hepatic branches^{2,9}.

The Type 1 variation found in the present study (absence of the proper hepatic artery) can also be considered normal by some authors⁹. Nevertheless, this absence can be associated to other anatomical variations, in percentages varying from 1 to 12 %⁹.

The Type 2 variation (middle colic artery originating from the celiac trunk) is described in the literature⁹ but, to the best of our knowledge, its association with a right gastric artery origin from the gastroduodenal artery was not previously reported.

The Type 3 variation (left gastric artery origin from the abdominal aorta) is described in the literature and might be present in 3 % of cases⁹ as we showed. The presence of an inferior phrenic artery origin from the left gastric artery is also described in the literature¹¹ as is the right gastric artery origin from the gastroduodenal artery¹¹. Nevertheless, to the best of our knowledge, the combination of all these arterial variation in one sample was not previously described.

The Type 4 variation (right hepatic artery origin from the superior mesenteric artery) was described in the literature¹¹ but this variation is much less frequent than the left hepatic artery origin from the superior mesenteric artery⁹. The presence of two left hepatic arteries originating from the common hepatic artery associated to this variation was not found in the literature.

The Type 5 variation (two trunks from the abdominal aorta: a gastrosplenic and an hepatomesenteric) is described in the literature⁹, on a frequency similar to our results (3 %).

The Type 6 variation (the right hepatic artery origin from the superior mesenteric artery) is described in the literature and seems to be of little importance^{9,11}.

The high incidence of anatomical variations of the celiac trunk and its branches arterial pattern was widely explored in the literature, including a more recent review¹², focused on the surgical anatomy of the hepatic arteries and donor selection for liver transplantation. The celiac trunk is a main dominant vascular structure of the upper abdominal cavity, responsible not only but also for the liver arterial supply. Recent progress on the liver transplantation brought the need of a precise knowledge of the frequency of anatomical variations on the arteries involved. Nevertheless, very little is known about the diameter

of these arteries and based on this knowledge, new surgical reconstructive techniques can be proposed. Despite that formalin fixed cadavers were used in the present study, our data is reliable since it is compatible to those obtained in fresh cadavers⁷ or *in vivo*, through non invasive methods to access vascular caliber^{1,3,5}.

Table 2 shows a comparison between our normal data and data obtained from the literature. In spite of some available data in the literature, it was not possible to compare all arteries investigated because vascular diameter data is rare. This is especially the case of the splenic, the right gastric and the gastroduodenal arteries, whose data presented in the present study are original to the literature. Splenic artery aneurysms are described in the literature and most of descriptions are of vessels larger than 2 cm in diameter¹³. Nevertheless, Sunagozaka *et al.*¹⁴ described saccular aneurysms measuring 0.4 to 2.2 cm in diameter. It is important to notice that the described diameters of some aneurysms are close to normal values, reinforcing the importance of the normal values knowledge. No descriptions of arterial diameter values for the right gastric artery and for the gastroduodenal artery were found in the literature. Only one reference on resonance angiography of abdominal arteries attesting that the gastroduodenal artery is too small was found¹⁵. This might also be the case for the right gastric artery.

The knowledge of normal arterial diameters in a specific population is of great importance in order to make correct and precise radiological diagnosis of arterial aneurysms^{5,8}. Also, evaluation of arterial diameters is fundamental for liver transplantation follow up. Previous knowledge of the normal and expected values for a specific artery might help the early diagnosis, through radiological exams, of an arterial stenosis, even before clinical signs of low arterial flow.

It seems to be consensual from the literature that arteries with diameters < 0.3 cm are considered of high surgical risk on liver transplantation surgery^{1,2,5}. An important consideration about our results is that the hepatic arteries (common and proper) had always diameters > 0.3 cm, even those with anatomical variations.

TABLE 2: Mean arterial diameter of the normal celiac trunk and main branches obtained in the present study. Comparison with data from other authors, obtained *in vivo*, through radiological exams. Data expressed as cm ± standard deviation of mean.

Artery	Authors	Literature data	Present study data
Celiac trunk	Best e cols. (1991)	0.80	0.79 ± 0.06
Left gastric	Yan e cols. (1998)	0.206	0.38 ± 0.03
Common hepatic	Han e cols. (2002)	0.27	0.50 ± 0.04
	Ishigami e cols. (2004)	0.63	
Proper hepatic	Nghiem e cols. (1999)	0.30	0.45 ± 0.03
	Douard e col. (2002)	0.20	
Left hepatic	Nghiem e cols. (1999)	0.20	0.30 ± 0.03
Right hepatic	Ahn e cols. (2005)	0.24	0.36 ± 0.04
	Nghiem e cols. (1999)	0.30	

Nevertheless, when considering the right and left hepatic arteries on normal celiac trunks, four cadavers presented arteries smaller than 0.3 cm. This corresponds to 40 % of normal arteries. On variable celiac trunks, three right hepatic arteries and two left hepatic arteries were less than 0.3 cm in diameters. Kostelic *et al.*² found anomalous hepatic artery anatomy in 67 % of potential donors, and a left hepatic artery less than 0.2 cm in 1 % and between 0.2 and 0.3 in 5 % of potential donors. The authors mention that arteries less than 0.2 cm in diameter was an absolute exclusionary criteria for living related liver transplant donor while arteries between 0.2 and 0.3 cm in diameter were a relative exclusionary criteria. More recently, Ishigami *et al.*¹⁶ demonstrated that patients with variant arterial anatomy had higher post-transplantation complication rates, compared to patients with normal anatomy. Also, this is the first literature report indicating that patients with variant arterial anatomy had arteries of smaller diameters compared to those with normal anatomy¹⁶, which is similar to our results. Those authors concluded that variant artery anatomy in liver transplant recipient increases the risk of complications after transplantation and that the smaller caliber of the native common hepatic artery may contribute to the higher risk.

Conclusion

Our results also suggest that there is a reduction of the arterial diameters of the celiac trunk and its branches in the presence of anatomical variations of these arteries, which have direct clinical implications for liver transplantation.

References

1. Douard R, Ettorre GM, Chevallier JM, Delmas V, Cugnenc PH, Belghiti J. Celiac trunk compression by arcuate ligament and living-related liver transplantation: a two-step strategy for flow-induced enlargement of donor hepatic artery. *Surg Radiol Anat.* 2002;24:327-31.
2. Kostelik JK, Piper JB, Leef JA, Lu CT, Rosenblum JD, Hackworth C, Kahn J, Thistlethwaite JR, Whittington PF. Angiographic selection criteria for living related liver transplant donors. *Am J Roentgenol.* 1996;166:1103-8.
3. Ahn CS, Lee SG, Hwang S, Moon DB, Ha TY, Lee YJ, Park KM, Kim KH, Kim YD, Kim KK. Anatomic variation of the right hepatic artery and its reconstruction for living donor liver transplantation using right lobe graft. *Transplant Proc.* 2005;37:1067-9.

4. Watanabe M, Takita W, Tsuchiya M, Otsuka Y, Tamura A, Kaneko H, Kobayashi K. Hepatic arterial cannulation using the side holed catheter. *J Surg Oncol.* 2005;91:145-9.
5. Nghiem HV, Dimas CT, McVicar JP, Perkins JD, Luna JA, Winter III TC, Harris A, Freeny PC. Impact of double helical CT and three-dimensional CT arteriography on surgical planning for hepatic transplantation. *Abdom Imaging.* 1999;24:278-84.
6. Ayalon A, Wiesner R, Perkins J, Tominaga S, Hayes DH, Krom RA. Splenic artery aneurysms in liver transplant patients. *Transplantation.* 1988;45:386-9.
7. Yan Y, Chen C, Chen Y, Wu Y, Shi Z. Arterial patterns in the thoracic and abdominal segments of the esophagus: anatomy and clinical significance. *Surg Radiol Anat.* 1998;20:399-402.
8. Sasaki A, Bandoh T, Shiraishi N, Adachi Y, Kitano S, Kaketani K. Laparoscopic ligation of an aneurysm of the left gastric artery. *Surg Laparosc Endosc Percutan Tech.* 2001;11:225-7.
9. Lippert H, Pabst R. Arterial variations in man: classification and frequency. München: JF. Bergmann Verlag; 1985.
10. Ribeiro RA, Ribeiro JAS, Rodrigues Filho OA, Caetano AG, Fazan VPS. Common carotid artery bifurcation levels related to clinical relevant anatomical landmarks. *Int J Morphol.* 2006;24:413-6.
11. McVay CB. Anson & McVay surgical anatomy. 6ed. Philadelphia: WB. Saunders Company; 1984.
12. Hiatt JR, Gabbay J, Busuttil RW. Surgical anatomy of the hepatic arteries in 1000 cases. *Ann Surg.* 1994;220:50-2.
13. Berceci SA. Hepatic and splenic artery aneurysms. *Semin Vasc Surg.* 2005;18:196-201.
14. Sunagozaka H, Tsuji H, Mizukoshi E, Arai K, Kagaya T, Yamashita T, Sakai A, Nakamoto Y, Honda M, Kaneko S. The development and clinical features of splenic aneurysm associated with liver cirrhosis. *Liver Int.* 2006;26:291-7.
15. Miyazaki T, Yamashita Y, Shinzato J, Kojima A, Takahashi M. Two-dimensional time-of-flight magnetic resonance angiography in the coronal plane for abdominal disease: its usefulness and comparison with conventional angiography. *Br J Radiol.* 1995;68:351-7.
16. Ishigami K, Zhang Y, Rayhill S, Katz D, Stolpen A. Does variant hepatic artery anatomy in a liver transplant recipient increase the risk of hepatic artery complications after transplantation? *Am J Roentgenol.* 2004;183:1577-84.

Acknowledgements

The authors are thankful for the excellent technical support of Nelson Roberto da Mota, Marcelo Savoldi, Valdir Mazzucato Júnior and Waldeci Roberto Bim, from the Multidisciplinary Laboratories, School of Medicine of Ribeirão Preto, while the study was carried out.

Correspondence:

Valéria Paula Sassoli Fazan
Department of Surgery and Anatomy
School of Medicine of Ribeirão Preto - USP
Av. Bandeirantes 3900
14049-900 Ribeirão Preto-SP Brazil
Phone: (55 16)3602-2501
Fax: (55 16)3633-0017
vpsfazan@yahoo.com.br
vpsfazan@gmail.com

Conflict of interest: none
Financial source: FAPESP and CNPq

Received: August 19, 2008
Review: October 14, 2008
Accepted: November 12, 2008

How to cite this article

Silveira LA, Silveira FBC, Fazan VPS. Arterial diameter of the celiac trunk and its branches: anatomical study. *Acta Cir Bras.* [serial on the Internet] 2009 Jan-Feb;24(1). Available from URL: <http://www.scielo.br/acb>