

## Immunoexpression of proliferating cell nuclear antigen (PCNA) in spleen of splenectomized rats with preservation of inferior pole, submitted to hyperbaric oxygenation<sup>1</sup>

Marcela Souza Lima Paulo<sup>I</sup>, Filipy Taifson Barbosa dos Santos<sup>II</sup>, Polyanna Gonçalves Rocha<sup>III</sup>, Mirella de Barros Silva<sup>IV</sup>, Luiz Cálice Cintra<sup>V</sup>, Luciene Lage da Motta<sup>VI</sup>, Flávia Imbroisi Valle Errera<sup>VII</sup>, Danilo Nagib Salomão Paulo<sup>VIII</sup>, Tarcizo Afonso Nunes<sup>IX</sup>

<sup>I</sup>Fellow PhD degree, Postgraduate Program in Surgical and Ophthalmological Applied Sciences, Federal University of Minas Gerais (UFMG), Belo Horizonte-MG, Brazil. Intellectual and scientific content of the study, acquisition and interpretation of data, manuscript preparation.

<sup>II</sup>Graduate student, Pharmacy, College of Health Sciences, EMESCAM, Vitoria-ES, Brazil. Acquisition and interpretation of data, manuscript preparation.

<sup>III</sup>Graduate student, Pharmacy, College of Health Sciences, EMESCAM, Vitoria-ES, Brazil. Interpretation of data.

<sup>IV</sup>Graduate student, Pharmacy, College of Health Sciences, EMESCAM, Vitoria-ES, Brazil. Acquisition and interpretation of data, manuscript preparation.

<sup>V</sup>PhD, Associate Professor, College of Health Sciences, EMESCAM, Vitoria-ES, Brazil. Analysis and interpretation of data.

<sup>VI</sup>MD, Pathologist, Santa Casa de Misericórdia de Vitória Hospital, Brazil. Analysis and interpretation of data.

<sup>VII</sup>Associate Professor, Department of Morphology, College of Health Sciences, EMESCAM, Vitoria-ES, Brazil. Intellectual and scientific content of the study, manuscript preparation, critical revision.

<sup>VIII</sup>PhD, Chairman, Full Professor, Department of Surgery, College of Health Sciences, EMESCAM, Vitoria-ES, Brazil. Conception, design, intellectual and scientific content of the study; statistical analysis; manuscript writing; critical revision.

<sup>IX</sup>PhD, Chairman, Full Professor, Department of Surgery, Medical School, UFMG, Belo Horizonte-MG, Brazil. Manuscript writing, critical revision.

---

**PURPOSE:** To analyze PCNA immunoexpression on the inferior pole of the spleen of splenectomized rats submitted to hyperbaric oxygenation (HBO).

**METHODS:** Were analyzed fragments of the inferior pole of the spleen of 20 male Wistar rats submitted to splenectomy with preservation of the inferior pole. The rats were divided in two groups: group A (n=10) without HBO and group B (n=10) submitted to HBO at 2, 5 atmospheres per 120 minutes, twice a day for three days and once a day for seven days. The groups were then subdivided in four subgroups: A15 (n=5), with euthanasia on the 15<sup>th</sup> day; A45 (n=5), with euthanasia on the 45<sup>th</sup> day; B15 (n=5) with euthanasia on the 15<sup>th</sup> day and B45 with euthanasia on the 45<sup>th</sup> day. Respectively on these days, fragments of the inferior pole of the spleen of all animals were collected and analyzed with the immunohistochemistry technique in order to evaluate PCNA expression.

**RESULTS:** There was an expressive increase in PCNA immunoreactivity in the group B. The 45 day postoperative period resulted in a higher level of positivity than the 15 day postoperative period (p<0.01).

**CONCLUSION:** The quantitative analysis of proliferating cell nuclear antigen positive suggests that hyperbaric oxygenation increases cellular proliferation, contributing to splenic regeneration.

**Key words:** Proliferating Cell Nuclear Antigen. Hyperbaric Oxygenation. Splenectomy. Rats.

---

## Introduction

For a long time the spleen was considered a non-essential organ to life, and its removal suggested that it caused no serious damage to the patient<sup>1</sup>. In the last decades, however, it was confirmed that splenectomy in children and adults results in high mortality in the postoperative period caused by fulminating sepsis<sup>2</sup>. Infectious complications were also observed in experimental animals<sup>3</sup>. For these reasons, conservative spleen surgeries were again taken into account. Subtotal splenectomy with inferior pole preservation (ESTPI) in which blood irrigation is maintained by the vessels of the gastrosplenic ligament is one of the most recently described.

The investigation of the inferior pole of the spleen of dogs and rats<sup>4-6</sup> submitted to ESPTI showed alterations in the viability of the remaining tissue, in the immediate postoperative period. Rats submitted to this procedure, followed by hyperbaric oxygenation (HBO) at 100% pure oxygen, in conventional microscopy, showed larger lymphatic follicles, increase of the amount of cells and vessels and more lymphocytic cell proliferation in the inferior pole of the spleen<sup>7,8</sup>. Considering these findings, we proposed to evaluate the immunohistochemistry expression (IHC) of the proliferating cell nuclear antigen (PCNA) which main function is to increase the activity of delta DNA polymerase during DNA replication, event that precedes cell division process<sup>9</sup>. In this context, PCNA investigation might contribute to a better comprehension of the cellular processes that occur during the growth and proliferation of the inferior pole of the spleen after HBO.

## Methods

This study was approved by the Ethics Committee in Animal Experimentation (n° 004/08-CETEA) of the Federal University of Minas Gerais, Brazil. The study was conducted at the Laboratory of IHC of Research Center EMESCAM in collaboration with the Laboratory of Cellular and Molecular Biology of Human Cancer of the Federal University of Espirito Santo, Brazil (UFES).

### Study design

Twenty male Wistar rats submitted to ESTPI were used in this study. The animals were randomly divided in two groups according to whether they were submitted or not to HBO and were later subdivided in four groups according to the day of specimen collection of the inferior pole of the spleen for IHC analysis<sup>8</sup> (Table 1).

**TABLE 1** – Distribution of rats in two groups according to the use of hyperbaric oxygenation and in four subgroups according to the postoperative day when the collection of specimens of the spleen inferior pole (n=20) was done.

Groups	Subgroups - day of specimen collection	Number of spleen tissue fragments
Without HBO (n=10)	A15 – 15 <sup>th</sup> day (n=5)	n=5
	A45 – 45 <sup>th</sup> day (n=5)	n=5
With HBO (n=10)	B15 – 15 <sup>th</sup> day (n= 5)	n=5
	B45 – 45 <sup>th</sup> day (n=5)	n=5

### *Surgical procedure and hyperbaric oxygenation*

The animals were anesthetized with 75mg/Kg ketamine chloridrate (Vetaset®, Fort Lodge – Iowa, USA) associated with 5mg/Kg of xylazine chloridrate (Kensol® König – Avellaneda, Argentina) via intraperitoneal injection. Next, the rats were submitted to laparotomy for the realization of ESTPI which remained irrigated by the vessels of the gastrosplenic ligament<sup>4</sup>. The spleen superior portion was removed according to Paulo *et al.*<sup>10</sup>. After the end of the anesthetic effect, the animals in group B were submitted to HBO in an appropriate chamber, according to what was established in the protocol<sup>10</sup>: gradual compression up to 2, 5 atmospheres, being 1 atm at sea level and 1.5 atm registered at the chamber manometer, maintained at this pressure for 90 minutes, followed by gradual decompression of the chamber for 25 minutes. This procedure was carried out twice a day for three days and once a day for seven days.

### *Specimen collection from the inferior pole of the spleen and euthanasia*

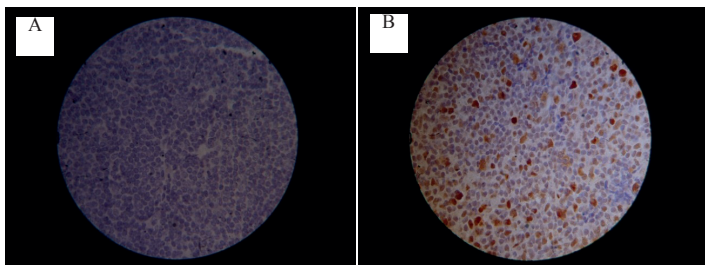
The twenty rats were submitted to a new laparotomy on the 15<sup>th</sup> and 45<sup>th</sup> postoperative day, according to the subgroup, for the collection of specimen from the spleen inferior pole, followed by euthanasia (Table 1). The splenic fragments were fixed on neutral-buffered formalin 10% (pH 7.0) and sent to the laboratory of anatomical pathology.

*Immunohistochemistry analysis*

The specimens collected from the inferior pole of the spleen were kept in formalin for 24-48 hours and processed in paraffin for IHC analysis. Sections were cut at 3mm thickness and placed on pre-treated glass slides (AutoFrost® - CancerDiagnostic – United States of America). Immunostaining was done by anti-PCNA primary antibody (Mouse monoclonal [PC-10] to PCNA, BSA and Azide free [ab80576] - Abcam®).

For the IHC procedure, glass slides were: deparaffinized with xylol at room temperature twice at 10 minutes each; hydrated in 100% ethanol, 95% ethanol, 80% ethanol and distilled water; antigenic recuperation: heating the slides in 10mmol/L citrate buffer pH 6.0 at 98°C for 30 minutes; maintained at room temperature for thirty minutes and washed in phosphate-buffered saline (PBS); washed in 0% fat free powder milk to decrease the background and incubated in wet chamber for 30 minutes; incubated with 300 µL of primary antibody PCNA solution diluted 1:200 in wet chamber for two hours; washed with PBS; incubated in wet chamber with eight drops of secondary antibody (Histofine® - Nichirei – cod.414191f) in room temperature for 30 minutes; washed in PBS; incubated with 3mL of peroxidase inhibitor (H<sub>2</sub>O<sub>2</sub> 3%) at room temperature for five minutes; washed with PBS; incubated in wet chamber with diaminobenzidine solution (DAB) at room temperature for five minutes; washed with distilled water; stained with 1 mL Harris' hematoxylin for two minutes; washed with distilled water; immersed in 5% ammonium hydroxide in order to obtain blue nucleus and brown cytoplasm; washed in distilled water; dehydrated in alcohol and xylol and mounted with coverslips using Canada Balsam.

A slide with a spleen section was used as negative control (Figure 1A) without using the specific antibody and, as positive control (Figure 1B) with human amygdala fragments. The positive nuclei presented brownish or yellowish coloration and were considered positive, no matter the staining intensity.



**FIGURE 1** – (A) Negative Control – a section of the spleen without brown staining indicating the absence of PCNA (x100) marker. (B) Positive Control – a section of human amygdala with positive PCNA marker, made evident by the brown staining (x100).

Quantitative analysis of PCNA expression was done in optical microscope. The pathologist chose the most representative areas with x100 augmentation (immersion). The level of positivity was determined by the formula described below<sup>9</sup>:

$$\text{Level of positivity} = \frac{\text{Number of positive cells}}{\text{Number of counted cells}} \times 100$$

Data was represented by median. The difference between the groups was evaluated with the non-parametric Mann Whitney test and p<0.05 was considered significant.

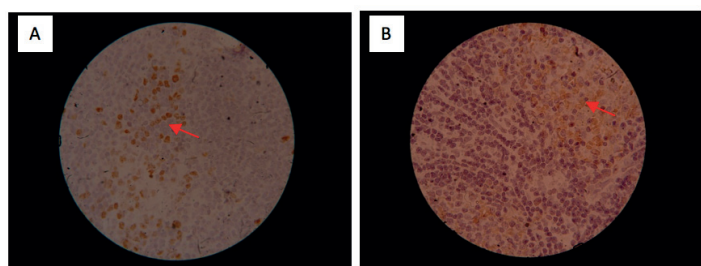
**Results**

PCNA was immunopositive in all subgroups with a varying positivity level between 53.0% and 84.0%. Among the subgroups which were not submitted to hyperbaric oxygenation, there was no difference in the positivity level. However, there was a difference of positivity level among the groups of animals submitted or not to hyperbaric oxygenation. In the groups which were not treated, there was no difference in positivity level. B15 subgroup (Figure 2A) presented a positivity level higher than that of A15 (p<0.01 (Figure 2B) and the same difference was observed between the groups A45 and B45 (p<0.01). 45 days of postoperative resulted in higher level of positivity than that of 15 days, only in animals submitted to hyperbaric oxygenation (p<0.01) (Table 2).

**TABLE 2** - The cellular proliferation of the inferior pole of rats submitted to ESTPI treated and those non-treated with hyperbaric oxygen in the 15<sup>th</sup> day of postoperative period and in the 45<sup>th</sup> day of postoperative period.

Group	Subgroup	Cellular proliferation		P <sub>1</sub>	P <sub>2</sub>
		IP	M		
A	A15	53.5%	535.40	NS	<0.01
	A45	53.0%	550.40		
B	B15	71.5%	715.00	<0.01	<0.01
	B45	84.0%	841.00		

M - Median; IP – Positivity index; NS – Non Significant. (Mann's Whitney Test) p1 – Comparison between subgroups A15 and A45 and subgroups B15 and B45 p2 – Comparison between subgroups A15 and B15 and between subgroups A45 and B45



**FIGURE 2** - (A) There is a greater number of PCNA-positive cells (indicated by the arrow) in a section of a treated animal spleen – B15 (x100). (B) There is a small number of PCNA-positive cells in a section of a non-treated animal spleen – A15 (x100).

## Discussion

Many experimental studies have been conducted in order to better understand the biological properties of hyperbaric oxygenation. Among the most used markers to assess cell proliferation PCNA stands out, and its immune expression has been investigated in many studies. In this study, a significant difference was noted in PCNA immunoeexpression in the group treated with HBO.

HBO is used in the treatment of many inflammatory diseases and ischemic conditions such as wounds, carbon monoxide intoxication and acute necrotic infection<sup>12</sup>. The increase of oxygen dissolution in the blood causes oxygenation in hypoxic areas<sup>12</sup>. HBO increases free radical generation that oxidizes membrane proteins and lipids and inhibits bacterial metabolic functions. Hyperoxia in normal tissues causes fast significant vasoconstriction which is compensated by the increase of oxygen transportation in the plasma and the micro-vascular blood flow in the ischemic tissue is effectively improved<sup>16</sup>. In conventional histologic analysis, Costa-Val *et al.*<sup>17</sup> did not find spleen and liver cellular proliferation in rats submitted to HBO at 2, 5 atm for 90 minutes in 20 consecutive days, but found a significant reduction of extra medullar hepatic eritropoyesis<sup>17</sup>.

There are no reports in the literature on the evaluation of spleen cellular proliferation after HBO using PCNA. In order to understand the effects of this therapy on spleen regeneration references on the regeneration of other organs were considered, especially those on liver regeneration.

Although there was a decrease in renal tissue necrosis, HBO did not increase PCNA immunoeexpression, due probably to insufficient HBO time at 2, 5 atm (2 days for 90 minutes)<sup>11</sup>.

Many authors<sup>12-14</sup> have studied the effect of HBO in liver regeneration in rats after 70% hepatectomy using PCNA to evaluate proliferative activity. There was an increase in cellular

proliferation with a positivity index varying from 4% to 69% in treated groups and of 1, 4% to 50% in non-treated groups. Pressure in these groups varied from 2.0 to 2.8 atm, being 2.5 atm the most used.

The great variety of protocols described may confirm differences in positivity index found in many studies. These protocols include continuous treatment for many days; however, there are reports in which HBO effects are observed in a few hours after the beginning of treatment<sup>18</sup>. This is the reason why most recent studies investigate HBO effects between 24-48 hours of postoperative period. It is possible that studies on gene expression will help to understand the effects of early HBO.

## Conclusion

The quantitative analysis of proliferating cell nuclear antigen positive suggests that hyperbaric oxygenation increases cellular proliferation, contributing to splenic regeneration.

## References

1. Crosby WH. An historical sketch of splenic function and splenectomy Lymphology. 1983;16(2):52-5.
2. King H, Shumacker Jr HB. Splenic studies. Susceptibility to infection after splenectomy performed in infancy. Ann Surg. 1952;136(2):239-42.
3. Morris DH, Bullock FD. The importance of the spleen in resistance to infection. Ann Surg. 1919;70(5):513-21.
4. Paulo DNS, Lázaro da Silva A, Cintra LC, Bof AM, Santiago DC, Ribeiro GB. Esplenectomia subtotal, em cães, com preservação do pólo inferior suprido por vasos do ligamento gastroesplênico. Rev Col Bras Cir. 1999;26(3):147-52.
5. Paulo DNS, Paulo ICAL, Kalil M, Vargas PM, Lázaro da Silva A, Baptista JFA, Guerra AJ. Subtotal splenectomy preserving the lower pole in rats: technical, morphological and functional aspects. Acta Cir Bras. 2006;21(5):321-7.
6. Paulo ICAL, Paulo DNS, Cintra LC, Santos MCS, Rodrigues H, Ferrari TA, Azevedo TC, Silva AL. Preservative spleen surgery and hiperbaric oxygen therapy. Acta Cir Bras. 2007;22(1):21-8.
7. Paulo ICAL, Silva AL, Piras C, Ramos BF, Zanetti FR, Paulo DNS. Aspectos morfológicos e funcionais dos autoimplantes esplênicos em ratos tratados com oxigênio hiperbárico. Rev Col Bras Cir. 2010;37(3):226-33.
8. Paulo MSL, Paulo ICAL, Nunes TA, Silva AL da, Cintra LC, Paulo DNS. Effect of hyperbaric oxygen therapy in rats with subtotal splenectomy preserving the inferior pole. Acta Cir Bras. 2010;26(3):156-8.
9. Novellino ATN, Amorim RFB, Queiroz LMG, Freitas RA. Immunoeexpression analysis of PCNA and p53 in oral squamous cell carcinoma: correlation with histological grading of malignancy and clinical features. Acta Cir Bras. 2003;18(5):458-6.
10. Paulo DNS, Kalil M, Grillo Junior LSP, Borges EB, Cintra LC, Pereira FEL, Lázaro da Silva A. Viabilidade do baço após a ligadura dos vasos esplênicos: efeito do tratamento com oxigênio hiperbárico. Rev Assoc Med Bras. 2005;51(1):46-4.
11. Ayvaz S, Aksu B, Kanter M, Uzun H, Erboga M, Colak A, Basaran



- UN, Pul M. Preventive effects of hyperbaric oxygen treatment on glycerol-induced myoglobinuric acute renal failure in rats. *J Mol Histol.* 2012;43(2):161-9.
12. Ozden TA, Uzun H, Bohlooli M, Toklu AS, Paksoy M, Simsek G, Durak H, Issever H, Ipek T. The effects of hyperbaric oxygen treatment on oxidant and antioxidants levels during liver regeneration in rats. *Tohoku J Exp Med.* 2004;203:253-12.
  13. Tolentino EC, Castro e Silva O, Zucoloto S, Souza ME, Gomes MC, Sankarankutty AK, Oliveira GR, Feres O. Effect of hyperbaric oxygen on liver regeneration in a rat model. *Transplant Proc.* 2006;38(6):1947-52.
  14. Idetsu A, Suehiro T, Okada K, Shimura T, Kuwano H. Hyperbaric oxygenation promotes regeneration of biliary cells and improves cholestasis in rats. *World J Gastroenterol.* 2011;17(17):2229-6.
  15. Ozdogan M, Ersoy E, Dundar K, Albayrak L, Devay S, Gundogdu H. Beneficial effect of hyperbaric oxygenation on liver regeneration in cirrhosis. *J Surg Res.* 2005;129:260-4.
  16. Gill AL, Bell CAN. Hyperbaric oxygen: its uses, mechanisms of action and outcomes. *QJMed.* 2004;97(7):385-95.
  17. Costa-Val R, Nunes TA, Silva RC, Souza AF, Souza IE, Souza TK. Inhibition of rats extramedullary liver erythropoiesis by hyperbaric oxygen therapy. *Acta Cir Bras.* 2007;22(2):137-4.
  18. Speit G, Dennog C, Radermacher P, Rothfuss A. Genotoxicity of hyperbaric oxygen. *Mutat Res.* 2002;512(2-3):111-9.

---

#### **Acknowledgements**

---

To Luiz Antônio de Oliveira, technician of the Laboratory of Animal Experimentation of EMESCAM; Rosicléia Marcos de Oliveira, technician of the Pathology Laboratory of EMESCAM; PhD Leticia Rangel, Coordinator of the Cellular and Molecular Biology Human Cancer Laboratory of UFES; Renata Daltoé and Karine Lourenzoni Araújo, PhD students and Aline Ferrari and Raison Antunes, undergraduate students for their technical support during the development of the study. FTBS and PGR had a scholarship of scientific initiation.

---

#### **Correspondence:**

Tarcizo Afonso Nunes  
Rua Professor Estevão Pinto, 637/1104 30220-060 Belo Horizonte –  
MG Brasil  
Tel.: (55 31)3409-9632 / 9983-0110  
tan@medicina.ufmg.br

Received: June 12, 2013

Review: Aug 14, 2013

Accepted: Sept 12, 2013

Conflict of interest: none

Financial sources: Foundation for Research Support of the State of Espírito Santo (FAPES) and the Institute for Sustained Development and Practical Actions in the Area of Health (Instituto Solidário)

<sup>1</sup>Research performed at Laboratory of Animal Experimentation, College of Health Sciences (EMESCAM), Vitoria-ES, Brazil.