

Analysis of the effects of topical renal hypothermia on lung tissue after kidney ischemia and reperfusion in rats¹

Marlon Roberto Fiorentini^I, Emanuel Burck dos Santos^{II}, Larisse Longo^{III}, Lúcia Maria Kliemann^{IV}, Walter José Koff^V, Carlos Otávio Corso^{VI}

DOI: <http://dx.doi.org/10.1590/S0102-86502015007000001>

^IFellow Master degree, Postgraduate Program in Surgical Sciences, Department of Surgery, Universidade Federal do Rio Grande do Sul (UFRGS), Brazil. Conception and design of the study, technical procedures, acquisition and interpretation of data, manuscript writing.

^{II}PhD, Attending Physician, Division of Urology, Hospital de Clínicas de Porto Alegre, Brazil. Conception, design, intellectual and scientific content of the study; critical revision.

^{III}MSc, Biomedical Scientist, Laboratory of Experimental Research in Hepatology and Gastroenterology, Hospital de Clínicas de Porto Alegre, Brazil. Acquisition and interpretation of data, technical procedures.

^{IV}PhD, Full Professor, Department of Pathology, School of Medicine, Universidade Federal do Rio Grande do Sul, Brazil. Histopathological examinations, acquisition and interpretation of data.

^VPhD, Full Professor, Department of Surgery, School of Medicine, Universidade Federal do Rio Grande do Sul, Brazil. Conception of the study, critical revision.

^{VI}PhD, Associate Professor, Department of Surgery, School of Medicine, Universidade Federal do Rio Grande do Sul, Brazil. Conception and design of the study, interpretation of data, manuscript writing, critical revision.

ABSTRACT

PURPOSE: To evaluate whether topical renal hypothermia (TRH) at different levels of temperature has protective effects on lung tissue after renal I/R, through an analysis of organ histology and inflammatory markers in lung tissue.

METHODS: Twenty-eight male Wistar rats were randomly allocated across four groups and subjected to renal ischemia at different levels of topical renal temperature: normothermia (no cooling, 37°C), mild hypothermia (26°C), moderate hypothermia (15°C), and deep hypothermia (4°C). To induce I/R, the vessels supplying the left kidney of each animal were clamped for 40 minutes, followed by reperfusion. After four hours, another procedure was performed to harvest the tissues of interest. TNF- α , IL-1 β and myeloperoxidase activity were measured in lung tissue. Histological analysis was performed in hematoxylin and eosin-stained lung specimens.

RESULTS: Induction of renal I/R under deep topical hypothermia resulted in a significant decrease in lung concentrations of TNF- α compared with normothermic I/R ($p < 0.05$). A trend toward significant correlation was found between lung IL-1 β concentration and intensity of hypothermia (Spearman $r = -0.37$; $p = 0.055$). No difference was found in myeloperoxidase activity or histologic injury between groups.

CONCLUSION: Topical renal hypothermia reduces activation of the inflammatory cascade in the lung parenchyma. However, tissue-protective effects were not observed.

Key words: Hypothermia. Ischemia. Reperfusion. Kidney. Lung. Rats.

Introduction

Ischemia and reperfusion (I/R) play a central role in the pathophysiology of renal transplantation and partial nephrectomy. Interruption of blood flow causes tissue injury; paradoxically, its restoration leads to a cascade of events that induce additional damage¹. Although the mechanisms of I/R are still poorly understood, inflammation is involved in the pathophysiology of reperfusion injury. The inflammatory response results in endothelial activation and impairment of microvascular blood flow. Inflammatory mediators such as tumor necrosis factor- α (TNF- α), interleukin-1 β (IL-1 β), interleukin-6 (IL-6), interleukin-8 (IL-8), interleukin-12 (IL-12), interleukin-18 (IL-18), keratinocyte-derived chemokine (KC), and monocyte chemoattractant protein-1 (MCP-1) are produced by the renal tubular epithelium during I/R of kidney tissue²⁻⁴.

In addition to local damage, renal I/R is also a determinant of lung injury, and the leukocytes and cytokines released into the systemic circulation appear to play a central role in this process. Increased pulmonary expression of TNF- α , IL-1 β , IL-6, MCP-1, and intercellular adhesion molecule-1 (ICAM-1) due to upregulation of these mediators also occurs after kidney I/R, and has a synergistic effect in triggering lung tissue damage². Histologically, the lung injury of renal I/R is characterized by inflammation and hemorrhagic infiltration of the alveoli and parenchyma with consequent loss of endothelial barrier function⁵.

Several strategies have been proposed to minimize I/R injury, and hypothermia has attracted increasing interest due to its recognized cytoprotective effect in different experimental scenarios, such as acute myocardial infarction, organ transplantation, cardiopulmonary bypass, spinal cord injury, intestinal ischemia, and neonatal hypoxia. In clinical settings, prospective randomized clinical trials have demonstrated improved neurological outcomes following cardiac arrest and neonatal hypoxia⁶. However, systemic application of hypothermia has been limited due to the risks inherent to this method, such as hemodynamic disturbances, coagulopathy, metabolic acidosis, and arrhythmias. Thus, localized cooling has emerged as a less invasive, safer, and more cost-effective method⁷. In experimental studies, topical hepatic and mesenteric hypothermia attenuated lung injury in models of I/R of these organs^{8,9}. However, the effects of topical renal hypothermia (TRH) on lung tissue have not been studied. The purpose of the present study was to evaluate whether TRH during renal I/R has protective effects on lung tissue and to ascertain the how much cooling is necessary to achieve protection.

Methods

The study protocol was approved by the local Animal Research Ethics Committee (Research and Post-Graduation Group, Hospital de Clínicas de Porto Alegre) under number 1200-52. All experimental procedures were consistent with the U.S. National Institutes of Health Good Animal Practice Guidelines (Guide for the Care and Use of Laboratory Animals, Bethesda, USA, 2011).

Procedures were performed on 28 male Wistar rats (weight 240–487g). All animals were housed under standard environmental conditions with free access to water and food.

Anesthesia and surgical protocol

Detailed descriptions of the surgical technique, I/R model, and method of renal cooling employed are available in a previous publication by our research group¹⁰. Briefly, procedures were performed under general anesthesia achieved by intraperitoneal administration of ketamine (75 mg/kg) and xylazine (10 mg/kg). Adequacy of the depth of anesthesia was obtained by hindpaw reflex testing. Each animal was placed on a heating pad and core body temperature was monitored by a rectal probe and maintained at 37°C during the entire procedure. A longitudinal midline laparotomy was performed, a right nephrectomy was carried out, and the vascular supply of the left kidney was interrupted by placement of an atraumatic vascular clamp for 40 minutes (ischemia time). During this period of ischemia, the animals were subjected to one of four different topical kidney temperature levels, depending on the group to which they had been randomly allocated: G1 (normothermia, no cooling, 37°C), G2 (mild hypothermia, 26°C), G3 (moderate hypothermia, 15°C), or G4 (deep hypothermia, 4°C). A thermal insulation device made of latex and polystyrene was applied to isolate the left kidney from the rest of the abdominal cavity in the hypothermic I/R groups. An intraparenchymal temperature probe was inserted within the kidney to monitor core temperature. The left kidney target temperature was achieved through irrigation of iced saline solution and maintained throughout the ischemia time. After the period of ischemia, the renal pedicle was unclamped and the abdominal wall was closed. Animals were returned to their cages and allowed to recover. After 240 minutes of reperfusion (reperfusion time), the rats were anesthetized again and another surgical procedure was performed. The lungs were removed and a

fragment was flash-frozen in liquid nitrogen and stored at -80°C . The remaining lung tissue was fixed in formalin for subsequent histologic evaluation. Cardiectomy was performed to ensure sacrifice still under anesthesia.

Myeloperoxidase assay

Myeloperoxidase (MPO) activity was measured as described by Bradley *et al.*¹¹. MPO extraction was performed by homogenization of the lung tissue in phosphate buffer (50mM), pH 6.0, containing 0.5% hexadecyltrimethylammonium bromide (100mg tissue/ml phosphate buffer). The samples were sonicated, frozen in liquid nitrogen, and thawed three times. Homogenates were then centrifuged at 12,000 rpm for 10 minutes at 4°C (5810R centrifuge). A 7- μL aliquot of supernatant was added to 200 μL phosphate buffer (50mM, pH 6.0, containing 0.167mg/ml *o*-dianisidine and $5 \times 10^{-4}\%$ H_2O_2) for measurement of MPO activity. The changes in absorbance at 460 nm visible light were measured by spectrophotometry (Zenyth 200rt) and recorded at 20-second intervals for 10 minutes. Results are expressed as units/microgram of tissue ($\text{U}/\mu\text{g}$ tissue).

Assessment of TNF- α and IL-1 β in lung tissue

Lung tissue previously stored at -80°C was thawed and homogenized in a buffer composed of phosphate-buffered saline, 0.5% Triton X-100, and protease inhibitor (Sigma P8340, St. Louis, MO, USA), pH 7.2. Upon completion of homogenization, the material was centrifuged at 4,000 rpm for 10 minutes at 4°C and the supernatant collected for enzyme-linked immunosorbent assay (ELISA). TNF- α (88-7340 eBioscience, San Diego, CA, USA) and IL-1 β (88-6010 eBioscience, San Diego, CA, USA) levels in lung tissue were determined by immunoassay in accordance with the manufacturer's directions. Results are expressed as pg/mL .

Lung histology

Formalin-fixed lung specimens were paraffin-embedded for light microscopy. Sections were obtained and stained with hematoxylin and eosin (H&E) for histologic examination. All specimens were analyzed by a pathologist blinded to the experimental condition of the animals. The histologic criterion for the evaluation of lung injury was the degree of interstitial and alveolar hemorrhage after kidney I/R. Hemorrhagic areas were quantitatively assessed using Image-Pro Plus software (Media Cybernetics, Silver Spring, MD, USA).

Statistical analysis

Statistical analyses were conducted using PASW Statistics, version 18.0. (SPSS Inc., Chicago, IL, USA). Levels of TNF- α , IL-1 β , MPO, and degree of histologic injury were expressed as mean \pm standard deviation and compared between groups using one-way analysis of variance (ANOVA) with robust standard error (Welch's test) followed by post-hoc comparisons using Dunnett's T3 test. Spearman's correlation coefficient was employed to assess correlation among variables. The level of statistical significance was set at $p \leq 0.05$ (two-sided).

Results

Effect of TRH on pulmonary neutrophil infiltration after renal I/R

Polymorphonuclear leukocyte infiltration of lung tissue after renal I/R was quantitated by measuring pulmonary MPO activity. After 240 minutes of reperfusion, no statistically significant differences in level of MPO activity were found among the four groups. The following mean levels of MPO activity were observed: G1 (ischemia without hypothermia, 37°C), 30.8 ± 5.6 $\text{U}/\mu\text{g}$; G2 (ischemia with mild hypothermia, 26°C), 33.6 ± 5.1 $\text{U}/\mu\text{g}$; G3 (ischemia with moderate hypothermia, 15°C), 32.6 ± 1.6 $\text{U}/\mu\text{g}$; G4 (ischemia with deep hypothermia, 4°C), 32.9 ± 3.7 $\text{U}/\mu\text{g}$ (Figure 1).

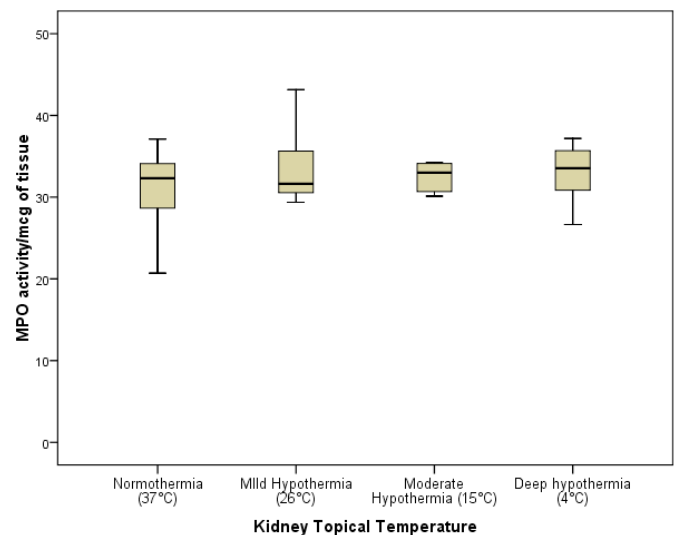


FIGURE 1 - MPO activity in rats undergoing renal ischemia and reperfusion under four different levels of topical kidney temperature. No difference was found among groups.

Effect of TRH on lung TNF- α and IL-1 β levels after renal I/R

TNF- α levels in lung tissue were significantly lower in G4 (deep hypothermia) than in G1 (ischemia without topical cooling). The mean levels observed were: G1, 31.3 \pm 14.8 pg/mL; G2, 14.1 \pm 4.7 pg/mL; G3, 15 \pm 4 pg/mL; G4, 9.6 \pm 3.2 pg/mL ($p < 0.05$) (Figure 2). IL-1 β concentrations in the lung were

also lower among animals subjected to renal ischemia under hypothermic conditions, but the differences did not reach statistical significance. The following mean values were observed: G1, 210.5 \pm 64.7 pg/mL; G2, 179 \pm 57.1 pg/mL; G3, 169.6 \pm 28.4 pg/mL; G4, 156.2 \pm 25.8 pg/mL (Figure 2). The intensity of TRH showed a significant correlation with pulmonary levels of TNF- α (Spearman $r = -0.71$; $p < 0.001$) and a borderline-significant correlation with pulmonary IL-1 β concentration (Spearman $r = -0.37$; $p = 0.055$).

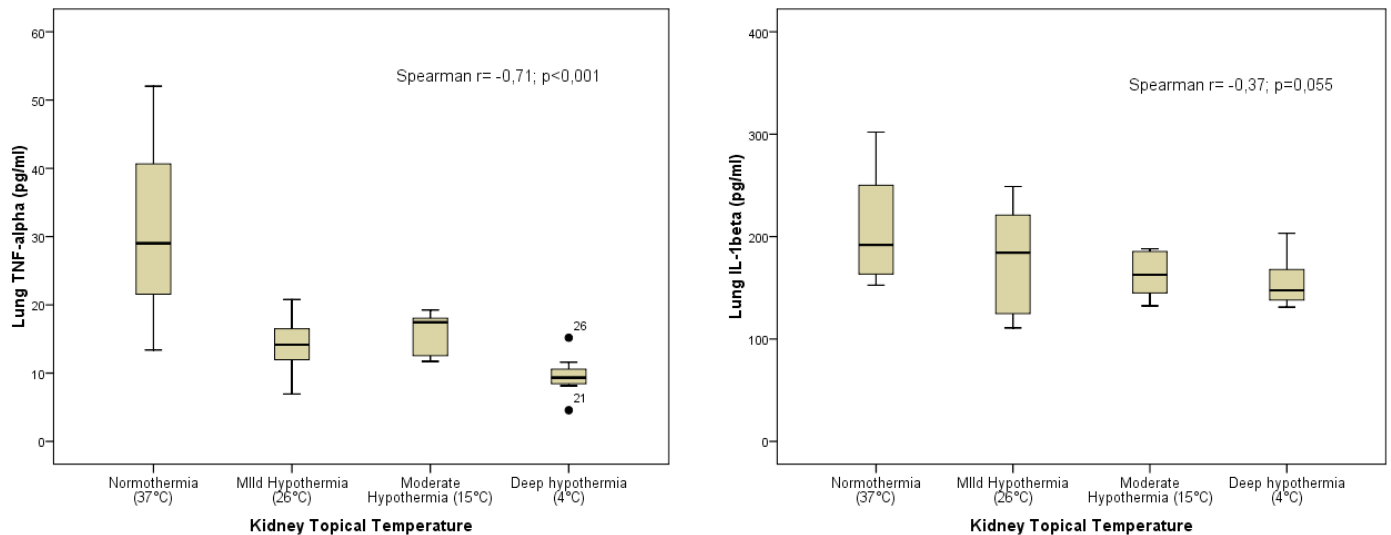


FIGURE 2 - Pulmonary levels of TNF- α and IL-1 β in animals undergoing renal ischemia under four distinct levels of topical kidney temperature. TNF- α was significantly decreased in animals under deep topical hypothermia (4°C) during renal ischemia compared with animals undergoing renal ischemia under a normothermic condition ($p < 0.05$). A significant correlation was observed between intensity of topical hypothermia and lung TNF- α levels. Although no significant difference in the levels of IL-1 β was seen among groups, a correlation with borderline statistical significance was noted between intensity of topical hypothermia and lung IL-1 β levels.

Effect of TRH on pulmonary histology after renal I/R

H&E-stained lung sections were analyzed under light microscopy. Quantitative assessment of hemorrhagic areas in the lung parenchyma revealed no significant difference in the degree of alveolar or interstitial hemorrhage between groups (Figure 3).

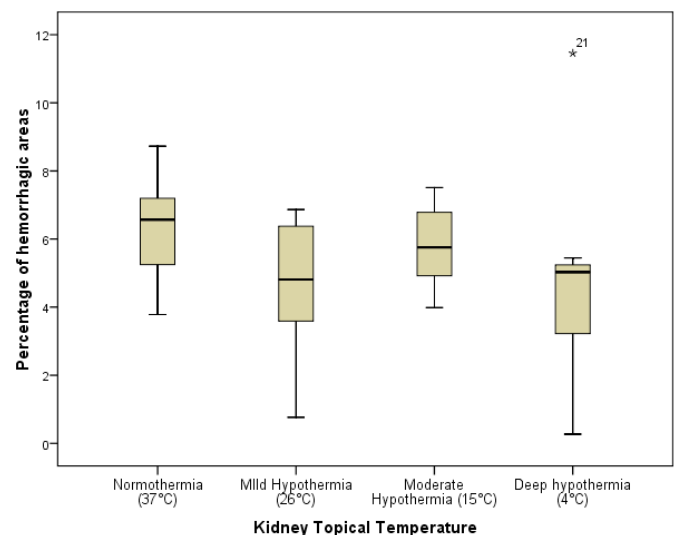


FIGURE 3 - Quantitative assessment of hemorrhagic areas in the lung parenchyma in animals undergoing renal ischemia under four different levels of topical kidney temperature. Results express the percentage of tissue affected by hemorrhagic changes. No difference was found among groups.

Discussion

Little is known about kidney-lung crosstalk in the clinical setting of ischemic acute kidney injury (AKI). Interest in this area has been growing due to the high morbidity and mortality rates associated with AKI. Despite recent improvements in supportive care, these rates have remained unchanged over the past two decades^{12,13}. Both experimental and clinical studies have pointed to an association between AKI and extrarenal organ injury. Pulmonary insufficiency is perhaps one of the most clinically apparent and widely studied distant organ effects of kidney injury. AKI has been shown to determine serious consequences on the pulmonary health of critically ill patients, with increased length of time on mechanical ventilation and increased difficulty weaning from the ventilator¹⁴.

The remote effects of AKI in the lungs are due to multiple distinct mechanisms: uncontrolled inflammatory cascade, oxidative stress, apoptosis, lung leukocyte activation and trafficking, and downregulation of sodium-potassium pump and water channels. These events lead to increased pulmonary vascular permeability, interstitial edema, alveolar hemorrhage, red blood cell sludging, and, consequently, compromised lung mechanics. Extravasation of fluid into alveoli also inactivates surfactant, further jeopardizing lung function^{12,13,15,16}.

A growing number of publications have shown that renal I/R determines increases in serum, kidney, and lung levels of cytokines such as TNF- α , IL-1 β , ICAM-1, and nuclear factor kappa-B (NF- κ B)^{2,4,16-18}. Increased levels of these inflammatory mediators in remote organs are due not only to increases in their systemic concentrations, but also to transcriptional changes that take place in extrarenal organs during ischemic AKI, leading to the expression of proinflammatory genes¹⁶. Exposure of leukocytes to inflammatory mediators allows their rolling on activated endothelium. Additionally, interaction of adhesion receptors with their counterreceptors on white blood cells leads to mobilization of leukocytes on the endothelium and diapedesis across the vessel wall, leading to accumulation of neutrophils and mononuclear cells in the interstitium^{2,19}.

Several strategies have been evaluated with the aim of reducing both the local injury and the secondary systemic injuries caused by renal I/R. In this scenario, curcumin, an orange-yellow polyphenol present in turmeric, has been shown to reduce renal and pulmonary damage by inhibition of apoptotic mechanisms, as well as by reducing systemic and tissue levels of cytokines such as TNF- α and IL-1 β ³. Alpha-melanocyte-stimulating hormone (α -MSH), an anti-inflammatory cytokine, and dexmedetomidine, an alpha2-

adrenergic receptor agonist with anti-inflammatory properties, have also been evaluated as potential strategies to prevent secondary lung injury during renal I/R. Both substances have been shown to inhibit upregulation of lung TNF- α and ICAM-1 messenger RNA, as well as to reduce leukocyte infiltration into the lung^{16,20}.

Grezzana *et al.*²¹, using methods very similar to those of the present study, demonstrated that induction of topical hepatic hypothermia at 26°C protected the ischemic liver against I/R injuries and allowed early recovery of hepatic function. Santos *et al.*¹⁰ demonstrated that kidney levels of catalase were lower in rats undergoing deep TRH (4°C) than in animals exposed to normothermic renal I/R, and concluded that topical hypothermia can reduce oxidative stress in the kidney.

The present study demonstrated a significant decrease in TNF- α concentrations in lung tissue resulting from the application of topical hypothermia to the ischemic kidney. Although not statistically significant, a small reduction in lung levels of IL-1 β was also observed in animals subjected to hypothermic kidney ischemia. In addition, a strong correlation was found between intensity of hypothermia and lung TNF- α concentration, suggesting that the lower the temperature, the less intense the activation of the inflammatory cascade in lung tissues. IL-1 β levels also showed a trend toward significant correlation with the intensity of topical hypothermia, supporting the hypothesis that temperature reduction could attenuate the mechanisms involved in lung damage. These results are consistent with previous research which demonstrated that administration of specific TNF- α and IL-1 β inhibitors prevents I/R-related remote organ injury²²⁻²⁷. Furthermore, there is good evidence that agents which decrease distant lung injury after I/R also decrease pulmonary TNF- α ^{20,28,29}.

As the specific objective of this study was to compare lung damage between groups subjected to normothermic and hypothermic renal ischemia, it was decided that the absence of a sham group would not affect analysis or interpretation of results. A sham group would be of interest mainly to document the actual occurrence of lung injury following renal ischemia, which has already been clearly demonstrated by previous studies^{2,4,5,12,16,17,30}. In the present investigation, changes in lung parenchyma at 4 hours after a 40-minute period of renal ischemia were evaluated, and significant numbers of red blood cells were found in the interstitium and alveoli in all groups. However, there was no statistically significant difference between animals subjected to kidney ischemia under hypothermic or normothermic conditions. Similar findings were reported previously by our research group in a study of tissue protection by TRH, in which histologic attenuation of renal injuries was not observed¹⁰.

Kelly *et al.*¹⁷ noted that increased leukocyte infiltration in the heart, kidney, liver, and lungs already evident 6 hours after a 30-minute period of renal ischemia, as assessed by measurement of MPO activity in these systems. Similar findings were reported by Deng *et al.*¹⁶, who observed increased MPO activity in the kidney and lung four hours after a 40-minute period of renal ischemia. In the present study, where all animals were subjected to renal I/R, there was no significant difference in level of MPO activity among groups, regardless of the intensity of hypothermia during renal ischemia. These findings are consistent with the histopathological analysis, which did not demonstrate any protective effect.

Conclusions

Renal ischemia under topical hypothermic conditions results in decreased activation of the inflammatory cascade in lung tissue. However, topical renal hypothermia was not associated with any significant change in lung neutrophil infiltration rate or lung histological damage after renal ischemia and reperfusion.

References

1. Prado RA, Pereyra LHT, Lentsch AB, Ward PA. Ischemia/reperfusion injury. *J Surg Res.* 2002 Jun;105(2):248-58. PMID: 12125704.
2. Campanholle G, Landgraf RG, Gonçalves GM, Paiva VN, Martins JO, Wang PHM, Monteiro RMM, Silva RC, Cenedeze MA, Teixeira VPA, Reis MA, Silva AP, Jancar S, Camara NOS. Lung inflammation is induced by renal ischemia and reperfusion injury as part of the systemic inflammatory syndrome. *Inflamm Res.* 2010 Oct;59(10):861-9. PMID: 20396927.
3. El Sharif A, Awad AS. Curcumin immune-mediated and anti-apoptotic mechanism protect against renal ischemia/reperfusion and distant organ induced injuries. *Int Immunopharmacol.* 2011 Aug;11(8):992-6. PMID: 21354353.
4. Hoke TS, Douglas IS, Klein CL, He Z, Fang W, Thurman JM, Tao Y, Dursun B, Voelkel NF, Edelstein CL, Faubel S. Acute Renal Failure after bilateral nephrectomy is associated with cytokine mediated pulmonary injury. *J Am Soc Nephrol.* 2007 Jan;18(1):155-64. PMID: 17167117.
5. Kramer AA, Postler G, Salhab KF, Mendez C, Carey LC, Rabb H. Renal ischemia-reperfusion leads to macrophage mediated increase in pulmonary vascular permeability. *Kidney Int.* 1999 Jun;55(6):2362-7. PMID: 10354283.
6. Tang XN, Yenari MA. Hypothermia as a cytoprotective strategy in ischemic tissue injury. *Ageing Res Rev.* 2010 Jan;9(1):61-8. PMID: 19833233.
7. Grezzana Filho TJ, Mendonça TB, Gabiatti G, Kruel CD, Corso CO. Topical liver hypothermia and ischemic preconditioning: a new model of ischemia and reperfusion in rats. *Acta Cir Bras.* 2009 Jul-Aug;24(4):262-6. PMID: 19705024.
8. Patel S, Pachter HL, Yee H, Schwartz JD, Marcus SG, Shamamian P. Topical hepatic hypothermia attenuates pulmonary injury after hepatic ischemia and reperfusion. *J Am Coll Surg.* 2000 Dec;191(6):650-6. PMID: 11129814.
9. Santora RJ, Lie ML, Grigoryev DN, Nasir O, Moore FA, Hassoun HT. Therapeutic distant organ effects of regional hypothermia during mesenteric ischemia-reperfusion injury. *J Vasc Surg.* 2010 Oct;52(4):1003-14. PMID: 20678877.
10. Santos EB, Koff WJ, Grezzana Filho TJ, De Rossi SD, Treis L, Bona SR, Pêgas KL, Katz B, Meyer FS, Marroni NA, Corso CO. Oxidative stress evaluation of ischemia and reperfusion in kidneys under various degrees of hypothermia in rats. *Acta Cir Bras.* 2013 Aug;28(8):568-73. PMID: 23896835.
11. Bradley PP, Priebe DA, Christensen RD, Rothstein G. Measurement of cutaneous inflammation: estimation of neutrophil content with an enzyme marker. *J Invest Dermatol.* 1982 Mar;78(3):206-9. PMID: 6276474.
12. Hassoun HT, Lie ML, Grigoryev DN, Liu M, Tuder RM, Rabb H. Kidney ischemia-reperfusion injury induces caspase-dependent pulmonary apoptosis. *Am J Physiol Renal Physiol.* 2009 Jul;297(1):125-37. PMID: 19403643.
13. Ko GJ, Rabb H, Hassoun HT. Kidney-lung crosstalk in the critically ill patient. *Blood Purif.* 2009 Aug;28(2):75-83. PMID: 19439927.
14. Vieira JM Jr, Castro I, Curvello-Neto A, Demarzo S, Caruso P, Pastore L Jr, Imanishe MH, Abdulkader RC, Deheinzelin D. Effect of acute kidney injury on weaning from mechanical ventilation in critically ill patients. *Crit Care Med.* 2007 Jan;35(1):184-91. PMID: 17080002.
15. Yap SC, Lee HT. Acute kidney injury and extrarenal organ dysfunction: new concepts and experimental evidence. *Anesthesiology.* 2012 May;116(5):1139-48. PMID: 22415388.
16. Deng J, Hu X, Yuen PS, Star RA. Alpha-melanocyte-stimulating hormone inhibits lung injury after renal ischemia/reperfusion. *Am J Respir Crit Care Med.* 2004 Mar;169(6):749-56. PMID: 14711793.
17. Kelly KJ. Distant effects of experimental renal ischemia/reperfusion injury. *J Am Soc Nephrol.* 2003 Jun;14(6):1549-58. PMID: 12761255.
18. Meldrum KK, Meldrum DR, Meng X, Ao L, Harken AH. TNF-alpha dependent bilateral renal injury is induced by unilateral renal ischemia reperfusion. *Am J Physiol Heart Circ Physiol.* 2002 Feb;282(2):540-6. PMID: 11788401.
19. Springer TA. Traffic signals for lymphocyte recirculation and leukocyte emigration: the multistep paradigm. *Cell.* 1994 Jan;76(2):301-14. PMID: 7507411.
20. Gu J, Chen J, Xia P, Tao G, Zhao H, Ma D. Dexmedetomidine attenuates remote lung injury induced by renal ischemia-reperfusion in mice. *Acta Anaesthesiol Scand.* 2011 Nov;55(10):1272-8. PMID: 22092133.
21. Grezzana Filho TJ, Mendonça TB, Gabiatti G, Rodrigues G, Marroni NA, Treis L, De Rossi SD, Corso CO. Topical hepatic hypothermia plus ischemic preconditioning: analysis of bile flow and ischemic injuries after initial reperfusion in rats. *Acta Cir Bras.* 2011 Jun;26(3):194-201. PMID: 21537521.
22. Otani Y, Takeyoshi I, Koibuchi Y, Matsumoto K, Muramoto M, Morishita Y. The effect of FR167653 on pulmonary ischemia-reperfusion injury in rats. *J Heart Lung Transplant.* 2000 Apr;19(4):377-83. PMID: 10775819.
23. Esposito E, Mazzon E, Muia C, Meli R, Sessa E, Cuzzocrea S. Splanchnic ischemia and reperfusion injury is reduced by genetic or pharmacological inhibition of TNF-alpha. *J Leukoc Biol.* 2007 Apr;81(4):1032-43. PMID: 17210619.
24. Yamada T, Murase N, Maeda T, Ye Q, Sakamoto T, Terakura M, Starzl TE, Todo S. Protective Effect of TNF-alpha and IL-1beta Inhibitor FR167653 on Ischemia-Reperfusion Injury in Rat Small Intestinal Transplantation. *Transplant Proc.* 1998 Sep;30(6):2638. PMID: 9745524.
25. Seekamp A, Warren JS, Remick DG, Till GO, Ward PA. Requirements for tumor necrosis factor-alpha and interleukin-1 in

- limb ischemia/reperfusion injury and associated lung injury. *Am J Pathol.* 1993 Aug;143(2):453-63. PMID: 7688184.
26. Krishnadasan B, Naidu BV, Byrne K, Fraga C, Verrier ED, Mulligan MS. The role of proinflammatory cytokines in lung ischemia-reperfusion injury. *J Thorac Cardiovasc Surg.* 2003 Feb;125(2):261-72. PMID: 12579094.
 27. Colletti LM, Remick DG, Burtch GD, Kunkel SL, Strieter RM, Campbell DA Jr. Role of tumor necrosis factor-alpha in the pathophysiologic alterations after hepatic ischemia/reperfusion injury in the rat. *J Clin Invest.* 1990 Jun;85(6):1936-43. PMID: 2161433.
 28. Yoshidome H, Kato A, Edwards MJ, Lentsch AB. Interleukin-10 inhibits pulmonary NF-kappaB activation and lung injury induced by hepatic ischemia-reperfusion. *Am J Physiol.* 1999 Nov;277:919-23. PMID: 10564176.
 29. Yang J, Murphy C, Denham W, Botchkina G, Tracey KJ, Norman J. Evidence of a central role for p38 map kinase induction of tumor necrosis factor alpha in pancreatitis-associated pulmonary injury. *Surgery.* 1999 Aug;126(2):216-22. PMID: 10455887.
 30. Hassoun HT, Grigoryev DN, Lie ML, Liu M, Cheadle C, Tuder RM, Rabb H. Ischemic acute kidney injury induces a distant organ functional and genomic response distinguishable from bilateral nephrectomy. *Am J Physiol Renal Physiol.* 2007 Jul;293(1):30-40. PMID: 17327501.

Acknowledgements

To Marta Cioato, RN, of the HCPA Animal Experimentation Center, for her cooperation; and Department of Pathology and Laboratory of Physiology and Experimental Hepatology, HCPA.

Correspondence:

Carlos Otávio Corso
Hospital de Clínicas de Porto Alegre
Serviço de Cirurgia Geral
Rua Ramiro Barcelos, 2350
90035-903 Porto Alegre – RS Brasil
carloscorso04@gmail.com

Received: March 5, 2015

Review: May 10, 2015

Accepted: June 9, 2015

Conflict of interest: none

Financial source: Research and Event Incentive Fund, Hospital de Clínicas de Porto Alegre (FIPE-HCPA)

¹Research performed at Laboratory of Physiology and Experimental Pathology, Experimental Research Center (CPE), Hospital de Clínicas de Porto Alegre (HCPA), Universidade Federal do Rio Grande do Sul (UFRGS), Porto Alegre-RS, Brazil. Part of Master degree thesis, Postgraduate Program in Surgical Sciences, UFRGS. Tutor: Carlos Otávio Corso.