

## Healing of abdominal wall aponeurosis of rats after incision with either cold scalpel or electrocautery<sup>1</sup>

### Cicatrização da aponeurose abdominal de ratos com o uso do eletrocautério e bisturi de lâmina

Ademar Garcia<sup>2</sup>, José Eduardo Aguilar Nascimento<sup>3</sup>, Eduardo Mulinari Darold<sup>4</sup>, Rodolfo Edson de Franco Pimentel<sup>5</sup>, Eloísa Almeida Curvo<sup>6</sup>, Frederico Oliveira Daud<sup>6</sup>

1. Department of Surgery, University General Hospital (HGU), Cuiabá University (UNIC), Mato Grosso, Brazil.

2. Coordinator Medical Residency, General Surgery (HGU-UNIC), Mato Grosso, Brazil.

3. PhD, Chairman, Full Professor, Department of Surgery, Federal University of Mato Grosso, Brazil

4. MD, Surgery Resident (HGU-UNIC), Mato Grosso, Brazil.

5. MD, Staff Surgeon (HGU-UNIC), Mato Grosso, Brazil.

6. Medical Student (HGU-UNIC), Mato Grosso, Brazil.

---

#### ABSTRACT

**Purpose:** To compare the healing of abdominal wall aponeurosis of rats after incision with either cold scalpel or electrocautery. **Methods:** Twelve male adults Wistar inbred rats weightin 258-362g entered the experiment. They were randomly divided in two groups, control group (N= 6) and experimental group (N= 6). All animals underwent anesthesia followed abdominal wall incision with either cold scalpel (controls) or electrocautery (experimental group). The animals were killed on the 10<sup>th</sup> day and necropsied. Tissue samples containig the abdominal wall aponeurosis were sent for both histological study and hydroxyproline content assay. **Results:** The histological study showed no significant difference between the two groups. Hydroxiprolin content in experimenral group (128,56 [78,98-198,92] µg /100m) was not significantly different from control group (140,27 [116,20-166,59] µg /100ml; p = 0.53). **Conclusion:** Healing of abdominal wall after dieresis with either cold scalpel or electrocautery are equivalent and do not differ.

**Key Words:** Wound healing. Fascia. Laparotomy. Electrocautery.

---

#### RESUMO

**Objetivo:** Comparar a cicatrização da aponeurose abdominal de ratos submetidos à diereese com o uso de eletrocautério e de bisturi de lâmina. **Métodos:** Utilizou-se 12 ratos *Wistar*, machos, adultos, com peso entre 258-362g. Os animais foram divididos aleatoriamente em dois grupos: controle (N= 6) e experimental (N= 6). Sob anestesia parenteral, realizou-se no grupo controle a abertura da aponeurose abdominal utilizando-se o bisturi de lâmina e no experimental abertura com o uso do eletrocautério. Os animais foram sacrificados no 10<sup>o</sup> PO, a aponeurose foi ressecada e enviada para estudo histológico e dosagem de hidroxiprolina. **Resultados:** Não houve diferença na avaliação histológica entre os grupos. O conteúdo de hidroxiprolina no grupo experimental (128,56 [78,98-198,92] µg /100m) não foi diferente do grupo controle (140,27 [116,20-166,59] µg /100ml; p = 0.53). **Conclusão:** A cicatrização da aponeurose da parede abdominal de ratos submetidos à diereese com bisturi de lâmina e eletrocautério se equivalem e não diferem entre si.

**Descritores:** Cicatrização de feridas. Fásia. Laparotomia. Eletrocautério.

---

## Introduction

Diathermy has been widely used in all the types of operations either for dieresis or hemostasis. Although there is a quite long surgical experience with this instrument, it remains controversial whether diathermy for dieresis impairs or does not impair the healing process<sup>1,2,3</sup>. For some authors diathermy may promote greater inflammation and tissue necrosis than cold scalpel. Moreover, diathermy would induce increased formation of adhesions between the peritoneo along the incision and the gut<sup>4</sup>. Furthermore, some studies have shown significant reduction of wound tensile force and increase of the healing time with diathermy<sup>4,6</sup>. In opposition a randomized trial showed that scalpel and diathermy are equivalent, and the inflammatory reaction after opening the abdomen with diathermy would be of less important since the electrocautery by promoting dieresis and homeostasis at same time would reduce both operative time and bleeding<sup>7</sup>. Thus, literature present conflicting opinions on the use of the electric scalpel for incision purposes. This justify another revisit on the consequences of diathermy on the wound healing process. The aim of the present study was to investigate how the healing of abdominal aponeurosis is affect by either cold scalpel or electrocautery incision.

## Methods

Twelve male adults Wistar rats from the Universidade de Cuiabá Biotery weighting between 258 and 362 g entered the experiment. The study design foollowed the COBEA (Colegio Brasileiro de Experimentação Animal) guidelines. Rats were individually housed in standard stainless steel cages and fed with a standard rat chow (*Purina*<sup>®</sup>, Brazil) and were allowed to drink water *ad libitum* for five for adaptation in the laboratory environment. All animals received parenteral anesthesia with intramuscular dosis of Ketamine (15mg/kg) + Xylazine (5 mg/kg). The were fixed in the surgical board, and then submitted to trichotomy and antisepsis with 10% polyvinylpyrrolidone iodine. The abdomen was covered by a sterile surgical drape and then a midline laparotomy was performed involving both the skin and subcutaneous tissue with a 15 Fr. cold scalpel. The rats were then randomly divided in two groups: control group (N= 6) and experimental group (N= 6). Aponeurosis was opened with the same cold scalpel in control rats, and with electrocautery ("Medcir", Model BM-560, 100W, 110-220 Vç Brazil) in experimental group animals. Immediately after that, the abdominal aponeurosis was sutured with nylon 5.0 separated stitches. The skin was closed with continuous suture with the same thread. After recovering from anesthesia the rats were identified and returned to their original cages. They remained in their cages receiving water and standard chow *ad libidum* until the 10<sup>th</sup> postoperaive day when they were killed with an overdose of the same anesthetic drugs previously described.

During autopsy the skin of the abdominal wall was opened by an "U" incision to preserve the integrity of the aponeurosis. The sutured aponeurosis area was removed with 1 cm (0,39 in) free margin in lateral borders, and cut into two pieces. Half of the specimens was sent for histological study and the other half for total hydroxyproline assay. Histological slides of four micrometers thick were stained with hematoxiline and eosin and examined. Histological variables were based on previously report<sup>8</sup> as follows:

- *Inflammatory reaction*: categorized as intense (+++) when showed visible inflammatory cells infiltration on low optic microscopy magnification (10 X); moderate (++) when to the neutrophilus cells identification demanded optic magnification (100 X) and discrete (+) when necessary upper magnification (200 X);

- *Granulation tissue*: categorized as Type A when it was found large amount of fibroblasts into a scarce collagen matrix seen with difficulty under microscopy magnification of 10 X, and limited vascular formation. Type B – edematous granulation tissue, evidently visible with magnification of 10X, and great number of vases indicating accentuated neoangiogenesis.

- *Fibrosis and foreign body granulation tissue*: categorized as present or absent.

The Bergman and Loxley (1970) technique modified by Angeleli, Burini and Oliveira (1982) was used for hydroxyproline assayment. The basic steps of the assay can be resumed as follows: a) the frozen tissue was homogenized with 20 ml of cold distilled water using a tissue homogenizer (POLYTRON-KINEMATICA, type PT 10-35 USA); b) a volume of approximately 1,0 ml of the homogenate was hydrolyzed with 2 ml of concentrated HCl in drying machine on 110° degree during 24 hours, using glass duct covered with an emery hood; c) the samples were then cooled in natural temperature and mixed with one drop of 1% phenolphthalein alcohol solution. The product was then neutralized to pH 8,0 with saturated lithium hydroxide solution (LiOH), and the final volume was completed to 30 ml with distilled water, and then centrifuged in 3000 rpm during 30 minutes; d) the solution was diluted 5 times, and then 1 ml of it was oxidized with 0.7% chloramine T and Ehrlich (p-dimetil aminobenzaldehido) reagent was used for coloration. The results were read with spectrophotometer in 562 nm against the white. At the same time reaction with hydroxyproline criterion in 2 mg/ml of concentration was realized in order to calculate the hydroxyproline rate tissue. Hydroxiprolin content data was compared between groups with the Mann-Whitney test. A 5% ( $p \leq 0,05$ ) level was establish to reject the nullity hypothesis.

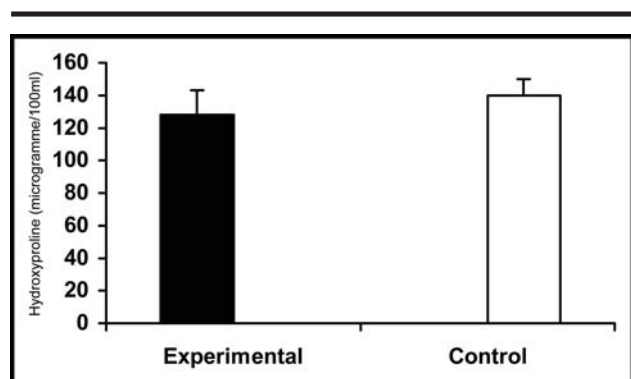
## Results

No death occurred in the two groups. Both groups showed intense to moderate inflammatory reaction with a trend to be more intense in experimental group. The presence of fibrosis, foreign body granulation tissue, and

type A granulation was found in all animals of both groups (Table 1). The content of hydroxyproline in experimental group (128,56 [78,98-198,92] µg/100ml) was not significantly different from controls (140,27 [116,20-166,59] µg/100ml ;  $p = .58$ ) (Figure 1).

**TABLE 1** - Histological parameters in the two groups

Rat	Group	Inflammatory Reaction	Granulation Type	Fibrosis	Granuloma Present
01	Experimental	+++	Type A	Present	Present
02	Experimental	+++	Type A	Present	Present
03	Experimental	++	Type A	Present	Present
04	Experimental	++	Type A	Present	Present
05	Experimental	+++	Type A	Present	Present
06	Experimental	+++	Type A	Present	Present
07	Control	+++	Type A	Present	Present
08	Control	++	Type A	Present	Present
09	Control	++	Type A	Present	Present
10	Control	++	Type A	Present	Present
11	Control	++	Type A	Present	Present
12	Control	++	Type A	Present	Present



**FIGURE 1** - Hydroxyproline content (microgramme/100ml) in the two groups ( $p=0.58$ ).

## Discussion

Dieresis and synthesis are routine surgical procedures and the correct comprehension of the healing process is of great importance, since disturbance on the normal evolution of wound repair may represent a serious clinical problem with significant morbidity and mortality<sup>1</sup>. The main focus of the present study was to compare the healing process after using either diathermy or scapel to open the abdominal aponeurosis. As far as we could analyse the overall findings, we verified that both techniques are comparale. A number of authors have reported the effects of the electrocautery in the evolution of the healing process<sup>1,3,4,11,12</sup>. Pollinger et al<sup>13</sup> have analyzed wound healing after the use of either cold scalpel or electrocautery in pigs. They performed

incisions at the intestine, uterus, and the skin and reported, by histological parameters, a delayed healing at the 3<sup>rd</sup>, 7<sup>th</sup>, and 14<sup>th</sup> postoperative days in the group submitted to cold scalpel. Other experimental studies using animals showed that the use of electrocautery, instead of cold scalpel, to incise the abdomen, did not alter the wound healing process<sup>14,15,16</sup> and some of these studies showed that the use of electrocautery is even better due to enhanced control of bleeding and a shorter operative time<sup>12,17,18,19,20</sup>. Ziv et al<sup>20</sup> have performed median laparotomy in 60 rats, randomizing them in 2 groups (cold scalpel or electrocautery). The fascia and skin incision were closed separately using continue suture with nylon. Analyzing mechanical properties of fascia segments 6 days after surgery they found no significant difference between the two groups. In a clinical study, Kearns et al<sup>5</sup> compared the results from the incision performed with either electrocautery or cold scalpel in 100 patients. They showed that patients receiving electrocautery incision had faster healing, less important bleeding, and minimal pain postoperatively. In the present work the histological study showed similar inflammatory reaction in both experimental and control group. The concentration of hydroxyproline was slightly higher in the experimental group, but without statistical significance. Thus the overall results showed similar behavior of the groups at the 10<sup>th</sup> postoperative day. Considering the large utilization of electrocautery as an instrument for aponeurosis incision in different types of surgery and the conflicting results about its use in the available publications we consider that the results of this work will increase the discussion on

this issue, and at the same time, will stimulate more experimental studies using other parameters to study the healing process.

### Conclusion

The findings of our study suggest that the abdominal aponeurotic healing after diuresis using cold scalpel and electrocautery are equivalent.

### References

1. Phillips LG. Cicatrização das Feridas. In: Townsend CM, Beauchamp RD, Evers BM, Mattox KL. Sabiston Tratado de Cirurgia. 16ed. Rio de Janeiro: Guanabara Koogan; 2003. p139-53.
2. Gallup DG. Opening and closing of the abdomen and wound healing. In: DM Gershenson, AH DeCherney and SL Curry. Operative gynecology. 1ed. Philadelphia: WB Saunders; 1993. p 127-46.
3. Chrysos E, Athanasakis E, Antonakakis S, Xynos E, Zoras O. A prospective study comparing diathermy and scalpel incisions in tension-free inguinal hernioplasty. *Am Surg.* 2005; 71(4):326-9.
4. Rappaport WD, Hunter GC, Allen R, Lick S, Halldorsson A, Chvapil T, Holcomb M, Chvapil M. Effect of electrocautery on wound healing in midline laparotomy incisions. *Am J Surg.* 1990; 160(6):618-20.
5. Kearns SR, Connolly EM, McNally S, McNamara DA, Deasy J. Randomized clinical trial of diathermy versus scalpel incision in elective midline laparotomy. *Br J Surg.* 2001; 88(4):41-4.
6. Liboon J, Funkhouser W, Terris DJ. A comparison of mucosal incisions made by scalpel, CO2 laser, electrocautery, and constant-voltage electrocautery. *Arch Otolaryngol Head Neck Surg.* 1997; 116:379-85.
7. Ji G, Wu Y, Wang X, Pan H, Li P, Du W, Qi Z, Huang A, Zhang L, Zhang L, Chen W, Liu G, Xu H, Li Q, Yuan A, He X, Mei G. Influence of high-frequency electric surgical knife on healing of abdominal incision, experimental and clinical studies. *World J Gastroenterol.* 2006; 12:4082-5.
8. Biondo-Simões MLP, Alcantara EM, Dallagnol JC, Yoshizumi KO, Torres LFB, Borsato KS. Cicatrização de feridas: Estudo comparativo em ratos hipertensos não tratados e tratados com inibidor da enzima conversora da angiotensina. *Rev Col Bras Cir.* 2006; 33(2):74-8.
9. Bergman I, Loxley R. The determination of hidroxiprolina in urine hydrolyses. *Clin Chim Acta.* 1970; 27:347-9.
10. Angeleli AYO, Burini RC, Oliveira JED. Padronização da metodologia para determinação das frações da hidroxiprolina urinária. *Rev Bras Pat Clin.* 1982; 18:124-7.
11. Rappaport WD, Allen R, Lick S. Effect of electrocautery on wound healing in midline laparotomy incisions. *Am J Surg.* 1990; 160(6):618-20.
12. Lawrenson KB, Stephens FO. The use of electrocuting and electrocoagulation in surgery. *Aust NZ J Surg.* 1970; 39:417-21.
13. Pollinger HS, Mostafa G, Harold KL, Austin CE, Kercher KW, Matthews BD. Comparison of wound-healing characteristics with feedback circuit electrosurgical generators in a porcine model. *Am Surg.* 2003; 69(12):1054-60.
14. Kumagai SG, Rosales RF, Hunter GC, Rappaport WD, Witzke DB, Chvapil TA, Chvapil M, Sutherland JC. Effects of electrocautery on midline laparotomy wound infection. *Am J Surg.* 1991; 162(6):620-2.
15. Aydos RD, Magalhães AM, Filhoz JFM, Barone B, Goldenberg S. Efeitos da diatermia cirúrgica na cicatrização de anastomoses do intestino grosso. Estudo experimental em coelhos - *Acta Cir Bras.* 1994; 9(4):190-4.
16. Soballe PW, Nimbkar NV, Hayward I, Nielsen TB, Drucker WR. Electric cautery lowers the contamination threshold for infection of laparotomies. *Am J Surg.* 2001; 181(4):384-5.
17. Pearce J. Current electrosurgical practice: hazards. *J Med Eng Technol.* 1985; 20:320-6.
18. Lanzafame RJ. The effect of lasers, electrocautery and sharp dissection on cutaneous flaps. *Plast Reconstr Surg.* 1996; 97(2):487-8.
19. Allan SN, Spitz L, Noort RV, Black MM. A comparative study of scalpel and electrosurgical incision on subsequent wound healing. *J Pediatr Surg.* 1982; 17:52-4.
20. Johnson CD, Serpell JW. Wound infection after abdominal incision with scalpel or diathermy. *Br J Surg.* 1990; 77(6):626-7.
21. Ziv Y, Brosh T, Lushkov G, Halevy A. Effect of Electrocautery vs. Scalpel on Fascial Mechanical Properties after Midline Laparotomy Incision in Rats. *IMAJ.* 2001; 3:566-8.

---

### Correspondence:

Ademar Garcia  
HU Julio Muller  
Av. L Bairro Alvorada  
e-mail: [ag1@terra.com.br](mailto:ag1@terra.com.br)  
Tel/Fax: 65 36157398

Conflito de interesse: nenhum  
Fonte de financiamento: nenhuma