

## Diclofenac sodium and Imipenem action on rat intestinal mucosa. A biomechanical and histological study<sup>1</sup>

Ação do Diclofenaco de sódio e Imipenem na mucosa intestinal do rato.  
Estudo biomecânico e histológico

Irio Gonçalves Junior<sup>I</sup>, Luiz Eduardo Naresse<sup>II</sup>, Maria Aparecida Marchesan Rodrigues<sup>III</sup>, Shoiti Kobayasi<sup>IV</sup>

<sup>I</sup>Assistant Professor, Department of Surgery and Orthopedics, Gastroenterological Surgery, Botucatu Medical School, UNESP, Brazil. Study design, sample collection, manuscript writing.

<sup>II</sup>Associate Professor, Department of Surgery and Orthopedics, Gastroenterological Surgery, Botucatu Medical School, UNESP, Brazil. Helped supervise the study, study design, manuscript writing.

<sup>III</sup>Full Professor, Department of Pathology, Botucatu Medical School, UNESP, Brazil. Histopathological analysis, data interpretation.

<sup>IV</sup>Full Professor, Department of Surgery and Orthopedics, Gastroenterological Surgery, Botucatu Medical School, UNESP. Study supervision and design, final approval of manuscript.

---

### ABSTRACT

**PURPOSE:** To study diclofenac sodium induced histological and mechanical alterations and their prevention with Imipenem in rat intestine.

**METHODS:** Male Wistar rats (n=240) were randomly assigned to four experimental groups: GI: n=60 treated with 0.9% saline IM; GII: n=60 treated with 6mg/kg body weight diclofenac sodium IM for four days; GIII: n=60 treated with 30mg/kg body weight Imipenem IM for four days, and GIV n=60 treated with diclofenac sodium plus Imipenem at the above doses IM for 4 days. Each group was further divided into 4 subgroups of 15 rats each and sacrificed at 4, 7, 14, and 21 days of follow-up, respectively. Abdominal cavity macroscopy and histology, and small bowel breaking strength were analyzed at each sacrifice moment.

**RESULTS:** There were no histological or mechanical alterations in normal control rats throughout the study. Ulcerated lesions in intestinal mucosa were observed and breaking strength decreased in all diclofenac sodium treated rats. Ulcerated lesions in intestinal mucosa were prevented by Imipenem in all rats. **CONCLUSION:** Diclofenac sodium induced ulcerated lesions in rat intestinal mucosa can be prevented by Imipenem treatment.

**Key words:** Diclofenac. Imipenem. Intestine, Small. Ulcer. Rats.

---

### RESUMO

**OBJETIVO:** Avaliar as alterações histológicas e biomecânicas do diclofenaco de sódio na mucosa intestinal do rato e a associação com o uso de Imipenem.

**MÉTODOS:** Foram estudados 240 ratos Wistar distribuídos aleatoriamente em quatro grupos experimentais: GI: 60 ratos tratados com injeção IM de soro fisiológico 0,9%; GII: 60 ratos tratados com injeção IM de diclofenaco de sódio na dose de 6mg/kg de peso por 4 dias; GIII: 60 ratos tratados com injeção IM de Imipenem na dose de 30 mg/kg de peso por 4 dias; GIV: 60 ratos tratados com injeção IM de soro fisiológico e diclofenaco de sódio nas doses acima. Em cada grupo os animais foram posteriormente divididos em 4 momentos de 15 animais em cada um para sacrifício, respectivamente, no 4º, 7º, 14º e 21º dias após o início do tratamento. As alterações da cavidade abdominal, assim como as características histológicas e de força de ruptura do intestino delgado foram analisadas em cada momento, em cada grupo.

**RESULTADOS:** Não foram encontradas alterações histológicas e biomecânicas nos animais do Grupo I nesse estudo. Lesões ulceradas na mucosa do intestino delgado foram observadas nos animais tratados com diclofenaco de sódio, assim como diminuição da força de ruptura. As lesões ulceradas encontradas foram prevenidas pelo uso de Imipenem.

**CONCLUSÃO:** O diclofenaco de sódio induz lesões ulceradas na mucosa intestinal do rato que podem ser prevenidas pelo uso de Imipenem.

**Descritores:** Diclofenaco. Imipenem. Intestino Delgado. Úlcera. Ratos.

---

**Introduction**

Detailed study of the inflammatory process has permitted the development of a medication group generically referred to as non-steroid anti-inflammatory drugs (NSAIDs), which have the specific function of blocking the inflammatory process cascade and consequently reduce pain intensity<sup>1</sup>. Diclofenac sodium (DS) is one NSAID that acts on the arachidonic acid cascade inhibiting prostaglandin biosynthesis, and is one of most commonly used drugs in experimental and clinical investigations<sup>2</sup>.

Patients who make long-term use of NSAIDs can develop inflammatory processes, stenosis, and ulcers (non- or perforated) in the small intestine or colon<sup>3</sup>. However, the mechanism(s) responsible for these alterations is still not fully understood<sup>4</sup>.

NSAIDs are used after surgery as preventive (before surgical incision) or therapeutic (after anaesthesia effect) analgesics and anti-inflammatories aiming to block the liberation of substances that change the excitation threshold in peripheral nociceptors and alleviate moderate or mild intensity pain<sup>5</sup>. However, these drugs also have undesirable side effects, such as intestinal anastomosis rupture. Clinical and experimental findings have also shown that NSAIDs can provoke ulcers in intestinal mucosa in locations without anastomosis, which can evolve to perforation<sup>6</sup>. Although the exact etiopathogenicity of these intestinal mucosa lesions is not fully known, NSAIDs probably facilitate intercellular junction breaks thus favouring bacteria translocation<sup>7</sup>.

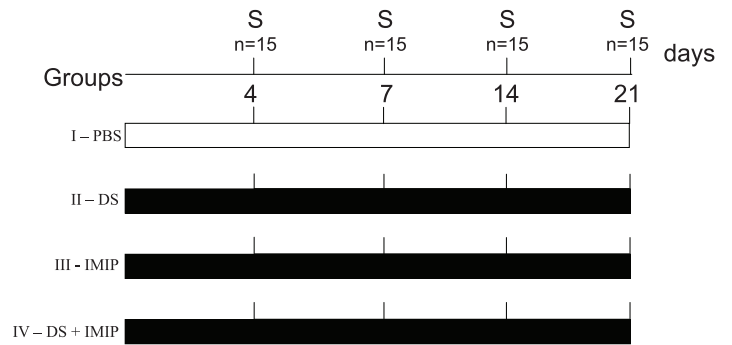
The line of research followed by our group is to find explanations for probable modulating factors which affect intestinal healing, using non-anastomosis rats to simulate the adverse conditions found in clinical practice. This type of investigation attempts to find new ways of avoiding possible NSAID complications<sup>2</sup>.

Due to the increasing use of DS after surgery and in an effort to obtain more information on how DS acts on intestinal mucosa lesions and their prevention, the aim of our study was to evaluate small intestine lesions induced by DS, their evolution and biomechanical alterations – rupture force of the small intestine distal portion, and to verify whether antibiotics (Imipenem) prevent their formation.

**Methods**

Two month old male Wistar rats (n=240) with 190g mean weight were randomly distributed into four groups, as follows: Group I: n=60, received one daily application of 0.5mL 0.9% SF

by intramuscular route (IM); Group II: n=60, received one daily 6mg/kg body weight dose of diclofenac sodium by IM; Group III: n=60, received 12 hourly applications of 30mg/kg body weight doses of Imipenem by IM; and Group IV: n=60, received one daily 6mg/kg body weight dose of diclofenac sodium and 12 hourly applications of 30mg/kg body weight doses of Imipenem by IM. In all groups, treatments were applied over 4 consecutive days. Figure 1 shows the experimental design



**FIGURE 1** - Experimental design. S = sacrifice, PBS = phosphate buffered saline (physiological solution), n = number of animals, IMIP = Imipenem, DS = Diclofenac sodium.

At each time point (4, 7, 14 and 21 days), 15 rats underwent macroscopic study of the abdominal cavity and terminal ileum, rupture force, and histological examination of ileum fragments, which were 10cm distant from the ileocaecal valve.

From each animal, a 3cm and 2cm segment were removed from the ileum terminal and immediately placed in PBS with 250mg/mL papaverine chloride at 37°C for 30min. In sequence, rupture force of these segments was measured. Distal ileum fragments (0.5cm) were used for histopathology. These fragments were opened from the contramesenterial side, with the mucosa face extended on filter paper and immersed in 10% formalin solution. Following this procedure, samples from the large omentum, large and small intestine, liver anterior lobe, and spleen were taken. Samples were fixed by immersion in 10% formalin solution for 72h. Samples were cut and processed by standard histological methods, and stained with Hematoxylin-Eosin, when necessary, using the GRAM technique. A specially designed apparatus was used to study intestinal segment rupture force.

Slides were analyzed by standard optical microscope to identify visible morphological changes. Histological parameters adopted after previous analysis of the material were: ulcerated lesion in intestinal mucosa; neutrophilic exudate in the submucosa and muscle layer, in addition to edema, responsible for the latter's dissociation; bacteria, or fecal and food remnants in lesions; epiploon block in mucosa corresponding to mucosa lesion, as well

as evaluating inflammatory infiltrates, and finally if there was any mucosa regeneration on the ulcerated lesions. Intestinal segment rupture force means and standard deviations were calculated for each group.

Factorial analysis of variance for completely random experiments was used to evaluate the following hypotheses:

- 1) Interaction between antibiotic and anti-inflammatory on each evaluation day;
- 2) Anti-inflammatory effect;
- 3) Antibiotic effect;
- 4) The time effect in each of the four groups.

The following statistics were calculated in each hypothesis tested: F and p (p=probability of erroneous conclusion by significance). Effects were considered significant when  $p < 0.05$ . In these cases differences between pairs of means were made by calculating the minimum significant difference for  $\alpha = 0.05$ , by Tukey's method.

## Results

No deaths occurred in any group. Only GII animals presented reduced food ingestion, diarrhoea, and weight loss up to 7th day of the experiment. From this time on, a gradual weight gain was seen, with animals recovering on the 21<sup>st</sup> day of follow-up. There were no significant clinical alterations in any rats from the other groups.

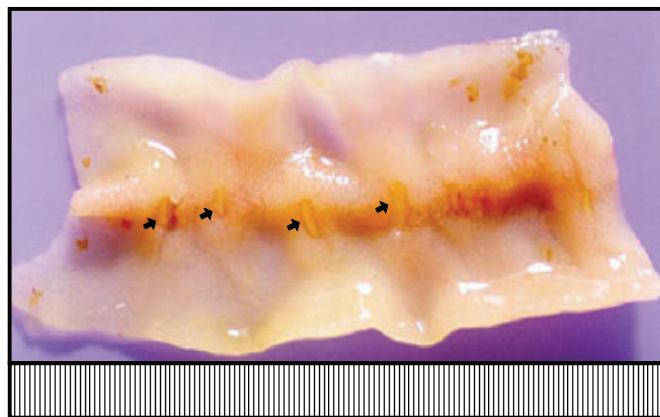
Macroscopic evaluation of the abdominal cavity revealed no peritonitis, blocks, adhesions, abscesses, or mucosal lesions in GI, II, or IV animals.

Macroscopic findings in GII varied according to sacrifice time: on the 4th day, all animals presented about 3mm diameter, non confluent, profound, round or linear aspect ulcerated lesions mainly in the terminal ileum (Figure 2). Some presented discrete block of the large omentum in serosa corresponding to mucosal lesion; on the 7th day, the number, diameter, and depth of these ulcerated lesions were reduced, but in some pieces there was still discrete large omentum adherence to serosa in the area corresponding to the mucosal lesion; on the 15th and 21st day both the abdominal cavity and intestinal flap macroscopic aspects were normal. The other groups did not present alterations (Figure 3).

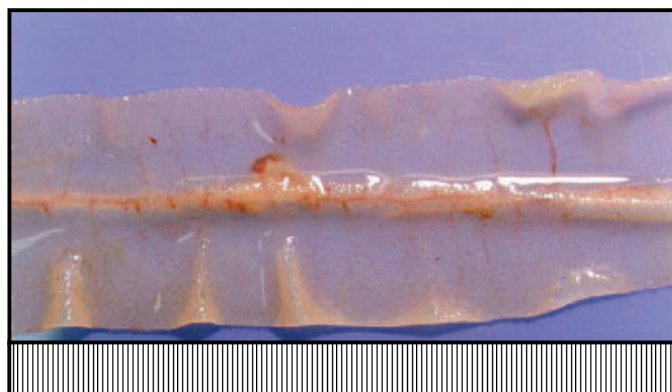
Histopathological examination of intestine fragments from GIII and GIV animals (AB, AB + AI) did not differ to GI (control). In contrast, analysis of intestine segments from GII on day 4 showed extensive deep focal ulcerated lesions, with a crust of necrotic material and exuberant bacteria colonization

affecting all layers. Below the ulcerated lesions, there was abundant inflammatory infiltrate, predominantly neutrophils and edema, disassociating the adjacent muscle layer. In the serosa corresponding to mucosal ulceration, there was adherence to the large omentum with vascular neof ormation, edema, fibroblast proliferation, and the same type of inflammatory infiltration seen in the submucosa. There was perforation and grand omentum block where lesions were deeper.

On day 7 ulcerated lesions were smaller than of day 4 with single layer epithelial regeneration recovering nearly all lesion. Under this area inflammatory infiltrate could be seen with a predominance of macrophages, granulation tissue, and newly formed vessels. In the serosa corresponding to mucosal ulceration, there was adherence to the large omentum with the same type of inflammatory infiltrate as day 4.



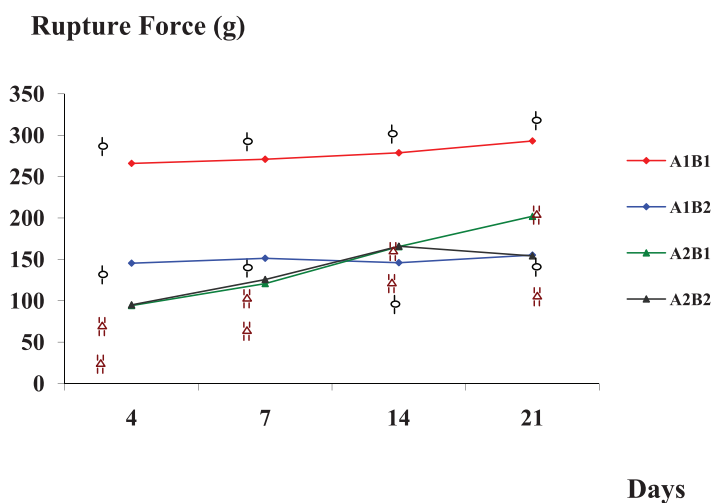
**FIGURE 2** - Group II – Day 4. Mucosal side of the small intestine with ulcerated lesions in the mesenterial border.



**FIGURE 3** - Group IV – Day 4. Absence of lesions or scar areas.

There was also granulation tissue, newly formed vessels and a large reduction in edema in relation to that seen in adhesions from the fifth day. On Days 14 and 21 no lesions were found in animal intestine mucosa.

Figure 4 shows data from the rupture force study. There is statistical difference between groups A1B1 and A1B2. There is interaction between the use of anti-inflammatory and antibiotic ( $p < 0.001$ ), as shown in groups A2B1 and A2B2.



**FIGURE 4** - Evolution of mean rupture force in experimental groups: A1 without anti-inflammatory, A2 with anti-inflammatory, B1 without antibiotic, and B2 with antibiotic.

## Discussion

Although structurally different, NSAIDs seem to have a similar action mechanism. Cyclooxygenase block with consequent inhibition of prostaglandin synthesis seems to be their common denominator. Apart from the beneficial aspect of treating pain, NSAIDs have a series of side effects, which mainly manifest in the digestive tract; the important ones being gastroduodenal hemorrhagic lesions<sup>8</sup>, visceral organ perforations<sup>8</sup>, changes in intestinal permeability<sup>8</sup>, and multiple stenosis in the small intestine<sup>8</sup>. Necropsy studies<sup>9</sup> have shown that 8.4% of patients with a history of chronic NSAID ingestion have non-specific ulceration in the intestinal mucosa.

In this study, ulcerated lesions were seen in the mesenterial border of intestinal mucosa of rats who received DS for 4 days. The anterior lesions were more intense and deeper on day 4, becoming smaller on day 7 with consolidated scar tissue around day 14. Ulcerated lesions were not seen in the other groups. These results suggest that DS was responsible for the formation of ulcerated lesions in intestinal mucosa.

The fact that some of these lesions compromised the serosa layer showed that they can evolve to perforation and consequently peritonitis; this probably did not occur as DS was suspended on day 4. Despite ulcerated lesions being seen in intestinal mucosa, they were not found in gastric mucosa; we were unable to

explain the mechanism behind this, which is also unexplained in the literature<sup>10</sup>. One theory is enterohepatic circulation, which can more easily appear with some anti-inflammatories from the NSAID group<sup>11</sup>.

Preferential distribution of lesions on the mesenterial side of the intestinal wall could suggest that the positioning of blood and lymphatic vessels in this area has some importance in the genesis of these lesions. However, optical microscopic examination did not reveal alterations, which might explain its etiopathogenesis.

In contrast, ulcerated lesions in the intestinal mucosa did not occur in animals who received DS together with the antibiotic, showing that Imipenem efficiently prevented them.

Primordial action from antibiotic treatment seems to really be linked with its bactericide function and consequently the reduction in bacteria translocation. In addition, intestinal protection occurs by the physical-chemical intestinal blood flow effect, epithelial covering, and by the immune system with the purpose of avoiding bacteria translocation<sup>11</sup>.

Maintaining normal intestinal flora is also responsible for maintaining normal dynamic equilibrium between the mucosa barrier and intestinal bacteria. This justifies the importance of maintaining both the quantity and quality of intestinal flora and adequate functioning of the intestinal barrier<sup>12</sup>.

The basic action of NSAIDs, due to their phospholipase A inhibition properties, is to impede formation of arachidonic acid with consequent reduction in prostaglandin and leukotriene synthesis. The inhibition cascade under normal conditions influences intestine microcirculation and consequently tissue oxidation with repercussions for cell renewal<sup>13</sup>. This could be one of the mechanisms which explain how NSAIDs slow down intestinal healing with a consequent rise in intestinal dehiscence index.

The initial lesion from NSAIDs in the mucosal barrier is triggered by a physical-chemical action, which is sufficient to propitiate bacteria translocation<sup>14</sup>. The joint action of these phenomena may provide an increase in bacteria population or qualitative alterations in their composition with consequent aggravation of bacteria translocation, initially favoured by NSAID action. The complexity of these phenomena can be analyzed when studying the functions of intestinal mucosa. Within these functions, intestinal permeability is responsible for the passage of molecules through a non-mediated diffusion mechanism, according to a pressure or concentration gradient, without help from a biochemical charging system<sup>14</sup>. This type of mechanism allows passage of antigens to the lymphatic system and important



macromolecules for organic system development. On the other hand, there could be increased permeability due to intestinal mucosa lesion, which here could have an infectious, toxic, or pharmacological character. Some of these macromolecules can be pathogenic to the organism, as with endotoxins or allergens.

It is important to stress that the permeability and absorption mechanisms are different, as an increase in permeability does not necessarily imply higher absorption. This can be seen in celiac diseases where increased mucosa permeability coexists with situations of inadequate absorption.

The initial breach point of NSAID lesions in the mucosa barrier is still unknown due to the plurality of their action mechanism. Therefore, the initial lesion may correspond to just one physical-chemical change which provides an access for previously blocked ions by similarity in load polarity. The intercellular junction could potentially be the first to be affected due to its susceptibility to different nocive stimuli. There is also evidence that intercellular junctions are the first organelles to suffer when supplied with insufficient energy<sup>14</sup>.

In 1999, Verderese<sup>14</sup> showed, by electron microscopy that the intercellular junction in small intestine was opened in DS rats. However, no bacterias have been seen in that part, but they trespassing the intestinal barrier through the enterocyte. Probably other mechanisms may lead this passage. On the other hand, contact from bacteria and consequently their toxins can damage or destroy the enterocyte in a process that can overtake the regenerative capacity of intestinal mucosa, leading to the formation of an ulcerated lesion.

Initial bacteria passage also seems to be related to a bacteria's ability to adhere to intestinal mucous<sup>14</sup>. Systemic action by NSAIDs allows their activation in the physical-chemical permeability of the intestinal barrier, which just like the liposaccharide framework of bacteria, is a phenomenon which can allow bacteria fixation in the intestinal mucosa and consequently their passage.

One of the objectives of this study was to observe whether events leading to intestinal mucosa lesion can be blocked by antibiotic treatment. Normal intestine flora contains a stable population of more than 500 bacteria species. This population provides a dynamic balance between host physiology and nutritional activity, actively participating in preventing bacteria translocation<sup>14</sup>.

One hypothesis is that the quantitative and qualitative stability of intestinal flora is responsible for the mucosa's resistance to colonisation by exogenous microorganisms. Also the bactericide or bacteriostasis activity of an antibiotic on a specific

group of bacteria could be a paradoxical effect in bacteria passage. In this way dynamic intestinal flora equilibrium is established by anaerobic bacteria and also by another group of bacteria<sup>14</sup>. The specific or damage action of the antibiotic on this group of bacteria can favour intestinal colonisation and extra-intestinal dissemination of bacteria such as *Escherichia coli*.

The effect of Imipenem, a wide spectrum bactericide antibiotic, has been seen on gram positive and gram negative bacteria, as well as *Bacteroides fragilis* and other bacteroides species<sup>14</sup>. Imipenem can lead to a uniform quantitative reduction in bacterial flora without a qualitative reduction or increase that could favour bacterial passage.

The absence of lesions in the group of animals receiving NSAIDs and Imipenem suggests that together they provided effective protection for the intestinal mucosa against developing an ulcerated lesion. One can thus conclude that DS used under our experimental conditions leads to the formation of ulcerated lesions, which heal 17 days after suspending the anti-inflammatory. Imipenem administered in conjunction with DS avoided the formation of DS induced ulcerated lesions in intestinal mucosa.

One of the important parameters that can reflect the intensity of tissue lesion is linked to alterations in the mechanical properties of the intestinal flap. Measuring mechanical resistance using rupture force has been used in our area to evaluate intestine healing evolution<sup>15</sup>. Earlier published works have evaluated the mechanical resistance of the intestinal flap from animals which have not undergone surgery. For this reason low mechanical resistance values obtained between day 4 and 7 could be indicative of increased intestinal flap collagen lysis. This was seen in all DS and Imipenem treated groups.

Intestinal flap mechanical resistance on day 4 and 7 was about 45% lower than controls. This suggests that, as well as having induced ulcerated lesion in the mucosa, DS or bacteria passage<sup>14</sup> had also caused submucosal lesion, the site of highest collagen concentration.

Low mechanical resistance in animals treated with Imipenem only was unexpected. Even though we did not see lesions in macro and microscopic exams that could explain this significant drop in resistance, the results suggest that changes did occur in collagen tissue. More studies are required to explain these findings, discarding the possibility of bacterial passage or increased collagen lysis.

The group that received combined DS and Imipenem also presented an accentuated drop in mechanical resistance. This demonstrates that, although Imipenem prevented the formation of DS induced lesions, it paradoxically did not occur with mechanical

resistance.

### Conclusions

Diclofenac sodium induced ulcerated lesions in rat intestinal mucosa can be prevented by Imipenem treatment.

Diclofenac sodium, Imipenem, or both reduce intestine wall mechanical resistance.

### References

1. Agrawal NM. Anti-inflammatories and gastroduodenal damage: therapeutic options. *Eur J Rheumatol Inflamm.* 1993;13:17-24.
2. Verderese LRM, Naresse LE, Leite CVS, Lucchiari PH, Kobayasi S. Action of diclofenac sodium on the small intestine of the rat after interruption of fecal peritonitis: study of breaking strength and of tissue collagen concentration. *Acta Cir Bras.* 1995;10:117-21.
3. Faucheron JL, Parc R. Nonsteroidal anti-inflammatory drug-induced colitis. *Int J Colorectal Dis.* 1996;11:99-101.
4. Bjorkman DJ. Nonsteroidal anti-inflammatory drug-induced gastrointestinal injury. *Am J Med.* 1996;101:25-32.
5. Hirschowitz BI. Nonsteroidal anti-inflammatory drugs and the gut. *South Med J* 1996;89:259-63.
6. Knouchi T, Kataoka K, Bing SR, Nakayama H, Uejima M, Shimono K, Kunahara T, Akimoto S, Hiroloka I, Ohnishi Y. Culture supernatants of *Lactobacillus acidophilus* and *Bifidobacterium adolescentis* repress ileal ulcer formation in rats treated with a nonsteroidal anti-inflammatory drug by suppressing unbalanced growth of aerobic bacteria and lipid peroxidation. *Microbiol Immunol.* 1998;45:347-55.
7. Georgopoulos A, Feistauer SM, Makristathis A, Burgmann H, Laggner AN. Influence of stress ulcer prophylaxis on translocation of bacteria from the intestinal tract in rats. *Wien Klin Wochenschr.* 1996;108:321-5.
8. Graham DY. The relationship between nonsteroidal anti-inflammatory drug use and peptic ulcer. *Gastroenterol Clin North Am.* 1990;19:171-82.
9. Allison MC, Howatson AG, Torrance CJ, Lee FD, Russel RI. Gastrointestinal damage associated with the use of nonsteroidal anti-inflammatory drugs. *N Engl J Med.* 1992;327:749-54.
10. Kent TH, Cadelli RM, Stamler FW. Small intestinal ulcers and intestinal flora in rats given indomethacin. *Am J Pathol.* 1989;54:237-49.
11. Reuter BK, Davies NM, Wallace JL. Nonsteroidal anti-inflammatory drug enteropathy in rats: role of permeability, bacteria, and enterohepatic circulation. *Gastroenterology.* 1997;112:109-17.
12. Somasundaram S, Rafi S, Hayllar J, Sigthorsson G, Jacob M, Price AB, Macpherson A, Mahmood T, Scott Dwriggles Worth TM, Bjarnason I. Mitochondrial damage: a possible mechanism of the "topical" phase of NSAID induced injury to the rat intestine. *Gut.* 1997;41:344-53.
13. Uribe A, Alam M, Midtuet T. E2 prostaglandins modulate cell proliferation in the small intestinal epithelium of the rat. *Digestion.* 1992;52:157-64.
14. Verderese LRM. A influência do diclofenaco de sódio na peritonite bacteriana, tratada com lavagem da cavidade peritonial e gentamicina. Estudo da translocação bacteriana [Tese]. Botucatu: Faculdade de Medicina, Universidade Estadual Paulista; 1999.
15. Naresse LE, Mendes EF, Curi PR, Lucchiari P, Kobayasi S. Aparelho para medida da força de ruptura das anastomoses intestinais. *Rev Hosp Clin Fac Med São Paulo.* 1987;42:204-8.

16. Katayama M, Xu D, Specian RD, Deztch EA. Role of bacterial adherence and the mucus barrier on bacterial translocation: effects of protein malnutrition and endotoxin in rats. *Ann Surg.* 1997;225:317-26.
17. Wells CL, Maddaus MA, Jcchorek RP, Simmons RL. Role of intestinal anaerobic bacteria in colonization resistance. *Eur J Clin Microbiol Infect Dis.* 1988;7:107-12.
18. Klietmann W, Focht J, Nosner K. Antibacterial effect of imipenem in vitro against important aerobic and anaerobic strains isolated from clinical specimens. *Chemioterapia.* 1987;6:243-50.

---

### Correspondence:

Luiz Eduardo Naresse  
Faculdade de Medicina de Botucatu  
Departamento de Cirurgia e Ortopedia  
Distrito de Rubião Junior, s/n  
18618-970 Botucatu – SP Brasil  
Tel.: (55 14)3811-6269  
naresse@fmb.unesp.br

Received: September 14, 2011

Review: November 16, 2011

Accepted: December 12, 2011

Conflict of interest: none

Financial source: none

<sup>1</sup>Research performed at Experimental Laboratory, Department of Surgery and Orthopedics Diseases, Botucatu Medical School, State University of Sao Paulo (UNESP), Brazil.