

## Laparoscopic nephrectomy with single-portal access Gelpoint® in swines<sup>1</sup>

Fernando Meyer<sup>I</sup>, Letícia Chueiri<sup>II</sup>, Maiara Radigonda<sup>II</sup>, Denise Sbrissia e Silva Gouveia<sup>III</sup>, Thais Tesser de Araujo<sup>II</sup>, André Gustavo Maschio<sup>IV</sup>, Mateus Eduardo Rugilo Rosa<sup>V</sup>

<sup>I</sup>PhD, Chairman, Full Professor, Urology Division, Pontifical Catholic University of Parana (PUCPR). Head, Department of Urology, Cajuru University Hospital, PUCPR, Curitiba-PR, Brazil. Conception of the study, provided guidelines for the surgical interventions, technical procedures, English language, manuscript writing, supervised all phases of the study, critical revision.

<sup>II</sup>Graduate students, PIBIC/PIBITI, Medical School, PUCPR, Curitiba-PR, Brazil. Helped with technical procedures, Acquisition of data, technical procedures, manuscript writing.

<sup>III</sup>MD, Resident, PIBITI, Department of General Surgery, Santa Casa de Misericórdia Hospital, Curitiba-PR, Brazil. Acquisition and interpretation of data, technical procedures, manuscript writing.

<sup>IV</sup>MD, Resident, Department of General Surgery, Santa Casa de Misericórdia Hospital, Curitiba-PR, Brazil. Acquisition and interpretation of data, English language, manuscript writing.

<sup>V</sup>Graduate student, Medical School, PUCPR, Curitiba-PR, Brazil. Acquisition and interpretation of data, English language, manuscript writing.

---

### ABSTRACT

**PURPOSE:** To analyze the viability of using Gelpoint® (single-port access) to make partial and total nephrectomy in pigs and to describe the technical difficulties found during these surgical procedures.

**METHODS:** Ten pigs (Landrace specie) with 20kg in average were distributed in two groups. Group A: total right nephrectomy and Group B: partial left nephrectomy. The procedures were performed inside the Surgical Technique Room from Pontifícia Universidade Católica do Parana (PUCPR).

**RESULTS:** In Group A, time to single-port insertion varied from one to two minutes and total time of the procedures were 20.4±8.2 minutes. Bleeding was under than 20 mL in 70% of animals. Time of instrument excision was 20.7±12 seconds and time of hilum dissection was 3.9±2.2 minutes. In Group B, after total contralateral nephrectomy two surgical procedures were not concluded due to bleeding. In this group, time of surgery was 6.8±4.2 minutes. With the exception of the second surgery, the highest blood volume loss was 50 mL. The mean excision time was 22.3 ± 22.3 seconds.

**CONCLUSION:** Total and partial nephrectomy through umbilical single-access using GelPoint® was feasible and safe in pigs.

**Key words:** Nephrectomy. Laparoscopy. Swine.

---

## Introduction

Laparoscopy with single-port access is a minimal invasive therapeutic option which, through a small incision, all surgery instruments are introduced. Apart from reducing the number of incisions, single-port technique permits better esthetics results, less use of narcotic analgesics, quicker return to activities, reduction of post-operative complications related to wound and the same functional results from conventional open surgery.<sup>1</sup>

Despite the advantages, LESS technique (Laparoendoscopic Single Site Surgery) causes loss of triangulation from conventional laparoscopic surgery, causing difficulties to surgeon's movements and consequently improving his learning skills curve. Thus, the previous knowledge of conventional laparoscopic procedure before debuting on surgery of laparoscopic with single-port access is essential.<sup>2</sup>

In Urology, Desai *et al.*<sup>3</sup> described the first procedures using single-port access, which through R-PORT® (Advanced Surgical Concepts, Dublin, Ireland) was performed a pyeloplasty and a transumbilical nephrectomy.

In Brazil, Martins *et al.*<sup>4</sup> had developed a trocar to use in a single-access abdominal surgery. They nominated it as SITRACC® (Single Trocar Access). This instrument consists on a four-way trocar which combine flexible endoscopy and videosurgery. SITRACC® can be used in the navel, vagina (in experimental phase) or through an access near the incision area. It is similar to the conventional laparoscopic surgery, but it has a new articulated system which permits the surgeon to work in different movements in the same axis.

Martins *et al.*<sup>4</sup> used SITRACC® in a cholecystectomy in ten female pigs, weighing in average 30kg. All the surgeries were completed with no need to conventional laparoscopic change, thus, they concluded this new modality is practicable for cholecystectomies in pigs. The first cholecystectomy via SITRACC® in humans was performed in a 46-year-old female patient. This procedure was done with classic steps of cholecystectomy, surgical time was 64 minutes and there were no surgery-related complications<sup>5</sup>.

The GelPoint® instrument, developed by Applied Medical Resources (Rancho Santa Margarita, CA), consists in a single-access advanced system which provides a continuous visualization of abdominal cavity, conserving the pneumoperitoneum during laparoscopy. Its gel sealed-cover facilitates the triangulation of standardized laparoscopic instruments, which maximizes the internal diameter of procedure and offers more freedom to movements (Figure 1 and 2).

Similarly to SITRACC®, GelPoint® was designed to allow manipulation of instruments inside abdominal cavity, making it possible to access a single-way and reducing the intra and post-operative risks.

GelPoint® reduces injuries related to trocars insertions and improves scars appearance (esthetics), evidencing its benefits and relevance to patients. In contrast with nowadays, in the past, this was not relevant, but now especially children and women should be included to a risk-benefit esthetic factor evaluation.

Hence there is an expectation that GelPoint® may be an alternative for renal surgeries, the current study aims to evaluate partial and total nephrectomy in an experimental model (pigs). The aims of this work consist on analyzing the use of this new surgical instrument in two different surgical techniques and also describe the difficulties found in the proposed procedure.

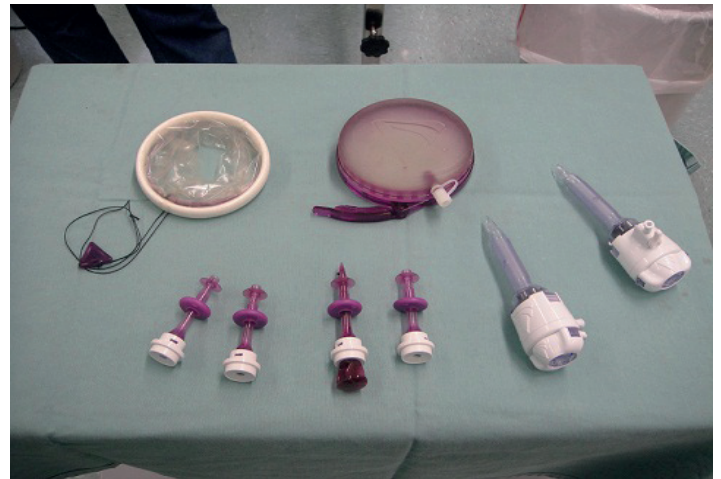


FIGURE 1 - GelPoint® and its trocars.

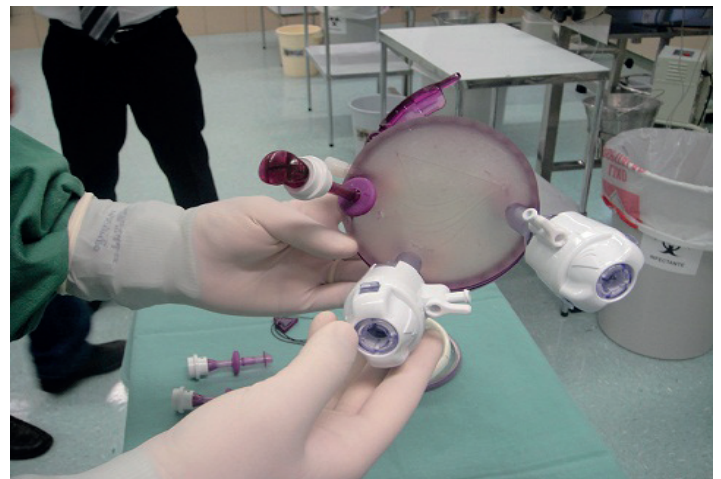


FIGURE 2 – Triangulation of trocars on GelPoint®.

## Methods

All the experiments were done according to Brazilian College of Animal Experimentation (COBEA) and after approval by the Ethics Committee on Animal Use (CEUA).

Ten pigs, Landrace specie, with 20 kg in average were distributed in two operation groups: Group A (total right nephrectomy) and Group B (partial left nephrectomy).

It was intentioned to use the less number of pigs, so it was done a two-step procedure in the same animal: total and partial nephrectomy. The first step included Group A (total right nephrectomy) and, after it, the second step consisted on changing the animals' position to proceed with a partial left nephrectomy (Group B).

Anesthesia was done with thiopental 10 mg/kg and maintained with halothane. The surgery consisted on the following sequence: anesthesia induction; fixation of the animal on the surgical table in right lateral decubitus; abdominal area was cleaning with iodine alcohol; establishment of the operatory place; incision of approximately 3.0 cm under the umbilical scar; introduction of GelPoint® through the incision; total right nephrectomy according to the laparoscopic technique; hemosthasia

and cavity revision; GelPoint® withdrawal together with the right kidney; animal repositioning (left lateral decubitus) to proceed with partial nephrectomy (Group B); abdominal area cleaning with iodine alcohol; establishment of the operatory place; introduction of GelPoint® through the incision; partial left nephrectomy according to the laparoscopic technique; hemosthasia and cavity revision; GelPoint® withdrawal together with the resected renal segment, abdominal sewing with a mononylon string 2-0; and euthanasia. Euthanasia was performed with 20 mL of KCl, which was administrated *in bolus*.

Therefore, data collected to study included: animal's weight, total surgery duration; time GelPoint® introduction; volemic loss; size of the removed organ; size of incision; time to organ excision; and time to hilum dissection.

## Results

The ten operatory procedures aimed to evaluate the surgical technique in pigs and also to foresee the complications associated to this technique in humans. Data related to total nephrectomy is shown in Table 1 and data related to partial nephrectomy in Table 2.

**TABLE 1** - Total nephrectomy.

SURGERY	WEIGHT (kg)	TOTAL TIME OF THE SURGERY (min)	TOTAL TIME OF GelPoint® INTRODUCTION (min)	VOLEMIC LOSS (mL)	SIZE OF THE ORGAN (cm)	SIZE OF THE INCISION (cm)	TIME OF PIECE EXCISION (seconds)	TIME OF HILUM DISSECTION (min)
1D	20	31	2	< 20	8.5 x 4	3	80	4
2D	20	31	2	< 20	8.5 x 4	2.5	41	4
3D	12	26	1	150	6 x 2.5	3	10	8
4D	12	13	2	< 20	7.5 x 3.5	3	5	3
5D	15	11	1	< 20	7 x 3.5	3	13	2
6D	15	12	1.5	50	6.5 x 3.5	3	7	1
7D	12	9	1	50	6 x 3	3	13	3
8D	15	29	1	< 20	7 x 2	3	15	8
9D	12	21	2	< 20	7.5 x 3	3	11	3
10D	13	21	1	< 20	7 x 3.5	3	12	3

TABLE 2 - Partial nephrectomy.

SURGERY	WEIGHT (kg)	TOTAL TIME OF THE SURGERY (min)	TOTAL TIME OF GelPoint® INTRODUCTION (min)	VOLEMIC LOSS (mL)	SIZE OF THE ORGAN (cm)	SIZE OF THE INCISION (cm)	TIME OF PIENCE EXCISION (seconds)
1E	20	8	2	< 20	3.5 x 2	3	61
2E	20	6	1	150	2.5 x 2	2.5	55
3E	12	Not concluded	Not concluded	Not concluded	Not concluded	Not concluded	Not concluded
4E	12	4	1	< 20	4.5 x 2.5	3	5
5E	15	3	1	< 20	3 x 1.5	3	2
6E	15	3.5	1.5	50	2.5 x 2	3	3
7E	12	3	1	50	2.5 x 2	3	5
8E	15	14.5	1.5	< 20	2 x 1.5	3	28
9E	12	13	2	< 20	2.5 x 2	3	20
10E	13	Not concluded	Not concluded	Not concluded	Not concluded	Not concluded	Not concluded

When analyzing the data described on Table 1, there was a variation from 1 to 2 minutes on the time of instrument insertion after standardized skin incision. There was also a variability of surgical acts total time (between 9 to 31 minutes), considering a total mean time of  $20.4 \pm 8.2$  minutes. In 70% of animals, bleeding was less than 20 mL. The mean time of organ excision was  $20.7 \pm 12$  seconds, moreover there was a considerable reduction on time after the third procedure. The time of hilum dissection was similar in all animals of the group ( $3.9 \pm 2.2$  minutes).

In relation to Table 2, the surgical acts number 3 and 10 were not concluded because of excessive bleeding after total contralateral nephrectomy. This situation create problems to the surgical technique because the operation area had no adequate visibility, thus, making the surgery team finish the procedure before concluding it with euthanasia to reduce animal's suffering. With other animals, time to insert the instrument varied from 1 to 2 minutes and surgery average time was  $6.8 \pm 4.2$  minutes. Exceptionally in surgery number 2, which blood loss was 150 mL, the highest volemic loss in operated animals was 50 mL. The average time for organ excision was  $22.3 \pm 22.3$  seconds.

## Discussion

Although videolaparoscopy had been established on minimal invasive therapeutic alternatives scenery, many technologic and scientific investments on new techniques have been created, which are less damaging and have better esthetic results for the patient<sup>6</sup>. In urologic surgery field, LESS technique emerged as an alternative to conventional videolaparoscopy, especially on nephrectomies, as long as similar and satisfactory results started to be published when these two techniques were compared<sup>7</sup>.

The restriction on deliberate use of LESS technique for nephrectomy and other surgical procedures is due to trocars' triangulation, which results in movement reduction and increase the possibility to collide the tweezers. In this context, several single-port instruments were designed aiming to improve the physicians' progression on learning skills curve, making the surgery safer, with appropriate time of execution and better overall results<sup>6,7</sup>.

GelPoint® is an advanced single-access instrument developed by Applied Medical Resources (Rancho Santa Margarita, CA), which permits single access, continue visualization of abdominal cavity, preservation of pneumoperitoneum from beginning to the end of surgery and less risk of injury on trocar's insertion. Besides it, esthetic factor is also considerably relevant nowadays when choosing a surgery technique, especially in women and children.

In addition, GelPoint® has a removable gasket cover which can take out the excised organ with the instrument itself, without extending the size of incision. Moreover, the cover allows the introduction of the trocars in the desired position, including its position change when necessary<sup>7</sup>.

Brown-Clerk *et al.*<sup>6</sup> compared three important systems of single-portal access: TriPort®, SILS® and GelPoint®. GelPoint® showed better results related to surgeon's performance and it was considered the most appropriate instrument for nephrectomy.

Among the parameters evaluated in this work, it is important to give emphasis to time to renal hilum dissection, which the average time was  $3.02 \pm 1.76$  minutes due to factors such as: animals' abdominal cavity restriction compared to human and use of conventional laparoscopic instruments leading to more difficulties to move the tweezers. We believe that when using adequate surgical instruments for LESS technique, such as curved and articulated tweezers and a light source posteriorly illuminating instead of in a 90° angle, would facilitate surgeon's hands movements and decrease instruments collision.

GelPoint® design facilitates its insertion and fixation to abdominal wall. This can be observed with the time required to place it, which did not exceed 2 minutes. SITRACC®, designed in 2007 in Brazil by Martins *et al.*<sup>8</sup>, is used for the same purpose, and varied from two to five minutes to abdominal wall installation.

During the procedures we observed the importance of appropriate surgical team training, because frequently there is a loss of conventional laparoscopic surgery triangulation, so since they are working in parallel, simultaneous movements are necessary by the surgeon and the auxiliary responsible for the camera to guarantee an appropriate procedure.

Comparative studies between devices of LESS are lacking in the literature, which prejudices the divulgation of this technique. The renewal of the conventional technique, which is still implemented inside many hospitals, depends on studies to show its benefits and disadvantages of Gelpoint, aiming to improve the technique used on its execution.

## Conclusions

Total and partial videolaparoscopic nephrectomy by umbilical access with GelPoint® was feasible and safe to the experimental animals. The possibility to make this procedure a minimal invasive surgery may depend on the development and adaptation of new instruments. Therefore, this study may be used to future comparisons and surgical indications to facilitate its use in humans, because it was firstly evidenced the possibility to use this new technique in pigs.

## References

1. Musquera M, Peri L, Izquierdo L, Campillo P, Ribas MJ, Alcaraz A. Experiencia pionera en España con nefectomía LESS de donante vivo. *Actas Urol Esp.* 2011;35:559-62.
2. Sotelo R, Astigueta JC, Carmona O, Andrade RD, Sánchez-Salas R. Laparo-endoscopia por acceso único: experiencia inicial. *Actas Urol Esp.* 2009;33(2):172-81.
3. Desai MM, Rao PP, Aron M, Pascal-Haber G, Mishra S, Kaouk JH, Gill IS. Scarless single port transumbilical nephrectomy and pyeloplasty: first clinical report. *BJU Int.* 2008;101(1):83-8.
4. Martins MVDC, Skinovsky J, Coelho DE, Torres MF. SITRACC® - Single trocar access: a new device for a new surgical approach. *Braz J Videoendoscopic Surg.* 2008;1(2):61-3.
5. Martins MVDC, Skinovsky J, Coelho DE. Colectectomia videolaparoscópica por trocarte único (SITRACC®): uma nova opção. *Rev Col Bras Cir.* 2009;36(2):177-9.
6. Brown-Clerk B, Laveaga AE, LaGrange CA, Wirth LM, Lowndes BR, Hallbeck MS. Laparoendoscopic single-site (LESS) surgery versus conventional laparoscopic surgery: comparison of surgical port performance in a surgical simulator with novices. *Surg Endosc.* 2011;25:2210-8.
7. Aminsharifi AR, Goshtasbi B, Afsar F. Laparoendoscopic single-site nephrectomy using standard laparoscopic instruments: our initial experience. *Urol J.* 2012;9(4):657-61.
8. Meyer F, Coutinho DJ, Gouveia Denise SS, Lizana JN, Dziedricki LF. Laparoscopic nephrectomy with single-portal access Sitracc® in swines. *Acta Cir. Bras.* 2012;27(3):231-5.

## Correspondence:

Fernando Meyer  
Pontifícia Universidade Católica do Paraná (PUCPR)  
Departamento de Urologia  
Rua Portugal, 307  
80510-280 Curitiba - PR Brasil  
Tel.: (55 41)3074-7478  
Fax: (55 41)3015-0303  
fmeyer@onda.com.br

Received: July 18, 2013

Review: Sept 17, 2013

Accepted: Oct 21, 2013

Conflict of interest: none

Financial sources: Institutional Program for Scientific Initiation Scholarship (PIBIC) and Institutional Program for Initiation in Technological Development and Innovation (PIBITI) of the National Council for Scientific and Technological Development (CNPq), Brazilian Ministry of Science and Technology,

<sup>1</sup>Research performed at Operative Technique and Experimental Surgery Division, Department of Urology, Pontifical Catholic University of Parana (PUCPR), Curitiba-PR, Brazil.