

The protective cardiac effects of β -myrcene after global cerebral ischemia/reperfusion in C57BL/J6 mouse¹

Gul Baykalir Burcu^I, Ciftci Osman^{II}, Cetin Ash^{III}, Oztanir Mustafa Namik^{IV}, Basak Türkmen Neşe^V

DOI: <http://dx.doi.org/10.1590/S0102-865020160070000005>

^IAssistant Professor, Department of Pharmacology and Toxicology, Faculty of Veterinary, University of Firat, Elazig, Turkey. Acquisition of data, manuscript writing.

^{II}Professor, Department of Medical Pharmacology, Faculty of Medicine, University of Inonu, Malatya, Turkey. Design of the study, manuscript writing, carry out the study.

^{III}Assistant Professor, Department of Histology and Embryology, Faculty of Medicine, University of Inonu, Malatya, Turkey. Histological examinations.

^{IV}Professor, Department of Brain and Neurosurgery, Faculty of Medicine, University of Inonu, Malatya, Turkey. Design of the study.

^VPhD, Department of Pharmaceutical Toxicology, Faculty of Pharmacy, University of Inonu, Malatya, Turkey. Biochemical experiments.

ABSTRACT

PURPOSE: To investigate the protective effect of β -myrcene (MYR) on oxidative and histological damage in mice heart tissue caused global cerebral ischemia/reperfusion (IR) in C57BL/J6 mice.

METHODS: Animals(n=40) were randomly divided into four groups: (1)control, (2)IR, (3)MYR and (4)MYR+IR. The control group was received 0.1% carboxymethyl cellulose as a vehicle following a medial incision without carotid occlusion. In the IR group, the bilateral carotid arteries were clipped for 15min, and treated with the vehicle intraperitoneally(ip) for 10 days. MYR (200mg/kg) was received dissolved in 0.1%CMC for 10 days. In the MYR+IR group, the IR model was applied exactly as in the IR group, and then they were treated with MYR 10 days.

RESULTS: The cerebral IR caused oxidative damage (increase TBARS, decrease antioxidant parameters). Treatment of MYR was increased in GSH,GPx,CAT,SOD activity while TBARS level was decreased. In addition, degenerative changes in I/R group heart tissue were ameliorated by MYR administration.

CONCLUSION: The administration of β -myrcene protects oxidative and histological damage in the heart tissue after global ischemia-reperfusion and may be useful safe alternative treatment for cardiac tissue after ischemic stroke.

Key words: Brain Ischemia. Reperfusion. Oxidative Stress. Mice.

Introduction

Stroke is the third most common cause of death in most industrialized countries¹. Global cerebral ischemia occurs when the blood supply to the entire brain or a large part of the brain is disrupted, resulting in the tissue deprivation of oxygen and glucose that may give tissue damage². In adult humans, global cerebral ischemic injury occurs in some conditions like cardiac arrest, coronary artery bypass surgery, cardio-respiratory failure, and others leading to the drastic reduction of the blood flow to the brain³. Ischemia/reperfusion (IR) injury is a complex disorder and produces a series of molecular and cellular changes such as reduction-oxidative damage, molecular inflammatory dysfunction, high-energy depletion, and ion imbalances that culminate in a severe pathological state directly related to the intensity of the injury⁴. However, a therapeutic strategy for cerebral IR injury has not been established yet⁵. Among these, cerebral IR in particular are responsible for oxidative stress due to the generation of free radicals⁶, which culminates into deleterious effects during pathogenesis⁷. During reperfusion after ischemia, while restoration of oxygen and glucose supply reinstates the oxidative phosphorylation that helps to normalize energy demanding physiologic processes, a parallel cascade of deleterious biochemical processes can be triggered that may paradoxically antagonize the beneficial effect of reperfusion⁸. This phenomenon has been demonstrated in various tissues, especially in the heart, and has been termed reperfusion injury⁹.

β -myrcene (7-methyl-3-methylene-1,6-octadiene) is a monoterpene that is found in many plants including hops, verbena and lemon grass¹⁰. It is also produced commercially in high volume for use in essential oils as intermediates in the production of terpene alcohols. β -myrcene is therefore widely used as a flavoring additive in the production of food and soft beverages, in alcoholic beverages, and in the manufacture of cosmetics, soaps, and detergents¹¹. It has many pharmacological actions including analgesic, antiinflammatory and antioxidant effects¹⁰⁻¹⁴. It was thought that MYR is a strong antioxidative agent and with this property it can be prevents oxidative and histological damage in tissue. Therefore MYR were selected in this study for treatment of cardiac damage after stroke.

Thus, the current study investigated that MYR treatment ameliorates the oxidative and histological heart damage after global cerebral IR in C57BL/6 J mice.

Methods

The present study was approved by the Ethical Committee on Animal Research of Inonu University and carried

out in accordance with the Guidelines for Animal Research of the National Institutes of Health (NIH).

C57BL/6J male mice (clean grade), weighting 18-22g, were supplied by the Inonu University Laboratory Animals Research Center (Malatya, Turkey), housed in sterilized polypropylene cages, and given an *ad libitum* diet of standard commercial food pellets and water. All mice were kept under a 12-h light/dark cycle at an ambient temperature of 21±2°C and a humidity level of 60±5%. A total of 40 animals were randomly divided into four groups (n = 10): (1) control (sham-operated), (2) global cerebral IR, (3) MYR, and (4) MYR+IR. This experimental design was described in our previous study¹⁵. MYR (200 mg/kg) was dissolved in 0.1% carboxymethyl cellulose and administered intraperitoneally (i.p.) for 10 consecutive days. The dose of MYR was selected according to Ciftci *et al.*¹² and MYR treatment was initiated concomitant with the induction of global cerebral IR. Mice in the SH group and the IR group were treated with only the 0.1% CMC solution as a vehicle. In the MYR and MYR+IR groups, mice were treated with MYR (200 mg/kg/day) for 10 days following the IR procedure, after which all animals were sacrificed under anesthesia, and tissue and blood samples were obtained for laboratory analyses.

Chemicals

Myrcene and all other chemicals used for experimental analysis were purchased from Sigma Chemical Co. (St. Louis, MO) and were of analytical grade, or of the highest grade available.

Surgical procedure

This experimental design was described in our previous study¹⁵. For the induction of global cerebral ischemia, the mice were anesthetized with xylazine (5 mg/kg, *i.p.*) and ketamine (100 mg/kg, *i.p.*), and the procedure was performed according to the methods of Yonekura *et al.*¹⁶. Briefly, after a midline cervical incision, the bilateral common carotid arteries of animals in the IR and MYR+IR groups were isolated and occluded simultaneously for 15 min using two vascular miniclips. The same surgical procedure was applied to the SH and MYR groups, except that the carotid arteries were not clipped. Following surgery, all mice were placed in a thermal room until they recovered from anesthesia.

Biochemical analyses

The homogenization of tissue briefly was described our previous study^{13,14}. The levels of thiobarbituric acid reactive

substances (TBARS), total glutathione (GSH) levels and catalase (CAT), superoxide dismutase (SOD) and glutathione peroxidase (GPx) activities were determined by spectrophotometric methods and these methods briefly given our previous study^{13,14}.

Histological analysis

For histopathological examination, transverse section through the bottom of the heart is collected for each animal. For light microscopic evaluation, heart samples were fixed in 10% formalin. The heart samples were processed by routine tissue techniques and were embedded in paraffin. Paraffin-embedded specimens were cut into 5 mm thick sections, mounted on slides and stained with Hematoxylen- Eosin (H-E). Sections examined under a Leica DFC280 light microscope by Leica Q Win and Image Analysis System (Leica Micros Imaging Solutions Ltd.; Cambridge, U.K).

Statistical analysis

A computer program SPSS 11.0 (SPSS Inc., Chicago, IL, USA) was used for statistical analysis. For biochemical values, statistical analyses were performed using one-way ANOVA and

post hoc Tukey's honestly significant difference test. All values were presented as mean ± S.E.M. Differences were considered to be significant at p<0.05.

Results

Biochemical

The TBARS, GSH, CAT, GPx levels and SOD activity for heart tissue are given in Table 1. In IR group, the results showed that SOD, GPx, CAT and GSH levels were significantly (P≤0.01) decreased whereas TBARS levels were significantly (P≤0.01) increased compared with the control and other groups. It was shown that brain IR caused a significant increase lipid peroxidations in heart tissue. Also, it was determined that there were not any significant changes between the control and MYR groups in terms of SOD, CAT, GSH, TBARS and GPx levels. In IR+MYR group, the value of TBARS, CAT, SOD and GPx were near to control and reversed the effect of brain IR on these values. However, The GSH levels were changed but it was not in a statistically significant range. Generally, the results showed that MYR significantly reduced lipid peroxidations in heart tissue.

TABLE 1 - The levels of TBARS, GSH, CAT, GPx and SOD in heart tissue of C57BL/6J mice (mean ± SEM).

	TBARS (nmol/g tissue)	GSH (nmol/ml)	CAT (k/mg protein)	GPx (U/g protein)	SOD (U/mg protein)
Control	5.23 ± 0.41 ^a	53.7 ± 2.81 ^a	0.0061 ± 0.0002 ^a	65.16 ± 2.14 ^a	17.5 ± 1.12 ^a
IR	8.61 ± 0.40 ^b	39.2 ± 3.02 ^b	0.0023 ± 0.0004 ^b	31.57 ± 1.25 ^b	10.2 ± 1.21 ^b
MYR	5.34 ± 0.25 ^a	58.4 ± 3.23 ^a	0.0058 ± 0.0005 ^a	59.86 ± 1.71 ^a	17.9 ± 1.54 ^a
IR+MYR	6.02 ± 0.53 ^a	43.1 ± 2.13 ^b	0.0045 ± 0.0001 ^c	45.54 ± 2.06 ^c	13.2 ± 1.32 ^c

Means bearing different superscripts within same column were significantly different (p<0.01).

Histopathological

We examined sections for eosinophilic stained and pyknotic nuclei cells, vacuolisation, hemorrhage, mononuclear cell infiltration, congestion and necrosis. Histopathologic damage score was calculated these findings. Statistical analysis was made with SPSS 13.0 (SPSS Inc., Chicago, Ill., USA) and MedCalc 11.0 (Belgium) statistical programs. All data are expressed as arithmetic mean ± S.E. For comparisons between groups Kruskal-Wallis and Conover tests were used. Exact *p* values were given where available, and p< 0.0001 was accepted as statistically significant. Histopathological score was given in Table 2.

TABLE 2 - Comparison of the effect of Myrcen on histological changes caused by cerebral I/R on cardiac tissue. (Mean ± SE).

	Histopathologic Damage
Control	0.24 ± 0.10 ^a
IR	2.38 ± 0.13 ^b
MYR	0.90 ± 0.12 ^a
IR+MYR	1.57 ± 0.13 ^c

The mean differences the values bearing different superscript letters within the same column are statistically significant. (p≤0,0001). SE: Standart Error

In control and MYR groups showed normal cardiac histology of mouse as represented by Figure 1A and B,

respectively. In these groups heart tissue showed a normal myofibrillar structure with striations, branched appearances and continuity with adjacent myofibrils. Cardiac muscle cells were also normal; their large purple nucleus was located in the center of their pink colored cytoplasm. In addition to this, MYR treated animals had normal myocardial morphology too. The hearts of IR treated mouse showed distinctive appearance of cardiotoxicity with various degrees of focal damages. These damages are

eosinophilic stained and pyknotic nuclei cells (Figure 2C, E), vacuolisation, hemorrhage (Figure 2A, E), mononuclear cell infiltration (Figure 2A, D), congestion (Figure 2D) and necrosis (Figure 2C). We detected these histological findings decreased in IR+MYR group (Figure 3A, 3B). MYR supplementation reduced IR- induced histopathological changes in comparison to compared to that of IR treated groups.

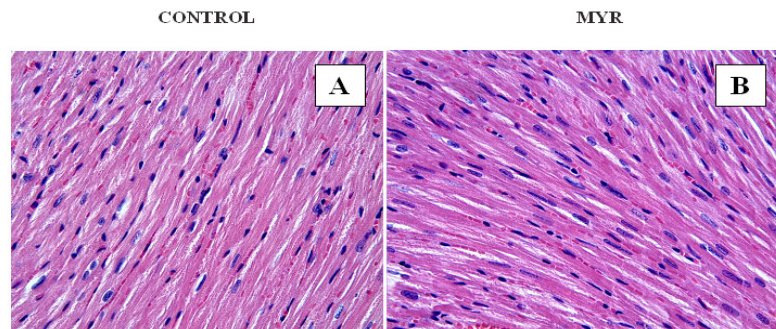


FIGURE 1 - Heart tissues in control (A) and MYR (B) groups show normal appearance of cardiac myofibres (H&E, x40).

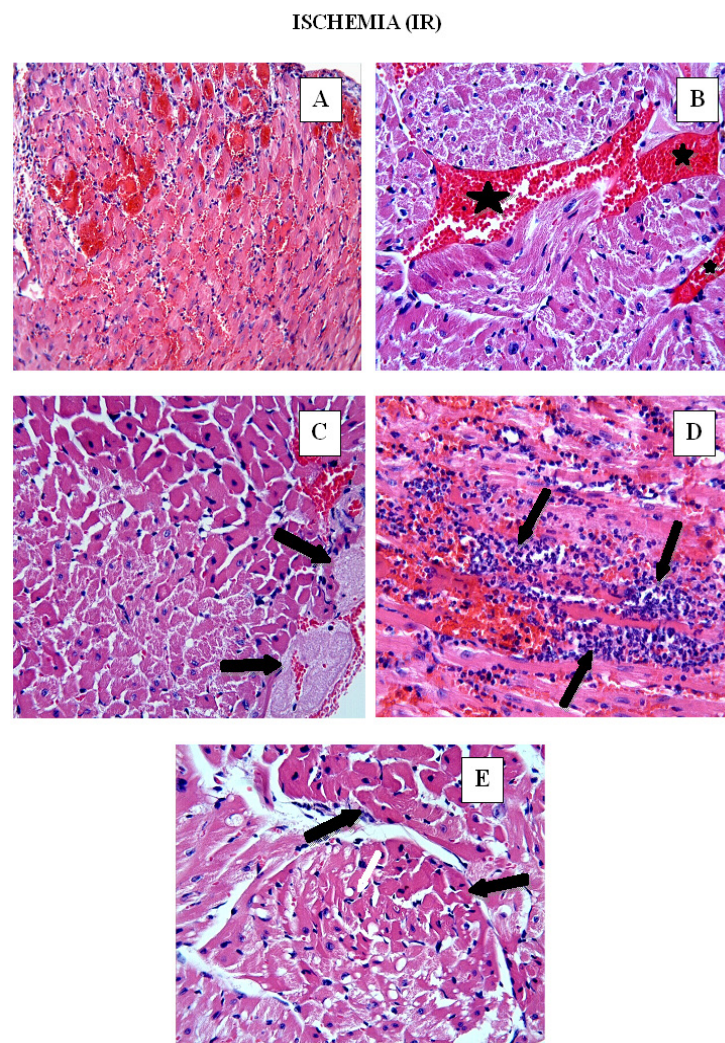


FIGURE 2 - IR group. Hemorrhage (A,C), mononuclear cell infiltration (A,D), vascular congestion (asterisks) (B), necrosis (arrows) (C), eosinophilic stained and pyknotic nuclei cells (C,E), vacuolisation (E) (H&E, x20).

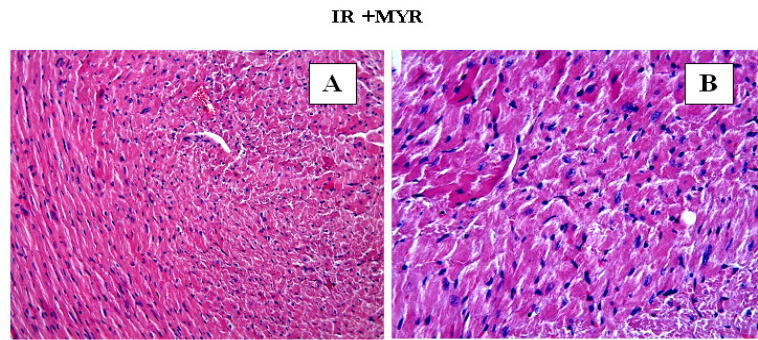


FIGURE 3 - IR + MYR group. Degenerative changes were decreased in IR+MYR group compared with IR group. **A** (H&E, x20), **B** (H&E, x40).

Discussion

In the present study, the protective effect of MYR on oxidative and histological damage in heart tissue after global cerebral ischemia/reperfusion (IR) in C57BL/J6 mice. There were found that brain IR caused a significant increase lipid peroxidations in heart tissue. And treatment of MYR reduced significantly lipid peroxidation in heart tissue. Many methods have been used to induce global cerebral ischemia in experimental animal models including decapitation without recirculation, neck tourniquet, bilateral common carotid artery occlusion and four-vessel occlusion¹⁷⁻²⁰. But, bilateral carotid artery occlusion is commonly used in C57BL/J6 mouse to design global cerebral IR model¹². This experimental model is used there. MYR were selected in this study for treatment of cardiac damage after stroke¹². Because It was thought that MYR is a strong antioxidative agent and it can prevent oxidative and histological damage in tissue. It was found that treatment of MYR has a protective effect against induced global cerebral IR due to decrease in oxidative stress and histopathological damage in heart. The mechanism is disclosed that reduction of production lipid peroxidation and inhibition of apoptosis.

It has been well established that oxidative stress displays an important role in the pathophysiology of IR. The excessive production of ROS occurs during IR^{21,22}. However, the exact mechanisms underlying heart damage after IR injury have not been elucidated yet. Among these, cerebral IR in particular are responsible for oxidative stress due to the generation of free radicals⁶. Alteration in Ca²⁺ homeostasis in tissue due to an increase in ROS has been suggested to explain the adverse effects of cerebral IR. It is a problem which damages the myocardium after a critical period of arteries occlusion. Mitochondria serve as a source for the massive generation of ROS during IR, thus leading to serious tissue injury. Under these conditions, xanthine

dehydrogenase is converted into xanthine oxidase, leading to the accumulation of purine metabolites, hypoxanthine and xanthine, which subsequently produce enormous amounts of superoxide anion radical and hydrogen peroxide^{22,23}. Oxidative stress and increased Ca²⁺ cause the opening of mitochondrial permeability transition pore. This allows an entry of water and solutes from the cytoplasm resulting in mitochondrial swelling and damage. The generation of ROS also occurs in the cytoplasm through the action of NAD(P)H oxidase. The resulting oxidative stress can outweigh antioxidant defenses and lead to cell death because oxidative stress can cause a widespread damage to cellular components such as DNA, lipids, and proteins that ultimately promote cellular damage and death during cerebral ischemia and reperfusion in many organs including heart^{2,7}.

It was seen that global cerebral IR induced lipid peroxidation in heart tissue in term of TBARS levels in this study. But, the antioxidant defense system was suppressed by IR in heart tissue via decreased enzymatic activities of SOD, CAT, GPx and expression in levels of GSH. Recent studies^{10,25} have confirmed our findings. The current study demonstrated that treatment of MYR caused a significant decrease in TBARS levels and increase in SOD, CAT, GPx activities and GSH levels in heart tissue of ischemic mice. Treatment of MYR decreases oxidative damage and ameliorates the heart damage caused by IR. There are few studies describing the pharmacological activity of MYR and these studies showed that MYR has an important analgesic, antiinflammatory and antioxidant properties^{10,11,13,14,26}. These findings approve that MYR is a strong antioxidant. Hence, MYR may protect heart tissue as a possible antioxidant, prevent damage and lipid peroxidation.

In this study, there was evaluated that significant histopathological changes in IR group, compared with the other groups. In IR group was shown distinctive appearance of cardiotoxicity with various degrees of focal damages including

eosinophilic stained and pyknotic nuclei cells, vacuolisation, hemorrhage, mononuclear cell infiltration, congestion, and necrosis. There was decreased these histological findings in treatment of MYR group. MYR treatment was reduced histopathological changes compared to IR group. Many studies^{12,27-29} confirmed the histological results. Also, treatment of MYR ameliorates histological changes caused by IR.

Conclusions

β -myrcene (MYR) has a modulatory effect on heart tissue after cerebral IR injury. There was relationship between oxidative status and histopathological changes. The useful effects of MYR seem to be closely linked with the suppressing of lipid peroxidation and enhancing of antioxidant enzyme activities.

References

- Margaill I, Plotkine M, Lerouet D. Antioxidant strategies in the treatment of stroke. *Free Radic Biol Med*. 2005 Aug;15;39(4):429-43. PMID: 16043015.
- Lee JC, Won MH. Neuroprotection of antioxidant enzymes against transient global cerebral ischemia in gerbils. *Anat Cell Biol*. 2014 Sep;47(3):149-56. doi: 10.5115/acb.2014.47.3.149.
- Llinas R, Barbut D, Caplan LR. Neurologic complications of cardiac surgery. *Prog Cardiovasc Dis*. 2000 Sep-Oct;43(2):101-12. PMID: 11014328.
- Boys JA, Toledo AH, Anaya PR, Lopez NF, Toledo PLH. Effects of dantrolene on ischemia reperfusion injury in animal models: a review of outcomes in heart, brain, liver, and kidney. *JIM*. 2010 Oct;58(7):875-82. doi: 10.2311/JIM.0b013e3181e5d719.
- Yasuda N, Ishii T, Oyama D, Fukuta T, Agato Y, Sato A, Shimizu K, Asai T, Asakawa T, Kan T, Yamada S, Ohizumi Y, Oku N. Neuroprotective effect of nobiletin on cerebral ischemia-reperfusion injury in transient middle cerebral artery occluded rats. *Brain Res*. 2014 Apr;1559:46-54. doi: 10.1016/j.brainres.2014.02.007.
- Nita DA, Nita V, Spulber S, Moldovan M, Popa DP, Zagrean AM, Zagrean L. Oxidative damage following cerebral ischemia depends on reperfusion: a biochemical study in rat. *J Cell Mol Med*. 2001 Apr-Jun;5(2):163-70. PMID: 12067499.
- Chan PH. Reactive oxygen radicals in signaling and damage in the ischemic brain. *J Cereb Blood Flow Metab*. 2001 Jan;21(1):2-14. PMID: 11149664.
- Aronowski J, Strong R, Grotta JC. Reperfusion injury: demonstration of brain damage produced by reperfusion after transient focal ischemia in rats. *J Cereb Blood Flow Metab*. 1997 Oct;17(10):1048-56. PMID: 93446429.
- Karmazyn M. Ischemic and reperfusion injury in the heart: cellular mechanisms and pharmacological intervention. *Can J Physiol Pharmacol*. 1991 Jun;69(6):719-30. PMID: 1913318.
- Bonamin F, Moraes TM, Dos Santos RC, Kushima H, Faria FM, Silva MA, Junior IV, Nogueira L, Bauab TM, Souza Brito AR, Rocha LRM, Hiruma-Lima CA. The effect of a minor constituent of essential oil from *Citrus aurantium*: The role of *b*-myrcene in preventing peptic ulcer disease. *Chem Biol Interact*. 2014 Apr 5;212:11-9. doi: 10.1016/j.cbi.2014.01.009.
- Cesta MF, Hard GC, Boyce JT, Ryan MJ, Chan PC, Sills RC. Complex histopathologic response in rat kidney to oral β -myrcene: an unusual dose-related nephrosis and low-dose alpha2u-globulin nephropathy. *Toxicol Pathol*. 2013;41(8):1068-77. doi: 10.1177/0192623313482057.
- Ciftci O, Oztanir MN, Cetin A. Neuroprotective effects of *b*-myrcene following global cerebral ischemia/reperfusion-mediated oxidative and neuronal damage in a C57BL/J6 mouse. *Neurochem Res*. 2014 Sep;39(9):1717-23. doi: 10.1007/s11064-014-1365-4.
- Ciftci O, Tanyildizi S, Godekmerdan A. Curcumin, myrcene and cineol modulate the percentage of lymphocyte subsets altered by 2,3,7,8-tetrachlorodibenzo-p-dioxins (TCDD) in rats. *Hum Exp Toxicol*. 2011 Dec;30(12):1986-94. doi: 10.1177/0960327111404909.
- Ciftci O, Ozdemir I, Tanyildizi S, Yildiz S, Oguzturk H. Antioxidative effects of curcumin, *b*-myrcene and 1,8-cineole against 2,3,7,8-tetrachlorodibenzo-p-dioxin-induced oxidative stress in rats liver. *Toxicol Ind Health*. 2011 Jun;27(5):447-53. doi: 10.1177/0748233710388452.
- Oztanir MN, Ciftci O, Cetin A, Aladag MA. Hesperidin attenuates oxidative and neuronal damage caused by global cerebral ischemia/reperfusion in a C57BL/J6 mouse model. *Neurol Sci*. 2014 Sep;35(9):1393-9. doi: 10.1007/s10072-014-1725-5.
- Yonekura I, Kawahara N, Nakatomi H, Furuya K, Kirino T. A model of global cerebral ischemia in C57 BL/6 mice. *J Cereb Blood Flow Metab*. 2004 Feb;24(2):151-8. PMID: 14747741.
- Lowry OH, Passonneau JV, Hasselberger FX, Schulz DW. Effect of ischemia on known substrates and cofactors of the glycolytic pathway in brain. *J Biol Chem*. 1964 Jan;239:18-30. PMID: 14114842.
- Siemkiewicz E, Gjedde A. Post-ischemic coma in rat: effect of different pre-ischemic blood glucose levels on cerebral metabolic recovery after ischemia. *Acta Physiol Scand*. 1980 Nov;110:225-32. PMID: 7211409.
- Crockard A, Iannotti F, Hunstock AT, Smith RD, Harris RJ, Symon L. Cerebral blood flow and edema following carotid occlusion in the gerbil. *Stroke*. 1980 Sep-Oct;11:494-8. PMID: 7423581.
- Pulsinelli WA, Duffy TA. Regional Energy balance in rat brain after transient forebrain ischemia. *J Neurochem*. 1983 May;40(5):1500-3. PMID: 6834075.
- Clemens JA. Cerebral ischemia: gene activation, neuronal injury, and the protective role of antioxidants. *Free Radic Biol Med*. 2000 May;28:1526-31. PMID: 10927177.
- Sugawara T, Chan PH. Reactive oxygen radicals and pathogenesis of neuronal death after cerebral ischemia. *Antioxid Redox Signal*. 2003 Oct;5(5):597-607. PMID: 14580316.
- Umamaheswari M, Asokkumar K, Sivashanmugam AT, Remyaraju A, Subhadradevi V, Ravi TK. In vitro xanthine oxidase inhibitory activity of the fractions of *Erythrina stricta* Roxb. *J Ethnopharmacol*. 2009 Jul 30;124(3):646-8. doi: 10.1016/j.jep.2009.05.018.
- Malik ZA, Singh M, Sharma PL. Neuroprotective effect of *Momordica charantia* in global cerebral ischemia and reperfusion induced neuronal damage in diabetic mice. *J Ethnopharmacol*. 2011 Jan 27;133(2):729-34. doi: 10.1016/j.jep.2010.10.061.
- Sen S, Chakraborty R, Sridhar C, Reddy YSR, De B. Free radicals, antioxidants, diseases and phytomedicines: current status and future prospect. *Int J Pharm Sci Rev Res*. 2010;3(1):91-100.
- Liu B, Yin G, Ding L, Ma Y. Research on the influence of diammonium glycyrrhizinate on the expression of NF-kappaB and neuron apoptosis after spinal cord ischemia-reperfusion injury in rats. *Zhongguo Xiu Fu Chong Jian Wai Ke Za Zhi*. 2008 Dec;22(12):1466-9. PMID: 19137892.

27. Wang JJ, Cui P. Neohesperidin attenuates cerebral ischemia-reperfusion injury via inhibiting the apoptotic pathway and activating the Akt/Nrf2/HO-1 pathway. *J Asian Nat Prod Res.* 2013 Sep;15:1023-37. doi: 10.1080/10286020.2013.827176.
 28. Gaur V, Kumar A. Hesperidin pre-treatment attenuates NO-mediated cerebral ischemic reperfusion injury and memory dysfunction. *Pharmacol Rep.* 2010 Jul-Aug;62(4):635-48. PMID: 20885004.
-

Correspondence:

Dr. Osman Ciftci

University of Inonu, Faculty of Medicine, Department of Pharmacology

44 280, Malatya, Turkey

Phone: +905325646122

Fax: +90422 3411216

osmciftci@gmail.com

Received: Mar 14, 2016

Review: May 16, 2016

Accepted: Jun 15, 2016

Conflict of interest: none

Financial source: none

¹Research performed at Neuroscience Laboratory, Faculty of Medicine, Inonu University, Malatya, Turkey.