

# Definitive pyloric closure for treatment of digestive fistula after pancreatoduodenectomy with over-the-scope clip (Padlock)

Eliza Ribeiro Alves de **ANDRADE**<sup>1</sup>, Rodrigo Cañada Trofo **SURJAN**<sup>2</sup>, Otávio **MICELLI-NETO**<sup>1</sup>, Jessé **CLEMENTINO-FILHO**<sup>1</sup>, Facundo **GALETTI**<sup>1</sup> and José Celso **ARDENGH**<sup>1</sup>

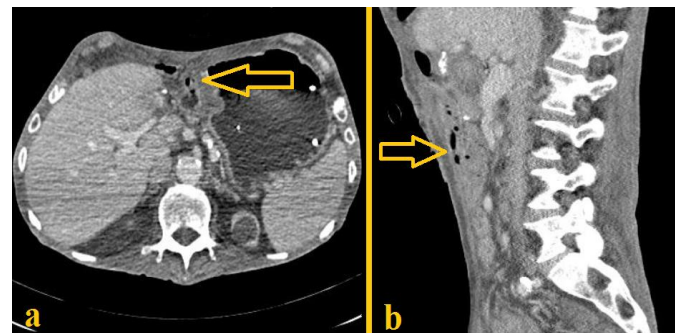
Received: 19 February 2021

Accepted: 15 March 2021

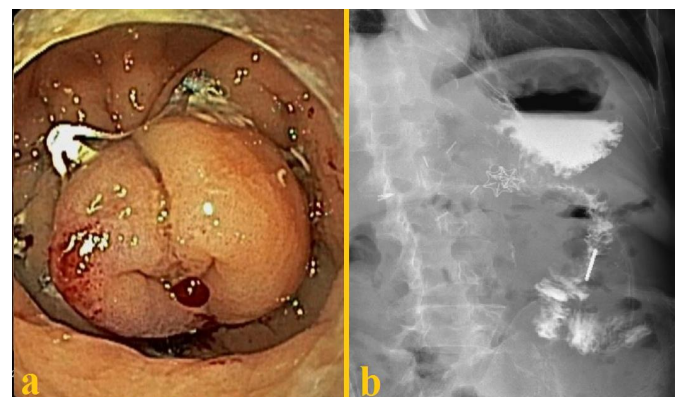
The endoscopic treatment of gastrointestinal perforations or digestive fistulas using endoclips dates from 1997 and represents a minimally invasive and effective therapeutic alternative associated with lower morbidity and mortality rates than conventional surgical approaches<sup>(1,2)</sup>. In 2009, the “over-the-scope-clip” system emerged as a new tool that would facilitate complete circumferential closure of tissues via endoscopy<sup>(3-5)</sup>. Pinho R et al., in 2015, described the first application of the “over-the-scope-clip” in endoscopic pyloric exclusion, performed after an unsuccessful attempt of surgical treatment of an intestinal fistula<sup>(6)</sup>.

We present a video of a definitive pyloric exclusion for the treatment of intestinal fistula using the Padlock “over-the-scope-clip” after pancreatoduodenectomy (PD). This is the second report of this technique and the first video demonstrating the procedure (E-VIDEO\*).

Seventy-six-year-old male, with previous robotic hepatectomy, who underwent PD and partial hepatectomy for pancreatic ductal adenocarcinoma, having previously undergone neoadjuvant chemotherapy. Liver resections were performed for suspected secondary impairment but demonstrated only inflammatory lesions (abscesses). Two months after the surgery, the patient developed nausea and frequent vomiting, in addition to multiple episodes of bronchoaspiration, requiring several digestive endoscopies and the passage of a nasojejun tube Freka® Trelumina. Given the refractoriness of the condition, surgical treatment with mechanical Y-de-Roux gastroenteroanastomosis and drain placement were chosen. Two weeks after the intervention, on abdominal computed tomography scan, small gaseous foci were identified in the upper abdomen, mainly adjacent to the drain (FIGURE 1). An upper digestive endoscopy was performed and disclosed a perforation on the afferent biliopancreatic limb close to the duodenojejunal anastomosis performed on the PD, compatible with late fistula. After 7 days of the endoscopic examination, closure and exclusion of the pylorus was performed with the use of two Padlock (FIGURE 2).



**FIGURE 1.** Intravenous contrast enhanced abdominal computed tomography disclosing small liquid collection with air foci (yellow arrows) suggestive of digestive fistula close to the hepatic raw surface area. **A)** Axial plane; **B)** Sagittal plane.



**FIGURE 2.** **A)** Pyloric exclusion with Padlock “over-the-scope-clip”; **B)** Barium meal disclosing the Padlocks, no contrast leakage, effective exclusion of the pylorus and patent gastroenteroanastomosis.

Declared conflict of interest of all authors: none

Disclosure of funding: no funding received

<sup>1</sup> Hospital Nove de Julho, Serviço de Endoscopia Gastrointestinal, São Paulo, SP, Brasil. <sup>2</sup> Hospital Nove de Julho, Serviço de Cirurgia, São Paulo, SP, Brasil.

Corresponding author: Eliza Ribeiro Alves de Andrade. E-mail: elizadeandrade@hotmail.com

\*E-VIDEO: [https://youtu.be/s563aO\\_zV4w](https://youtu.be/s563aO_zV4w)

Contrast examination (barium meal) was performed 1 week after the procedure, showing no leakage of contrast or fistulous pathways and effective pyloric exclusion (FIGURE 2B). At revision upper digestive endoscopy, a wide and patent gastroenteroanastomosis was observed with total closure of the pylorus. The patient presented uneventful recovery from the pyloric exclusion and returned to oral feeding.

This is the second report on literature of pyloric exclusion with “over-the-scope-clip”, reassuring the safety and effectiveness of the technique. It is a less invasive alternative and with lower morbidity than performing revision surgeries in order to treat digestive fistulae. Its use should be considered as an option to perform pyloric exclusion for different indications of the procedure.

### Authors' contribution

Andrade ERA and Surjan RCT wrote the article. Surjan RCT and Ardengh JC designed the study. Micelli-Neto O and Andrade ERA performed the procedure. Galetti F and Clementino-Filho performed data collection. Micelli-Neto O, Surjan RCT and Ardengh JC provided critical advice. All authors discussed the results and commented on the article and take full responsibility on the manuscript.

### Orcid

Eliza Ribeiro Alves de Andrade: 0000-0003-4364-7878.  
Rodrigo Cañada Trofo Surjan: 0000-0003-3918-8920.  
Otávio Micelli-Neto: 0000-0003-3803-5578.  
Jessé Clementino-Filho: 0000-0003-2443-4324.  
Facundo Galetti: 0000-0001-9569-1702.  
José Celso Ardengh: 0000-0002-5932-2499.

---

Andrade ERA, Surjan RCT, Micelli-Neto O, Clementino-Filho J, Galetti F, Ardengh JC. Fechamento pilórico definitivo para o tratamento da fistula digestiva após pancreato-duodenectomia com clipe “over-the-scope” (Padlock). *Arq Gastroenterol.* 2021;58(3):413-4.

---

## REFERENCES

1. Weilan T, Fehlker M, Gottwald T, Schurr MO. Performance of the OTSC System in the endoscopic closure of iatrogenic gastrointestinal perforations: a systematic review. *Surg Endosc.* 2013;27:2258-74.
2. Cereatti F, Grassia R, Drago A, Conti CB, Donatelli G. Endoscopic management of gastrointestinal leaks and fistulae: What option do we have? *World J Gastroenterol.* 2020;26:4198-4217.
3. Bartell N, Bittner K, Kaul V, Kothari TH, Kothari S. Clinical efficacy of the over-the-scope clip device: A systematic review. *World J Gastroenterol.* 2020;26:3495-3516.
4. Mosquera-Klinger G, Torres-Rincón R, Jaime-Carvajal J. Endoscopic closure of gastrointestinal perforations and fistulas using the Ovesco Over-The-Scope Clip system at a tertiary care hospital center. *Rev Gastroenterol Mex (Engl Ed).* 2019;84:263-6.
5. Dinelli M, Omazzi B, Andreozzi P, Zucchini N, Redaelli A, Manes G. First clinical experiences with a novel endoscopic over-the-scope clip system. *Endosc Int Open.* 2017;05:E151-6.
6. Pinho R, Fernandes C, Cost A, Proença L, Fernandes S, Carrapita J, Carvalho J. Definitive endoscopic pyloric exclusion with an over-the-scope-clip. *Endoscopy.* 2015;47:E323-24.

