

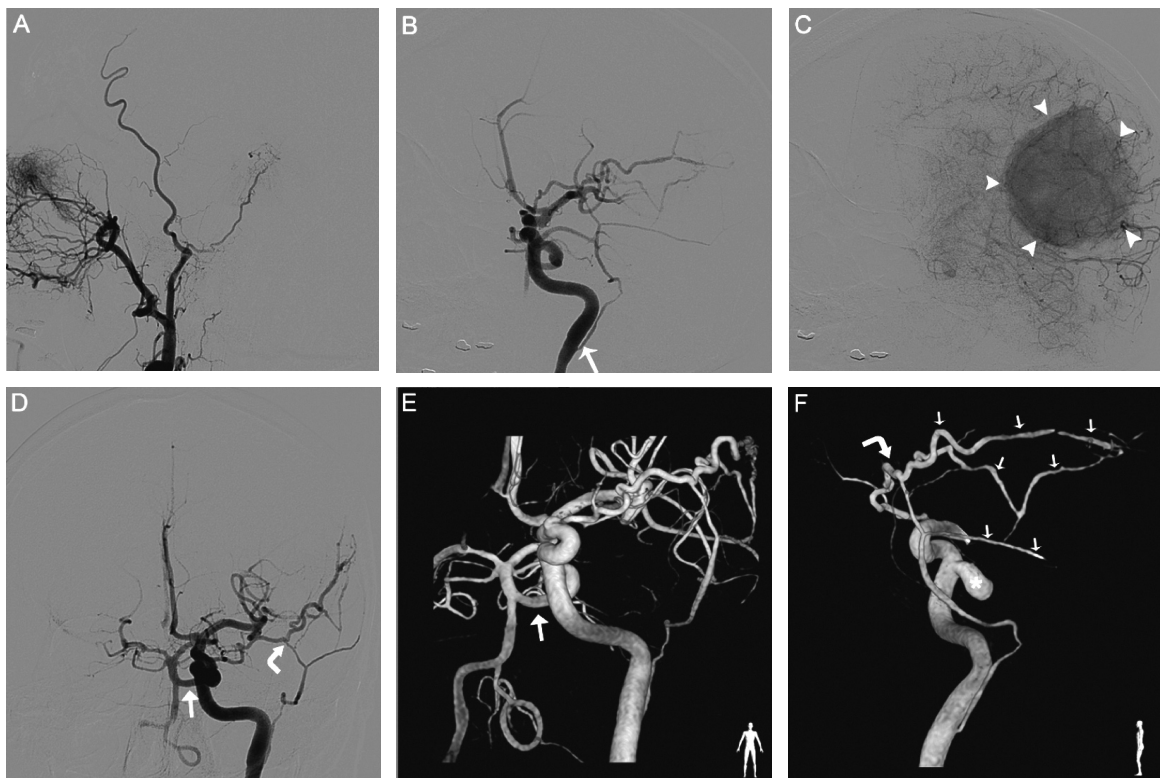
# A unique association: trigeminal and stapediaal arteries in a patient harboring a meningioma

Uma associação rara: artéria trigeminal e estapediana em paciente com meningioma

Felipe Padovani Trivelato, Marco Túlio Salles Rezende, Alexandre Cordeiro Ulhôa

A 63-year-old woman performed a magnetic resonance imaging because of persistent headache, which demonstrated a left parietal convexity tumor. A digital subtraction angiography was performed in order to plan the preoperative embolization. It showed the persistence of primitive trigeminal artery associated with the persistence of stapediaal artery<sup>1,2</sup>.

The stapediaal artery, arising from the cervical internal carotid artery, established anastomosis with the ophthalmic artery and originated the middle meningeal artery, which was responsible for the tumor supply (Figure). There is no previous report of this association in literature. The pathological findings confirmed the diagnosis of meningioma.



**Figure.** Digital subtraction angiography and 3D reconstructions. (A) middle meningeal artery lacking in external carotid angiography. (B) persistent stapediaal artery origin (arrow). (C) hypervascular blush (arrowheads). (D) trigeminal artery (arrow) and ophthalmic-stapedial anastomosis (curved arrow). (E) trigeminal artery (arrow). (F) removal of supraclinoid carotid and basilar arteries: trigeminal artery (asterisks), ophthalmic-middle meningeal (small arrows) connection (curved arrow).

## References

1. Jain R, Gandhi D, Gujar S, Mukherji SK. Case 67: Persistent stapediaal artery. *Radiology* 2004;230:413-416.
2. Willinsky R, Lasjaunias P, Berenstein A. Intracavernous branches of the internal carotid artery (ICA). Comprehensive review of their variations. *Surg Radiol Anat* 1987;9:201-215.

Interventional Neuroradiology Service - Felício Rocho Hospital, Belo Horizonte MG, Brazil.

**Correspondence:** Felipe Padovani Trivelato; Rua Timbiras 3 616; 30140-062 Belo Horizonte MG - Brasil; E-mail: felipepadovani@yahoo.com.br

**Conflict of interest:** There is no conflict of interest to declare.

Received 29 September 2011; Received in final form 13 October 2011; Accepted 20 October 2011