

Stroke due to calcific embolism after cardiac procedures

Accidente vascular decorrente de embolismo calcificado após procedimentos cardíacos

Farrukh S. Chaudhry, Daniel Vela-Duarte, José Biller

We evaluated two patients with calcific brain embolism¹. Following trans-septal cardiac catheterization, an 84-year-old woman with coronary artery disease and prior

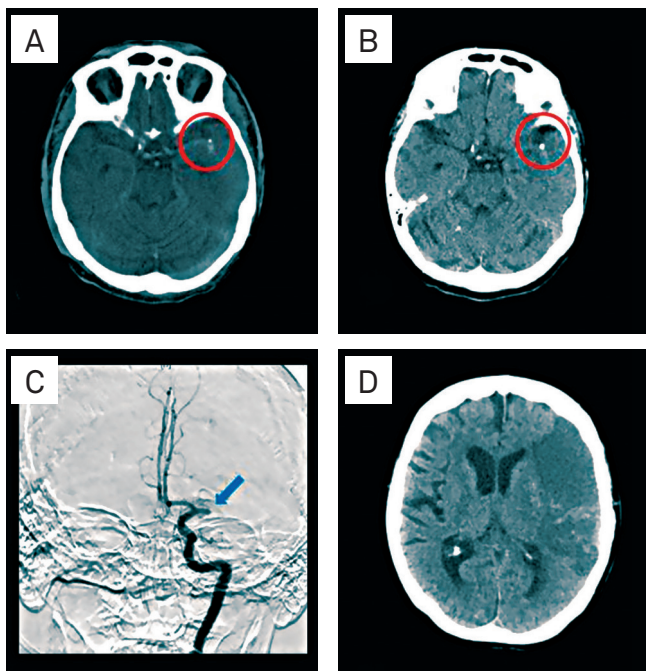


Fig 1. Computed tomography shows calcific embolus (circle) of the left middle cerebral artery (A), left middle cerebral artery calcific embolus three days after index event (B), and left internal carotid artery (ICA) injection shows occlusion (arrow) of M1 segment of the left middle cerebral artery (C). Computed tomography shows extensive left frontal-parietal area of hypoattenuation involving the superior division of the left middle cerebral artery.

mitral valve annuloplasty and bioprosthetic aortic valve replacement, had aphasia and right hemiparesis. Computed tomography (CT) showed a calcific embolus of the left middle cerebral artery (MCA) (Fig 1).

Following coronary artery bypass graft, aortic and mitral valve replacement, and patent foramen ovale closure, a 51-year-old man, had left hemiplegia and right gaze deviation. CT showed calcific embolus involving the stem of the right MCA (Fig 2).

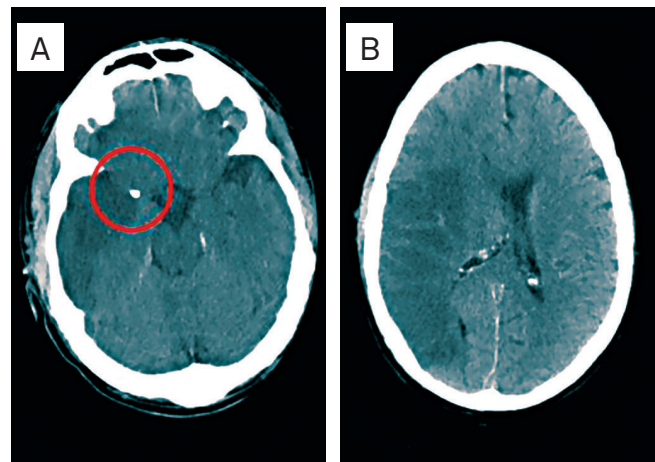


Fig 2. Computed tomography shows calcific embolus (circle) of the M1 segment of the right middle cerebral artery (A); extensive right frontal-parietal area of hypoattenuation involving the territory of the right middle cerebral artery (B).

References

1. Kirk GR, Johnson JK. Computed tomography detection of a cerebral calcific embolus following coronary catheterization. *J Neuroimaging* 1994;4:241-242.

Department of Neurology, Stritch School of Medicine, Loyola University Chicago, Chicago (IL), USA.

Correspondence: Farrukh S. Chaudhry; Loyola University Medical Center, 2160 South First Avenue, Maguire Building, Suite 2700, Maywood; IL 60181 - USA; E-mail: fchaudhry@lumc.edu

Conflict of interest: There is no conflict of interest to declare.

Received 30 January 2013; Received in final form 04 March 2013; Accepted 11 March 2013.