

Eagle's syndrome: a pain in the neck

Síndrome de Eagle: um diagnóstico difícil

Leonardo Cordenonzi Pedrosa de Albuquerque¹, Juliana Ávila Duarte², Amalia Izaura Nair Medeiros Klaes², Suelen Mandelli Mota¹, Bárbara Reis Krammer¹, Larissa Bianchini¹, Marino Muxfeldt Bianchin¹

A 60-year-old male patient was evaluated for cervical pain, hiccups, dysphonia and dysphagia for five months. Physical examination showed left IX and X cranial nerve palsy. Brain MRI was normal. A cervical CT scan showed an elongated styloid process and stylohyoid ligament pseudoarthrosis (Figure). Eagle's syndrome is a rare entity caused by

abnormal enlargement and ossification of the styloid process, the attached stylohyoid ligament and the lesser cornu of the hyoid bone^{1,2,3,4}. The condition causes variable degrees of compression of V, VII, IX, X and XII cranial nerves, and the jugular or carotid, leading to diverse symptoms^{1,2,3,4}. Eagle's syndrome pathogenesis remains unclear^{1,2,3,4}.

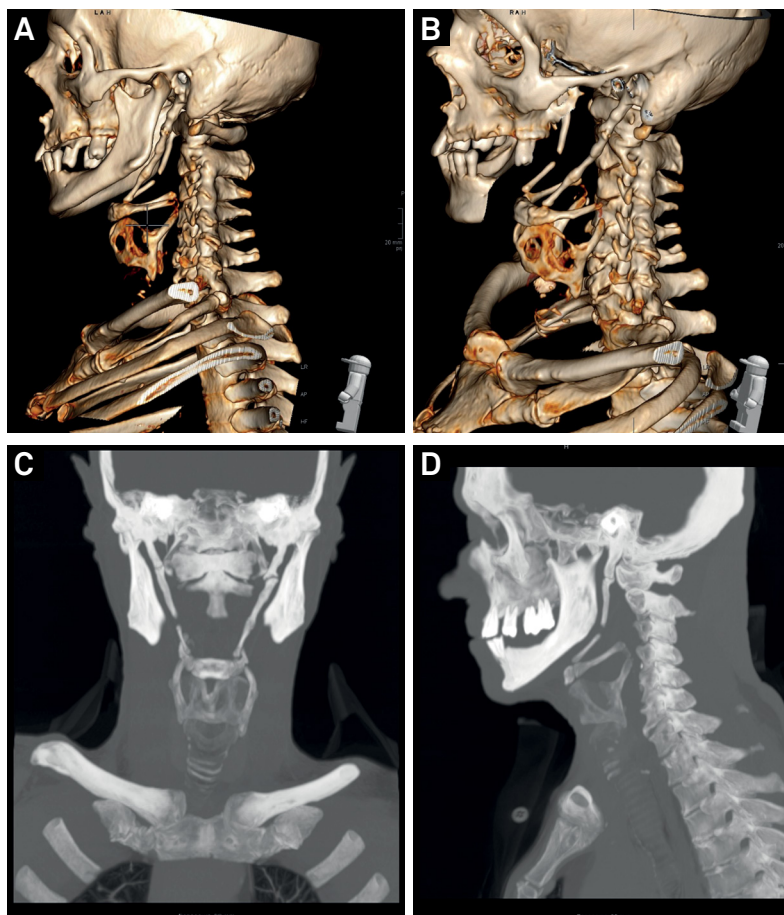


Figure. Maximum intensity projection and 3D CT-scan volume rendering of the patient's cervical region. Note bilateral calcification of the stylohyoid ligament.

¹Universidade Federal do Rio Grande do Sul, Hospital de Clínicas de Porto Alegre, Divisão de Neurologia, B.R.A.I.N. (Basic Research and Advanced Investigations in Neurology), Porto Alegre RS, Brasil;

²Hospital de Clínicas de Porto Alegre, Serviço de Radiologia e Diagnóstico por Imagem, Porto Alegre RS, Brasil.

Support: Brazilian Government research grant agencies CNPq, FAPERGS and FIPE/HCPA. Bianchin MM is further supported by CNPq (#307084/2014-0).

Correspondence: Marino M. Bianchin; B.R.A.I.N. Experimental Research Centre, Hospital de Clínicas de Porto Alegre; Rua Ramiro Barcelos, 2350; 90035-903 Porto Alegre RS, Brasil; E-mail: mbianchin@hcpa.edu.br

Conflict of interest: There is no conflict of interest to declare.

Received 17 August 2016; Accepted 10 October 2016.

References

1. Bahgat M, Bahgat Y, Bahgat A. Eagle's syndrome, a rare cause of neck pain. *BMJ Case Rep.* 2012; pii: bcr2012006278. <http://doi.org/10.1136/bcr-2012-006278>
2. Costantinides F, Vidoni G, Bodin C, Di Lenarda R. Eagle's syndrome: signs and symptoms. *Cranio.* 2013;31(1):56-60. <http://doi.org/10.1179/crn.2013.008>
3. Fusco DJ, Asteraki S, Spetzler RF. Eagle's syndrome: embryology, anatomy, and clinical management. *Acta Neurochir (Wien).* 2012;154(7):1119-26. <http://doi.org/10.1007/s00701-012-1385-2>
4. Piagkou M, Anagnostopoulou S, Kouladouros K, Piagkos G. Eagle's syndrome: a review of the literature. *Clin Anat.* 2009;22(5):545-58. <http://doi.org/10.1002/ca.20804>