

SOLITARY FIBROUS TUMOR WITH INTRACRANIAL INVASION

Leonardo C. Welling¹, José Carlos Lynch², Leandro Alcy S. Ferreira¹,
Juliano Baptista Correa¹, Mendel Sapunaru³, Wladimir Cortezzi⁴, Renata Schulz⁵

Various orbital pathological process can cause unilateral proptosis, these include a variety of neoplastic and non-neoplastic lesions. The most common cause of unilateral and bilateral proptosis is Graves's disease¹. Other common causes of proptosis are lymphomas and metastatic lesions. Less common causes include inflammatory pseudotumors, hemangiopericytomas, nerve sheath tumors, fibromatosis and meningiomas². Mesenchymal tumors of the orbit account for 5–8% orbital neoplasms. These include solitary fibrous tumors (SFT) which are benign neoplasms with uncertain histogenesis². The World Health Organization includes SFT's among mesenchymal, non-meningothelial tumors³. They have been described in the pleura⁴, skin⁵, orbit^{2,6}, paranasal sinuses and other sites. Atypical or malignant SFT's are often encountered in the thorax but extrathoracic malignant tumors are much more rare⁷. Solitary fibrous tumors occur most commonly in adults and show a slight male predominance⁸.

We present an unusual case of paranasal SFT with orbital and intracranial invasion.

CASE

A 69-year-old man had a long history of sinusitis. His symptoms has initiated one year before with a slow-growing painless swelling of the left orbit. The visual field was intact and ocular movements were preserved. CT scan revealed a mass inside etmoidal sinus with destruction of its walls, invading left orbit, with destruction of its roof and with intracranial invasion (Fig 1). The patient has been operated in two stages. The intracranial mass was approached by subfrontal extradural exposure and removed with microsurgical techniques. A irregular defect in the anterior skull base was observed. The proximity to vital structures and the limited visual field lead us to stop the surgery after the total removal of the intracranial mass and scheduled the second stage for later on. The second stage was performed through

“Le Fort III” osteotomy with a complete resection of etmoidal and orbital portion of tumor (Fig 2). An excellent recovery was observed and his proptosis resolved in one month. The histopathology revealed large collagenized areas, thick and hyalinized-walled vessels immunohistochemical testing resulted in proeminent staining for CD-34 (Fig 3).

DISCUSSION

The solitary fibrous tumor was first described as a primary spindle-cell tumor of the pleura in 1931⁹. Initially, it was thought that SFT was mesothelial in origin. However, electron microscopic and immunophenotypic investigations have shown that the SFT is myofibroblastic in nature¹⁰.

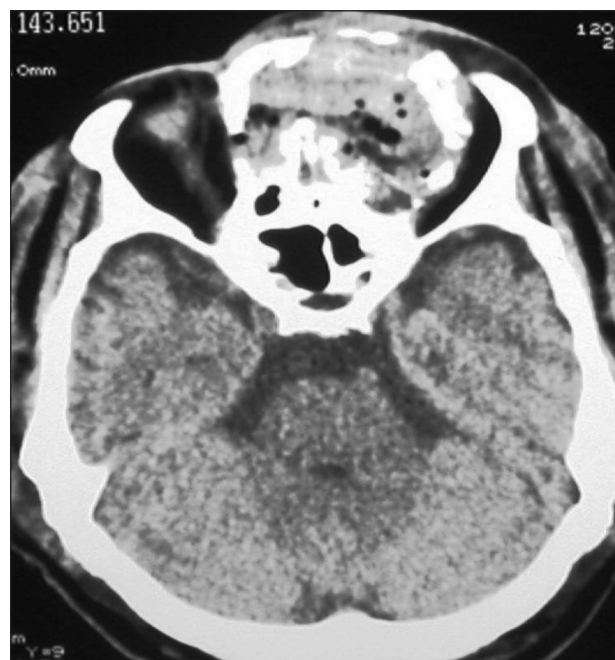

Fig 1. CT scan shows the etmoidal part of the tumor.

TUMOR SOLITARIO FIBROSO COM INVASÃO INTERCRANIANA

Serviço de Neurocirurgia do Hospital Servidores do Estado do Rio de Janeiro, Brazil (HSE – RJ); ¹Residente do Serviço de Neurocirurgia do HSE – RJ; ²Chefe do Serviço de Neurocirurgia do HSE – RJ; ³Neurocirurgião do HSE – RJ; ⁴Chefe do Serviço de Cirurgia Buco-Maxilo-Facial do HSE – RJ; ⁵Residente do Serviço de Patologia.

Received 26 January 2009, received in final form 4 May 2009. Accepted 11 May 2009.

Dr. Leonardo C. Welling – Rua Sacadura Cabral 178 - Hospital dos Servidores do Estado RJ / Serviço de Neurocirurgia / 7º andar - 20221-161 Rio de Janeiro RJ - Brasil. E-mail: leonardowellington@yahoo.com.br

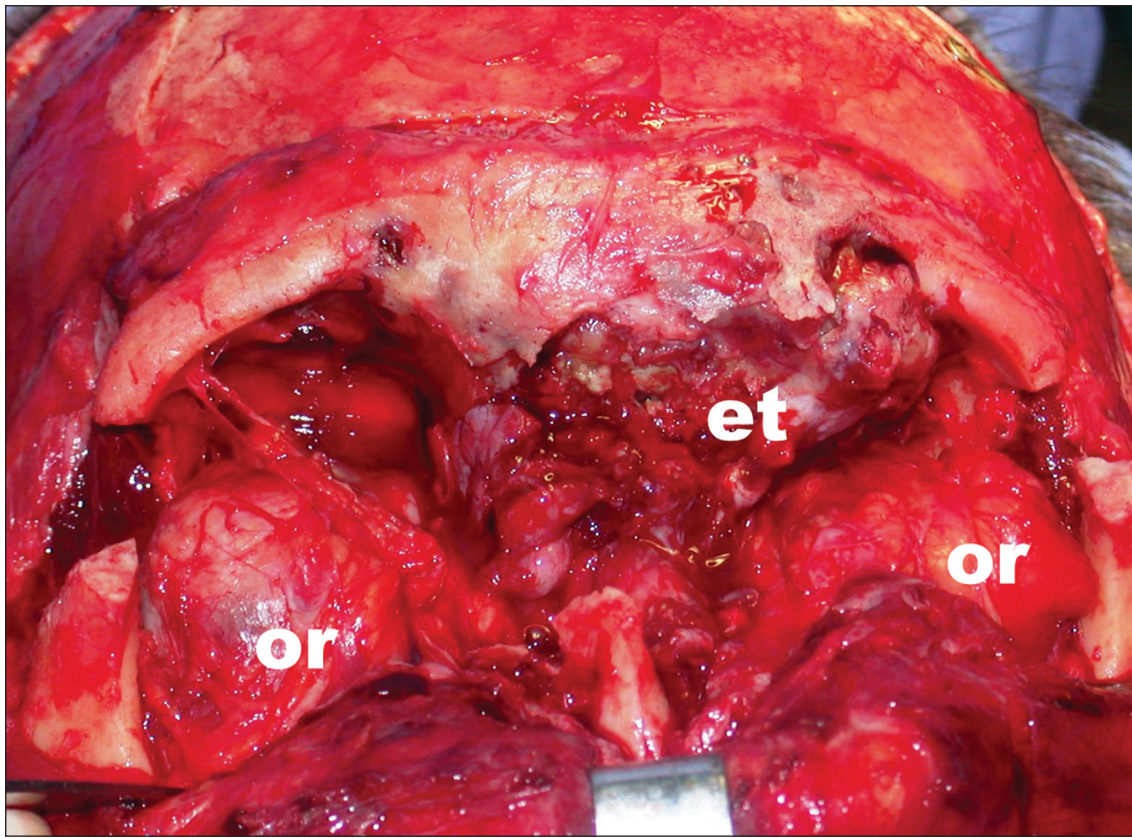


Fig 2. Le Fort III osteotomy. Etmoidal part of tumor (et), Orbit (or).

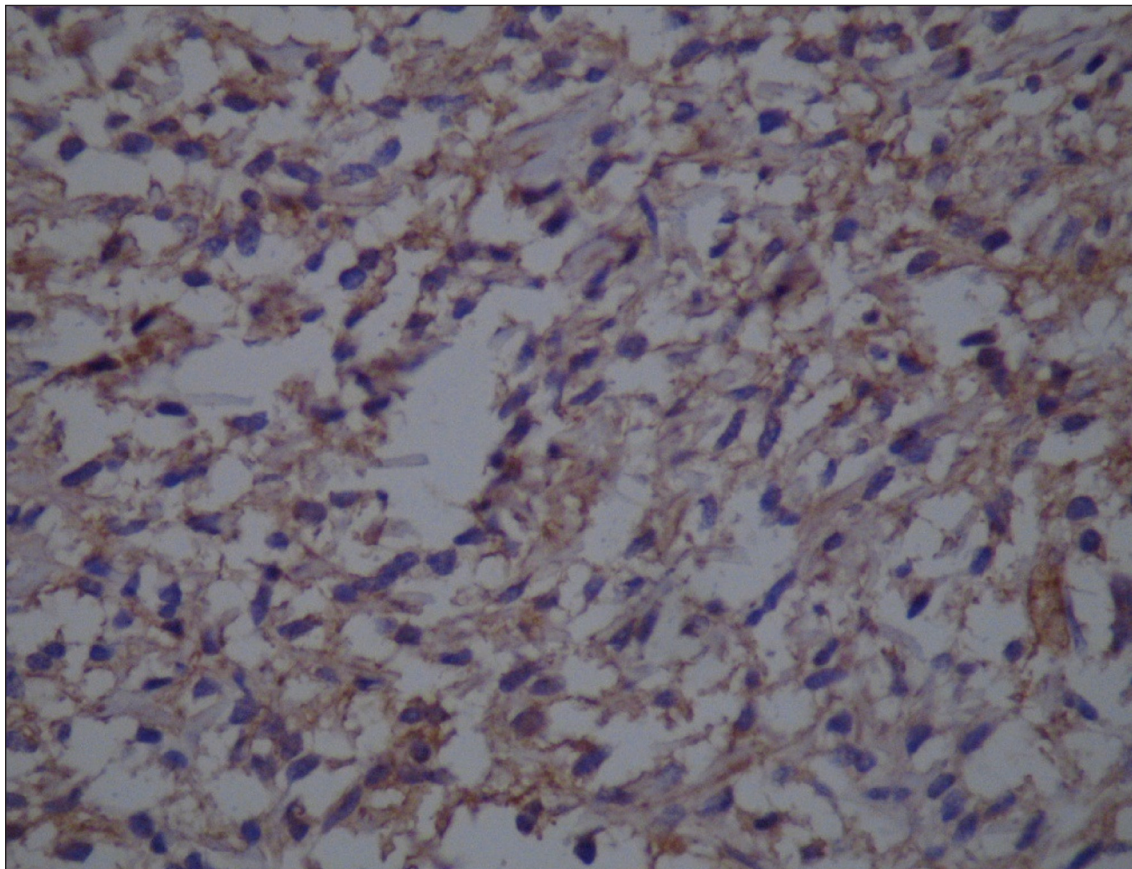


Fig 3. Immunohistochemical testing with proeminent staining for CD-34.

Nasal SFT's typically lead to nasal obstruction and also may be associated with epistaxis, rhinorrhea, anosmia, headache, facial pain and visual disturbances caused by orbital pressure⁷. As SFTs in most sites, the definitive treatment of solitary fibrous tumor is the complete tumor excision. Partially resected tumors have been noted to persist for years and recur⁶.

The majority of head and neck SFTs seem to be a benign and recurrence or metastasis rarely have been documented. Large tumor size and necrosis are also poor prognostic factors. In most reported cases the tumor cells stained positive for vimentin and CD34, and not by S-100 protein¹¹. CD 34 has in recent years been shown to be strongly and diffusely expressed in SFT's. CD 34 is not entirely specific for SFT and expresses in a variety of spindle cell neoplasms, such as dermatofibrosarcoma protuberans or neurofibromas⁸.

The most difficult distinction often is with hemangiopericytoma (HPC), which some authors consider to be a closely related tumor. While there is considerable overlap in the histologic features of these two tumors, HPC shows more diffuse vascularity with more prominent staghorn vessels. In addition, CD 34 staining is more often focal and weak in HPC whereas it is usually strong and diffuse in SFT¹².

Multiple chromosomal abnormalities, including translocations and gains of chromosomes have been reported. Further cytogenetic studies need to be carried out to identify specific chromosomal alterations to understand the biology of this tumor¹³.

In conclusion, the SFT is a benign neoplasm with uncertain histogenesis that rarely occurs in the head and neck region but it should be considered in the differential diagnosis of spindle cell lesions arising in the paranasal sinus, orbit, and invading intracranial structures.

The definitive treatment is the complete tumor excision since partially resected lesions have been noted to persist for years and recur.

REFERENCES

1. Saha S, Saha VP, Chattopadhyay S. Orbital and paraorbital tumors: clinicopathological profile and surgical management. *Indian J Otolaryngol Head Neck Surg* 2002;54:117-122.
2. Dorfman MD, King T, Dickerson GR, Rosenberg AE, Pilch BZ. Solitary fibrous tumor of the orbit. *Am J Surg Pathol* 1994;18:281-287.
3. Pakasa NM, Pasavir B, Chambonniere ML, et al. Atypical presentations of solitary fibrous tumors of the central nervous system: an analysis of unusual clinicopathological and outcome patterns in three new cases with a review of the literature. *Virchows Arch* 2005;447:81-86.
4. De Perrot M, Fischer S, Brundler MA, Sekine Y, Keshavjee S. Solitary fibrous tumors of the pleura. *Ann Thorac Surg* 2002;74:285-293.
5. Cowper SE, Kilpatrick T, Proper S, Morgan MB. Solitary fibrous tumor of the skin. *Am J Dermatopathol* 1999;21:213-219.
6. Polito F, Tosi M, Tosi P, Schurfeld K, Caporossi A. Orbital solitary fibrous tumor with aggressive behavior: three cases and review of the literature. *Graefes Arch Clin Exp Ophthalmol* 2002;240:570-574.
7. Hicks DL, Moe KS. Nasal solitary fibrous tumor arising from the anterior cranial fossa. *Skull Base* 2004;14:203-207.
8. Nikas DC, De Girolami U, Folkerth RD, Bello L, Zamani AA, Black PMcL. Parasagittal solitary fibrous tumor of the meninges: case report and review of the literature. *Acta Neurochir (Wien)* 1999;141:307-313.
9. Klemperer P, Rabin CB. Primary neoplasms of the pleura: a report of five cases. *Arch Pathol* 1931;11:385-412.
10. Cassarino DS, Auerbach A, Rushing EJ. Widely invasive solitary fibrous tumor of the sphenoid sinus, cavernous sinus and pituitary fossa. *Ann Diag Pathol* 2003;7:169-173.
11. Alawi F, Stratton D, Freedman PD. Solitary fibrous tumor of the oral soft tissues: a clinicopathologic and immunohistochemical study of 16 cases. *Am J Surg Pathol* 2001;25:900-910.
12. Perry A, Scheithauer BW, Nascimento AG. The immunophenotypic spectrum of meningeal hemangiopericytoma: a comparison with fibrous meningioma and solitary fibrous tumor of meninges. *Am J Surg Pathol* 1997;21:1354-1360.
13. Cerdá-Nicolas M, Lopes-limes C, Eil-Bensor, et al. Solitary fibrous tumor of the orbit: morphological, cytogenetic and molecular features. Case report. *Neuropathology* 2006;26:557-563.