

Complete removal of the spinal nerve sheath tumors. Surgical technics and results from a series of 30 patients

Remoção completa dos tumores da bainha dos nervos raquianos. Técnica cirúrgica e resultados de uma série de 30 pacientes

Rudi Lenck Fernandes¹, José Carlos Lynch¹, Leonardo Welling¹, Mariangela Gonçalves², Rodrigo Tragante¹, Vicente Temponi¹, Celestino Pereira¹

ABSTRACT

Objective: Observe whether a microsurgical gross total removal (GTR) of a spinal nerve sheath tumors (SNSTs) is safe and decreases the tumor recurrence. **Method:** We identify 30 patients with 44 SNSTs. **Results:** We operated upon 15 males and 15 females patients; mean age 40 years. GTR was achieved in 29 (96.6%) instances. Surgical mortality was 3.3% and the recurrence rate was 3.3%. The median follow-up time was 6.2 years. **Conclusion:** The surgical approach used in this group of patients afford that the great majority of tumors could be totally removed with low mortality and low recurrence rates, proving to be safe and effective.

Keywords: microsurgery, neurofibroma, schwannoma, spinal nerve sheath tumors, surgical treatment.

RESUMO

Objetivo: Observar se a ressecção microcirúrgica completa dos schwannomas ou neurofibromas raquianos é uma técnica segura e efetiva. **Método:** Foram operados 30 pacientes com 44 schwannomas ou neurofibromas intrarraquiano. **Resultados:** A remoção total da lesão ocorreu em 27 casos (96.6%). A taxa de mortalidade cirúrgica observada nesta série foi de 3.3%. O tempo médio de seguimento foi de 6.2 anos. **Conclusão:** A estratégia microcirúrgica empregada com esses pacientes propiciou a remoção total dos tumores na maioria dos pacientes, com baixa mortalidade e recidiva tumoral, mostrando ser segura e efetiva.

Palavras-chave: microcirurgia, neoplasia raquiana, neurofibroma, tumores da bainha dos nervos, schwannoma raquiano.

The annual incidence rates for primary spinal neoplasms are reported to be in the range of 1.3 to 10.0 per 100,000¹. One-third is nerve sheath tumors^{1,2,3}. The spinal nerve sheath tumors (SNSTs) comprise the schwannomas and neurofibromas^{1,2,3,4}. Nevertheless little attention has been paid to this subject within Brazilian settings, which motivated us to review and present the cases of this pathological condition treated by our medical team, and to assess the safety and efficiency of microsurgical removal of those lesions.

Various terms have been used for this tumor: neuroma, neurinoma, neurilemoma, perineurial fibroblastoma, schwannoma gliome peripherique, schwannoma and neurofibroma^{2,4}. The SNSTs are benign, usually solitary, slow-growing, encapsulated neoplasms composed of differentiated neoplastic Schwann cells. The most common origin of these tumors is the posterior spinal nerve root^{1,2,3,4,5,6}.

METHOD

Data collection

The 30 patients registered in this retrospective study with SNSTs were operated at the *Hospital Federal dos Servidores do Estado* (RJ) and at *Rede D'Or São Luiz* between 1986 and 2012. The medical charts, pre and postoperative imaging, and pathological reports were retrospectively reviewed for each patient to confirm the diagnosis of SNSTs; creating a database from which information pertinent to the present study was collected. The intraoperative videos of 11 patients were analyzed for nuances of the microsurgical technique. The need for informed consent was waived due to the retrospective character of the study. Detailed neurological examinations were performed in the neurosurgery and/or neurology department. Radiographs

¹Departamento de Neurocirurgia, Hospital Federal dos Servidores do Estado, Rio de Janeiro RJ, Brazil;

²Rede D'Or São Luiz, Rio de Janeiro RJ, Brazil.

Correspondence: José Carlos Lynch; Rua Jardim Botânico 600, sala 605; 22461-000. Rio de Janeiro, RJ, Brasil; E-mail: cneuroamericas@uol.com.br

Conflict of interest: There is no conflict of interest to declare.

Received 15 October 2013; Received in final form 09 December 2013; Accepted 06 January 2014.

(XRs), computed tomography (CTs) and magnetic resonance imaging (MRIs) scans were reviewed with the radiology department. The postoperative images controls were done at hospital discharge and with 3 and/or by 12 months follow-up. Neurophysiological monitoring was not routinely used in this series.

Surgical technique

In all cases the same microsurgery technique was used following these general steps: After intubation, and appropriate arterial and venous access, the patient is turned to the prone position. The neck is maintained in a slightly flexed position with a Mayfield head clamp for the cervical lesions and high thoracic lesions and resting in the horseshoe for tumors in others locations. The involved spine region was shaved, prepared, and draped in a sterile fashion. The procedure starts with the use of a 4.5x loupe and co-axial lightning.

Exposing : A rectilinear midline incision is made starting in the superior level of the tumor and extending to the inferior level. In the cases that we are planning a partial laminectomy, the skin incision is being place about 2 cm lateral of midline. The thoracolumbar fascia is opened in the midline with a 10 scalpel; the paravertebral muscles are subperiostally desinserted and laterally retracted with a periosteum elevator. A unilateral subperiosteally exposure of the posterior spinal elements is performed only in the affected side. A bilateral muscle dissection is performed if the tumor is bilateral situated. The exposure is maintained with the appropriate autostatic retractors. At this point, the spinous processes and laminae of the involved level were well visualized. In small tumors, laminectomy can be limited to one single vertebral level and also limited to one side. Drilling does not need to be performed beyond the midline. That is done with the aid of air drill using cutting and/or diamond burr of 2 to 5 mm diameter. Laksell rongeur and Kerrinson forceps are also employed to finish the bone work. If the tumor is a dumbbell shape, a unilateral facetectomy and foraminotomy must be necessary. During the whole procedure, careful hemostasis is obtained with bipolar forceps to keep the field bloodless and to prevent adhesions that can be induced around the spilled blood. At this moment, the surgical microscope is introduced in the field. The dura mater is sectioned in the midline with a 15 blade. The free border of the dura mater is sutured, using 4.0 threads, in the paravertebral musculature.

Removing the lesion: In most of the cases, the lesion can be identified under the arachnoidal membrane. The arachnoidal covering the nerves roots is then opened in the posterior aspect of the exposure with micro scissors and gently dissected from the tumor surface to the sides using micro-surgery instruments and left intact to protect de

medulla and roots from the surgical dissection. At this point, the tumor is brought completely to view and a high magnification of the operating microscope is to be beneficial. The border between the tumor and ventral nerves roots and or spinal cord is established and the roots are protected with small cottonoids that are placed between the tumor and the roots. The surface of the schwannoma is coagulated with a low voltage bipolar under continue saline irrigation and sectioned with micro scissors. The interior of the lesion is penetrated and progressive debulked. After this, the tumor is shrunk and can be rolled on and we can visualize and identify with certainty the proximal root that originated the tumor that is cut with micro scissors. The surgeon should be aware, that in large lesions several roots appear to give origin to the tumor, these passage roots should be spared. When dealing with large lesions, that compress and deform the spinal cord or/and the roots, these tumors should be dissect from and not against the cord, and when free of adhesions, remove from the surgical field. We only attempted en block resection in small tumors that came out easily, without traction or compression of neural structures. After removing the tumor, the subarachnoid space is carefully irrigated and the involved nerves roots are brought to this normal position. At this point, the blood pressure should return to his normal levels. The dura is closed in a water tight fashion. Biological glue is added on the suturing line.

The suture of paravertebral musculature and fascia is performed in 3 planes to prevent muscle atrophy and residual pain; the skin is sutured with 3.0 nylon.

ILUSTRATIVE CASES

Case 1

A 61-year-old woman came to our attention complaining of backache and irradiating pain to the anterior aspect of the left thigh for 6-month duration. The neurological examination where within normal limits, with the exception of a mild paresis of the extension of the left thigh. She did not exhibit signs compatible with neurofibromatosis. MRI depicted a dumbbell shape lesion involving from the 3th to the 4th lumbar vertebrae with intense enhancement. (Figure 1A) The lesion was completely removed via a unilateral laminectomy and facetectomy. (Figure 1B) During the early postoperative period the patient developed a neuropathic pain that disappeared completely after 3 months.

Case 2

A 55-years-old man complained of intense flash pain in the posterior aspect of his right leg with irradiation to the foot when he stands up, for 2 months duration. The neurological examination was completely normal. Axial enhanced

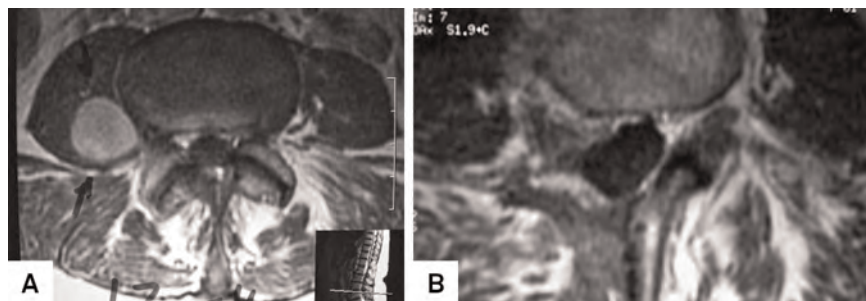


Figure 1. Case 1. Preoperative axial enhanced T1 MR imaging demonstrating a medium size left dumbbell L3-L4 schwannoma (A). Postoperative axial enhanced T1 imaging demonstrating total removal of the tumor and postoperative changes (B).

T1 MRI demonstrated a medium size intradural L4 schwannoma. (Figure 2A) We obtained GTR using microsurgical techniques and a L4 hemilaminectomy. (Figure 2B) The postoperative was uneventful and he was pain relieved.

RESULTS

To the best of our knowledge, this is the largest series of SNSTs published in Brazil. As this is a retrospective study, it has inherent biases and drawbacks that only a multicenter, prospective study can overcome. This sample is composed of 15 (50%) females and 15 males (50%) and 44 SNSTs; ranging from 8 to 70 years (mean 40 years). We detected 2 cases with obvious features of Recklinghausen's disease. The patient's demographics and clinical characteristics are summarized in the Table 1.

Clinical outcome: In our series, one surgical death (3.3%) occurred. During the follow up period, three individuals died. One patient present with lumbar melanotic SNST. It was completely removed but recurred in the pelvic region. She died 2 years after surgery despite adjuvant therapy. Another death was of a 16-years-old boy with Neurofibromatosis 2 (NF-2). He presented almost completely paraplegic, with approximately 30 tumors located in several levels of the spinal cord. We removed 2 dumbbell C2 Schwannomas involving both sensory and motor rootlets

with critical compression of the spinal-medullary junction. (Figure 3A and 3B) He improved and was discharged home stable, but unfortunately, 3 months later, he was admitted to another hospital with acute respiratory distress and died due from aspiration pneumonia and sepsis. The third patient present with a rare intramedullary schwannoma, he was paraplegic at admission, with sphincters compromise. He did not improve after surgery and died two years later due to repetitive urinary tract infection. Four patients were lost in the follow up and were not included in this study. We detected a single tumor recurrence that was reoperated with good result. At the time of the last follow-up, 25 (82.3%) patients were alive. Excellent or good outcome was achieved in 24 patients (80%). Temporary postoperative complications including infection, CSF fistula, deep venous thrombosis, and pulmonary complications, occurred in 4 patients (10%).

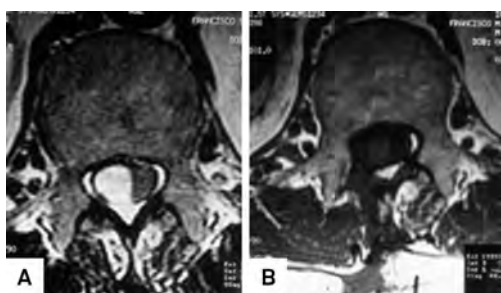


Figure 2. Case 2: Preoperative axial enhanced T1 MR imaging demonstrating a medium size right intradural L4 schwannoma (A). Postoperative axial enhanced T1 imaging demonstrating completed removal of the tumor through a hemilaminectomy (B).

Table 1. Characteristics of 30 patients treated with spinal nerve sheet tumors.

Age at treatment	8 to 70 years (mean 40.6 years)
Female	15(50%)
Male	15(50%)
NF 2	2 (6.6%)
Clinical-neurological picture	
Duration of symptoms	10 day to 2 years (mean, 8.4 months)
Radicular pain	14 (46%)
Motor deficit	12 (40%)
Axial pain	6 (20%)
Follow up	1 to 26 years (mean, 6.2 years)
Location	
Lumbar	11(36.6%)
Thoracic	10(33.3%)
Cervical	7(23.3%)
Two segments	2(6.6)
Multiple lesions	6(20%)
Histology	
Schwannoma	24(80%)
Neurofibroma	6(20%)
Follow-up	from 1 to 26 years (mean, 6.2 years)
Surgical mortality	1 (3.3%)
Gross total removal	29 (96.6%)
Recurrence	1(3.3%)

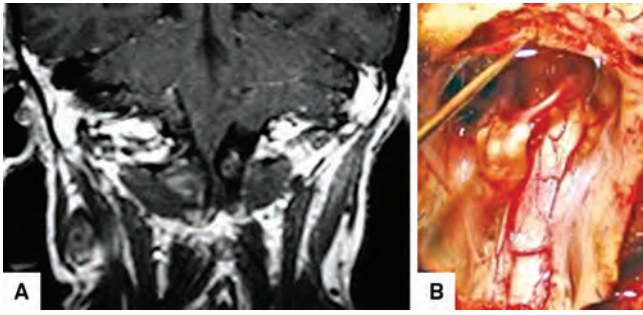


Figure 3. Preoperative coronal axial enhanced T1 MR revealing 2 lesions like mirror-image C-2 neurofibromas (arrows) in a patient with NF2 (A). Intra operative image of the two lesions before removal (B).

Extension of resection and recurrence

Gross total removal (GTR) was achieved in 29 (96.6%) patients, confirmed by surgeon impression and/or post-operative images. GTR was obtained through a laminectomy for large lesions or a hemilaminectomy in 9 patients (26.6%) with small or middle size tumors (Figures 1A, 1B, 2A and 2B).

Recurrence was observed once (3.3%); reoperation was performed 2.5 years later, with complete tumoral resection. In 28 patients, the root that originated the lesion could not be separated from the tumor and was divided. Eight patients noticed persistence of mild radicular deficits that did not cause any disturbance in their routine lives. Surgery in the spinal canal may cause atrophy of the cord or arachnoiditis. This was seen in one patient.

DISCUSSION

To the best of our knowledge, this is the largest series of SNSTs published in Brazil. As this is a retrospective study, it

has inherent biases and drawbacks that only a multicenter, prospective study can overcome. The age distributions in our study and that by Seppälä et al.¹ were similar, with a peak incidence between 40 and 60 years of age,^{2,3,6,7}. Like in the present study, previously authors had reported equal incidence in males and females¹. Our study confirms that axial or radiating pain is the most common presenting symptom in patients with SNST^{1,2,3,4,5,6,7}. Similar to others published series, in our sample, the duration of symptoms also varied widely, ranging from a few days to many years¹⁻⁶. This paper confirms that most SNSTs are located intradural, followed by dumbbell shape and extradural locations¹⁻⁷. The size of SNST varies from a small intradural tumor involving a single rootlet to a large mass involving several motors and sensory roots^{1,2,3,4,5,6,7}. (Figure 4A, 4B and 4C) A conventional laminectomy or partial laminectomy was sufficient for the treatment of most lesions as proposed by several surgeons^{1,2,6}. In case of intradural-extradural and large extradural tumors, a laminotomy was combined with unilateral partial facetectomy².

Mortality, gross total tumor removal and recurrence

The mortality in surgery of SNSs is usually low. In published series it's varies from zero to 6%^{1,2,3,4,5,6,7}. The operative mortality in our sample was 3.6% (1 case). A GTR was achieved in 29 (96.6%) instances. Others authors have reported results for GTR that varies from to 85 to 97.2%^{1,2,3,4,5,6,7,8}. Klekamp and Samii⁸ observed overall recurrence rates of 10.7% after 5 years and 28.2% after 10 years of follow-up, respectively and concluded that: partial removal, surgery of a recurrent tumor, NF-2, and old age predisposed for tumor recurrence. Matti T et al.⁵ study demonstrates that 50% of a subtotal removed tumor (STR) showed a clinical recurrence. Seppala et al¹ reported 20

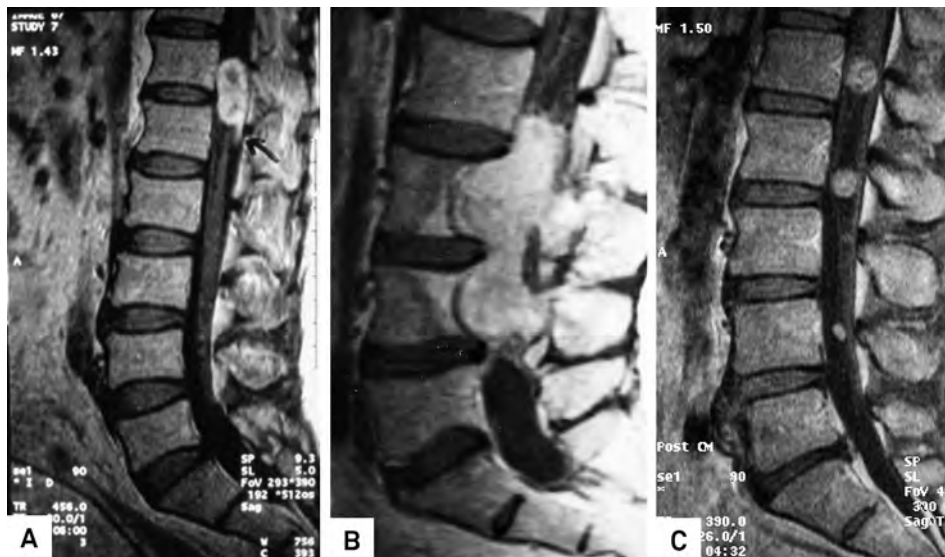

Figure 4. Examples: small schwannoma (A); large lesion with bone erosion and cystic formation (B); and multiples schwannomas (C).

Table 2. Summary of the main surgical series on spinal nerve sheet tumors.

Author/ year	N Cases	GTR(%)	Mort. (%)	Rec. (%)	F/U (years)
Abanese et al. ^{3/} 2002	41	94	6	N/A	5
Jeon JH et al. ^{6/} 2008	38	85	0	5.0	N/A
Contti P et al. ^{7/} 2004	152	97.2	1.3	1.9	N/A
Seppala et al. ^{1/} 1995	187	89.3	1.6	5.8	12.9
Safavi et al. ^{2/} 2008	128	97	0	3.9	4.2
Celli P et al. ^{13/} 2005	24	95.5	0	4.1	9
Current series	30	96.6	3.3	3.3	6.2

GTR: gross total removal; Mort.: mortality; Rec.: recurrence; F/U: follow up; N/A: not available.

patients in whom STR was performed, recurrence in this group was verified in 55% of the cases. On the other hand, Safavi-Abbasi et al.² reported that all patients in whom a tumor recurred had initially undergone GTR, and none of the patients undergoing STR had tumor recurrence. We believed that, probably, in this particular situation the surgeon did not recognize a small piece of tumor left behind and during the follow up this piece of tumor recurred. Hasegawa et al.⁹ found that no clear margin could be found between the capsule and tumor tissue in most of these tumors. They stated that resection of the nerve of tumor origin rather than enucleation would be justified to avoid tumor recurrence. In our material, we observed only one (3.6%) tumor recurrence. (Table 2) Thus, it seems to us that in SNSTs the goal of the treatment is GTR in the first surgery even with the sacrifice of the involved nerve root, to avoid recurrence and obtain the cure of the patient^{1,2,6,7}.

Sacrifice of the nerve root

Kim et al.⁴ and others^{2,9,10,11,12} reported that sacrifice of the nerve root do not always result in postoperative neurological deficits, and when it occurs, is usually a minor deficit. These facts indicate that the spinal roots giving origin to schwannoma are frequently nonfunctional at the time of surgery, and risks of causing disabling neurological deficit after sacrificing these roots are very small^{2,4,9,12}.

The preservation of the anatomical continuity and should be attempted in functional roots like C5 and S1², although this may be feasible only in cases of small tumors. Complete removal of larger tumors is often impossible without sacrificing the nerve root. Celli¹³ believed that some factors seem to influence the risk of neurological sequel after sectioning of the root, such as the neurofibroma pattern, preoperative weakness of the involved root, and intra-extradural tumors.

Surgical nuances

Surgeons must be aware, that in large lesions, in the initial steps of dissection, several roots appear to give origin to

the tumor, similar to the passages vessels in the brain's arteriovenous malformation, and of course, these roots should be spared. We only attempted in block resection in very small tumors that can be safely removed, without traction or compression of neural structures. (Figure 4A) Taking this aforementioned precautions, we and several authors advocated that GTR should always be attempted at the first surgery to prevent recurrence and cure the patient^{1,2,6,7,13} (Figure 1 and 2) However if subtotal removal has been performed, the patients need to be followed closely^{1,2,6}. In case of dumbbell tumors, most of them can be removed by a single posterior approach^{14,15}. When the tumor extends <1 cm out of the intervertebral foramen, it is possible to preserve the facet. For a tumor that extends 2 cm or more out of the foramen, it seems best to remove the facet¹⁴.

We consider a unilateral laminectomy as minimal-access approach that provides a minimally invasive removal of the tumor, reducing blood loss, the immediate postoperative pain, and length of stay in comparison with unnecessary multi levels laminectomy. The hemilaminectomy was accomplished in 8 patients (26.6%) of this series with medium or small size tumors, if the interspinous ligament is left intact, and if the patient already has moderate degenerative change, fusion might not be necessary but follow-up evaluations nevertheless are needed^{6,14,15}.

We are in agreement with the authors who claim that as schwannomas are located in different sites and locations, they may be small, large or multiples; (Figures 4A, 4B and 4C) these differences require different surgical approaches^{16,17,18}.

In conclusion, based in our experience on 30 patients with 44 SNST, operated upon using microsurgical techniques and a limited laminectomy, it is a safe method, with low mortality and morbidity. Our study advocated that GTR in SNSTs is feasible in most of the cases but the sacrifice of the nerve root involved by the lesion is frequently necessary, although the risks of causing disabling neurological deficit after sacrificing these roots are very small. In this series we observed only one case (3.6%) of recurrence.

References

1. Seppala MT, Haltia MJ, Sankila RJ, Jääskeläinen JE, Heiskanen O. Long-term outcome after removal of spinal neurofibroma: a clinicalpathological study of 187 cases. *J Neurosurg* 1995;83:621-626.

2. Safavi-Abbasi S, Senoglu M, Theodore N, et al. Microsurgical management of spinal schwannomas: evaluation of 128 cases. *J Neurosurg Spine* 2008;9:40-47.
3. Albanese V, Platania N. Spinal intradural extramedullary tumors. Personal experience. *J Neurosurg Sci* 2002;46:18-24.
4. Kim P, Ebersold MJ, Onofrio BM, Quast LM. Surgery of spinal nerve schwannoma. Risk of neurological deficit after resection of involved root. *J Neurosurg* 1989;71:810-814.
5. Seppälä MT, Haltia MJ, Sankila RJ, Jääskeläinen JE, Heiskanen O. Long-term outcome after removal of spinal neurofibroma. *J Neurosurg* 1995;82:572-577.
6. Jeon JH, Hwang HS, Jeong JH, Park SH, Moon JG, Kim CH. Spinal Schwannoma; Analysis of 40 Cases. *J Korean Neurosurg Soc* 2008;43:135-138.
7. Conti P, Pansini G, Mouchaty H, Capuano C, Conti R. Spinal neurinomas: retrospective analysis and long-term outcome of 179 consecutively operated cases and review of the literature. *Surg Neurol* 2004;61:34-43.
8. Klekamp J, Samii M. Surgery of spinal nerve sheath tumors with special reference to neurofibromatosis. *Neurosurg* 1998;42:279-290.
9. Hasegawa M, Fujisawa H, Hayashi Y, Tachibana O, Kida S, Yamashita J. Surgical pathology of spinal schwannoma: has the nerve of its origin been preserved or already degenerated during tumor growth? *Clin Neuropathol* 2005;24:19-25.
10. Halliday AL, Sobel RA, Martuza RL. Benign spinal nerve sheath tumors: their occurrence sporadically and in neurofibromatosis types 1 and 2. *J Neurosurg* 1991;74:248-253.
11. Jinnai T, Koyama T. Clinical characteristics of spinal nerves sheath tumors: analysis of 149 cases. *Neurosurg* 2008;56:510-515.
12. Schultheiss R, Gullotta G. Resection of relevant nerve roots in surgery of spinal neurinomas without persisting neurological deficit. *Acta Neurochir (Wien)* 1993;122:91-96.
13. Celli P. Treatment of relevant nerve roots involving nerves sheath tumors: removal or preservation? *Neurosurg* 2002;51:684-692.
14. McCormick PC. Surgical Management of Dumbbell Tumors of the Cervical Spine. *Neurosurg* 1996;38:294-300
15. Thorat JD, Rajendra T, Thirugnanam A, Ng IH. Single-stage posterior midline approach for dumbbell tumors of the thoracic spine, with intraoperative CT guidance. *Surg Neurol Int* 2011;2:31-35.
16. Lot G, Bernard G. Cervical Neuromas with extradural components: surgical management in a series of 57 patients. *Neurosurg* 1997;41:813-822.
17. Falavigna A1, Righesso NO, Teles AR, Ruschel L, da Silva PG. Abordagem cirúrgica posterior e posterolateral para neurinomas cervicais em ampulheta da raiz de C2. *Coluna* 2010;9:157-166.
18. Prevedello DM, Koerbel A, Tatsui CE, et al. Fatores prognósticos no tratamento dos tumores intradurais extramedulares. *Arq Neuropsiquiatr* 2003;61:241-247