

# SOMATOSENSORY EVOKED RESPONSE

## APPLICATION IN NEUROLOGY

*CARLOS A. M. GUERREIRO \**

*BRUCE L. EHRENBERG \*\**

Evoked potentials have substantially enhanced the diagnostic power of clinical neurophysiology in much the same way that computerized tomography (CT) has changed the outlook of neuroradiology. The short-latency somatosensory evoked response (SER) allows one to assess the conduction velocity in the "large-fiber" sensory pathways from the periphery to the cortex.

The SER, produced by electric stimulation of the median nerve, is the record of electrical activity travelling in the brachial plexus, the C6-7 roots, the cervical spinal cord, the brainstem lemniscal system, the thalamus, and the sensory cortex. The same technique can be applied to any other sensory nerves including peroneal, ulnar and various cranial nerves, but none of these is yet as well studied as the median nerve. These tests were made possible after development of computers capable of extracting the evoked response from the background noise (EEG, muscle artifacts).

As with the brainstem auditory evoked response (BAER), the most useful part of the SER consists of waveforms appearing less than 30 milliseconds (msec) after stimulation and therefore named short-latency evoked potentials.

The SER permits an evaluation of the responsivity of certain structures at different levels of the neuraxis and it can demonstrate a localized blockage or slowing of conduction. Since it can evaluate brainstem tracts that are medial to the auditory pathways, the SER complements the BAER in the localization of brainstem lesion. These waveforms are consistently reproducible, easy to obtain, and they do not change with drowsiness, anesthesia or doses of barbiturates sufficient to cause severe coma.

The present article reviews the basic procedures, the normal responses, the probable anatomical pathways involved, the abnormal findings, indications and value of the SER.

---

\* Fellow in Clinical Neurophysiology at Tufts-New England Medical Center (T-NEMC), Boston, Massachusetts, USA; Assistant Professor of Neurology at Campinas University (UNICAMP), São Paulo, Brazil.

\*\* Director of Clinical Neurophysiology, T-NEMAC, Boston, MA., USA.

*Acknowledgement:* This paper was partially supported by funds of Fundação de Amparo à Pesquisa do Estado de São Paulo. (FAPESP).

### TECHNICAL CONSIDERATIONS

Several technical procedures and different nomenclature are available in the literature 2,7,9,10,14,16,18,19. We use basically the same method as Chiappa 7 with some modifications. The test is done with the individual in the supine position. Sedation and sleep are encouraged for decreasing muscle artifacts. A unilateral surface electrode stimulates the median nerve at the carpal tunnel at 4.7/second using a 200 microsecond electrical square wave with a constant current of 5 to 15 milliamperes. Stimuli are below pain level and are adjusted to produce a minimal thumb twitch. The ground is a flexible metal strip covered with saline soaked cloth, wrapped circumferentially around the limb proximal to the site of stimulation. Electrodes are attached to the skin with collodion and filled with electrolytic paste to obtain an impedance of 3000 ohms or less. Electrodes are placed, according to the International 10-20 system, at the standard mid-frontal location (Fz), at a point half way between C3 and P3 (C3') and between C4 and P4 (C4') for approximation of the somatosensory cortex. Electrodes are also placed in the midline over the CII and CVII vertebrae, and on each supra-clavicular fossa over the brachial plexus at Erb's point. Four derivations are used: channel 1: Fz-C3' or C4' (whichever is contralateral to the stimulated median nerve); channel 2: Fz-CII; channel 3: Fz-CVII (or more recently we are using a bipolar derivation CII-CVII); channel 4: Fz-ERB (ipsilateral to the stimulated median nerve). The signals are amplified 50,000 or 100,000 times using EEG filters set for a 3-3KHz bandpass (50% down points). A total of 50 msec is averaged over 1024 or 2048 trials, twice for each side. The averaging process is displayed on an oscilloscope and the final result is recorded on an X-Y plotter. The whole procedure takes about an hour.

### RESULTS AND INTERPRETATION

A normal SER is shown in figure 1. Note, in the different derivations, the N2-P2 response (channel 1), the "B" wave (channel 2), the "A" wave (channel 3), and the Erb's point (EP) response (channel 4). The terminology used is from Chiappa 7. Note that in our method, the "A" wave separates from the "B" wave in the bipolar derivation. Absolute latency is determined from the stimulus to the peak of each wave. Interpeak latency is measured between two wave peaks. Amplitudes are measured baseline to peak or peak to peak (N2-P2). Our normative data do not differ from those of Chiappa 7. The most useful normal data comes from the interpeak latency in relation to the EP wave. This bypasses latency deficits due to limb length, limb temperature or peripheral neuropathies.

The following are the means ( $\bar{x}$ ) and standard deviations (SD) for the interpeak latencies from EP (in msec): EP - A = 2.1 (SD = 0.3); EP - B = 4.1 (SD = 0.2); EP - N2 = 9.4 (SD = 0.4); and EP - P2 = 12.3 (SD = 0.7). Waves B, N2 and P2 are seen in all normal controls. The EP response ( $\bar{x}$  = 9.7 msec) represents the ascending volley through median nerve and brachial plexus 16. The A wave ( $\bar{x}$  = 11.8 msec) probably represents dorsal root or posterior column potentials. It is not always useful clinically since it can be absent in normal subjects. The B wave ( $\bar{x}$  = 13.7

msec) may be bi or trilobed. In the latter case the mid-point is considered the peak. There is some controversy in the literature about the origin of this potential. Some authors think it arises from the dorsal column nuclei 7,14,16 and others from the medial lemniscus or thalamus 1,2,14,26. Data from medullary intra-operative recording by Ehrenberg and Guerreiro (to be published elsewhere) suggest a lower medullary origin (probably the cuneate nuclei) for the B wave. Reported clinical cases 19,23 support this idea as well as thalamic recording in humans following median nerve stimulation 5.

Many investigators think N2 ( $\bar{x} = 19.1$  msec) originates in the primary receptive field of the sensory cortex 1,14,16,18,21. Chiappa believes that this potential is generated at the thalamus. We have well-documented cases supporting Chiappa's view (example case 2). It is generally accepted that P2 arises within the sensory cortex. The criteria for abnormalities are primarily based on an interpeak latency greater than 3.0 SD above the mean. Amplitudes have a broad normal range, but sometimes are useful indicator.

#### CASES FOR ILLUSTRATION

*Case 1* — Normal adult (figure 1).

*Case 2* — A 42 year old female with acute onset of weakness and pins and needles sensation in the left face, arm and leg. Past history of heavy cigarette smoking, birth control pill usage for 13 years and migraines monthly on the first day of her menses. One month prior to study, malaise, photosensitivity and Raynaud's phenomenon occurred. Physical examination was unremarkable. Neurologic examination showed a mild complete left hemiparesis with mild left hyperreflexia. Sensation revealed normal vibration sense, but pinprick, light touch and position were diminished on the left side. Laboratory work-up was compatible with systemic lupus erythematosus. CT scan on admission was normal. SER is seen in figure 2. A repeat CT-scan after one week showed a definite right thalamic infarction which did enhance with contrast. Left and right carotid and left vertebral angiogram revealed a complete blockage of the right posterior cerebral artery.

*Case 3* — A 27 year old female who was referred to the New England Medical Center with a diagnosis of retrobulbar neuritis. Five days prior to her admission she developed pain behind the right eye and began seeing dots and a shade covering her visual field. Several years before she started to feel numbness in the fingertips of both hands and this remains unchanged. She also complained of a deteriorating memory for three years. Examination revealed a visual acuity of 20/50 on the right and 20/15 on the left. The fundi were normal. Visual confrontation fields showed a constriction on the right. Cranial nerves, motor and cerebellar examinations were normal. Sensory exam revealed inconsistent findings to pinprick and touch, without a reproducible level. There was vibratory hypesthesia to the ankles bilaterally. Her work-up included a normal cerebrospinal fluid, electrophoresis and gamma globulin level. The CT-scan was normal. Pattern shift visual evoked responses (PSVER) were grossly abnormal on the right. The SER is shown in figure 3. This patient illustrates an early diagnosis of MS based on the results of the evoked potentials.

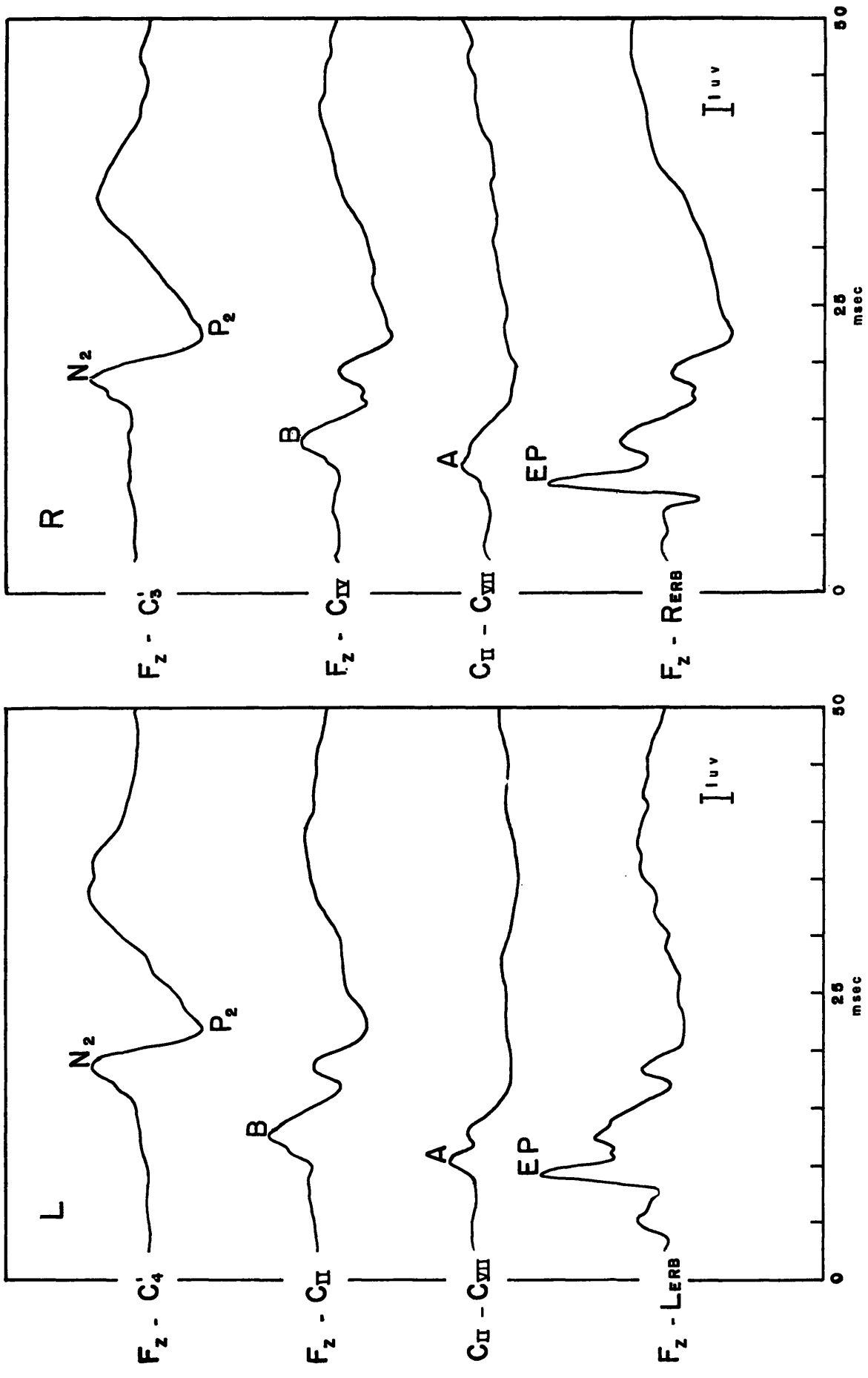


Fig. 1 — Normal 26 year old female.

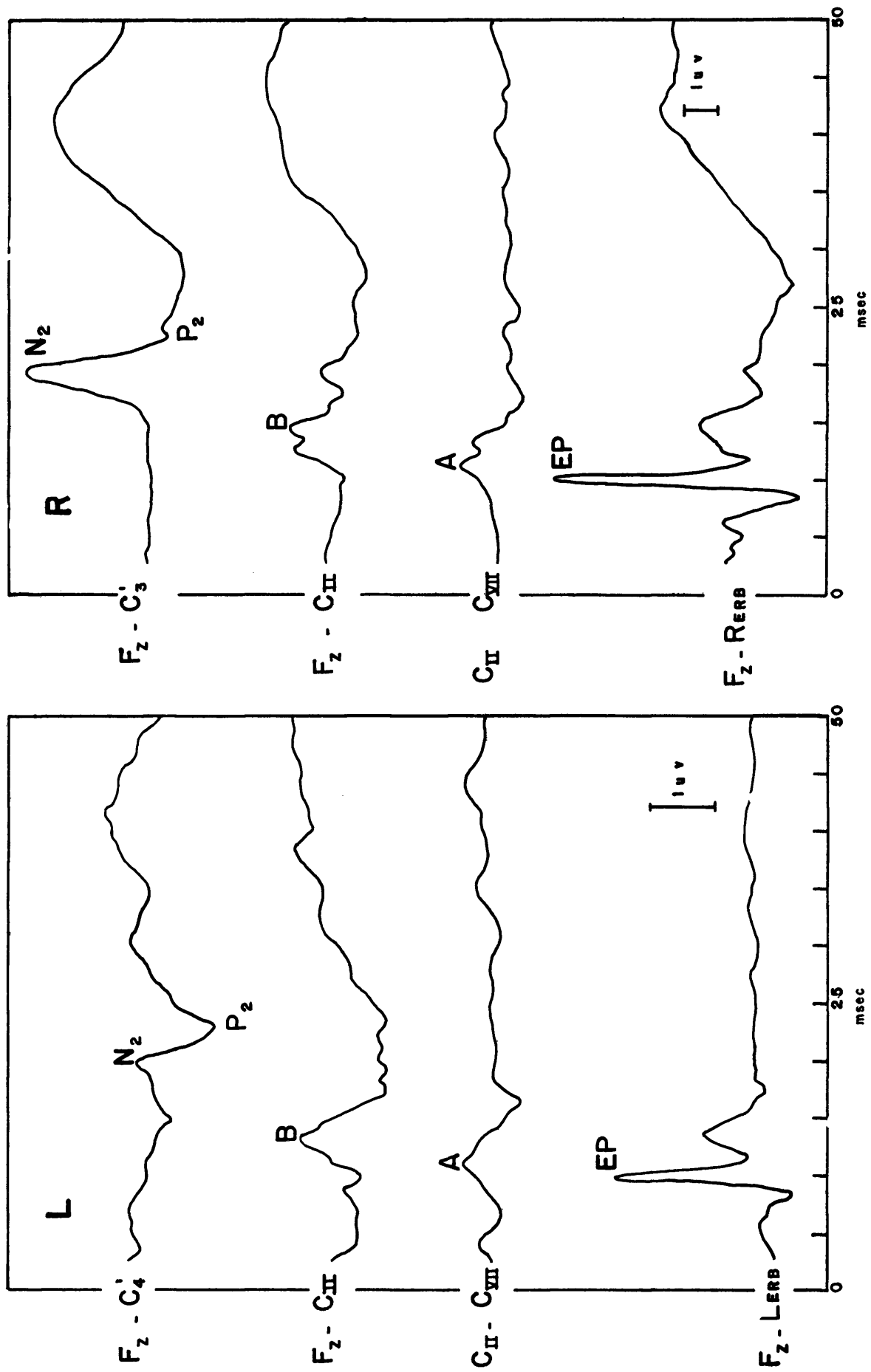


Fig. 2 — SER showing an asymmetric  $N_2$  in a patient with a well-documented right thalamic infarction. Note that  $N_2$  is  $0.25\mu V$  with left median stimulation (right thalamus) and is  $4.5\mu V$  with right median stimulation (left thalamus).

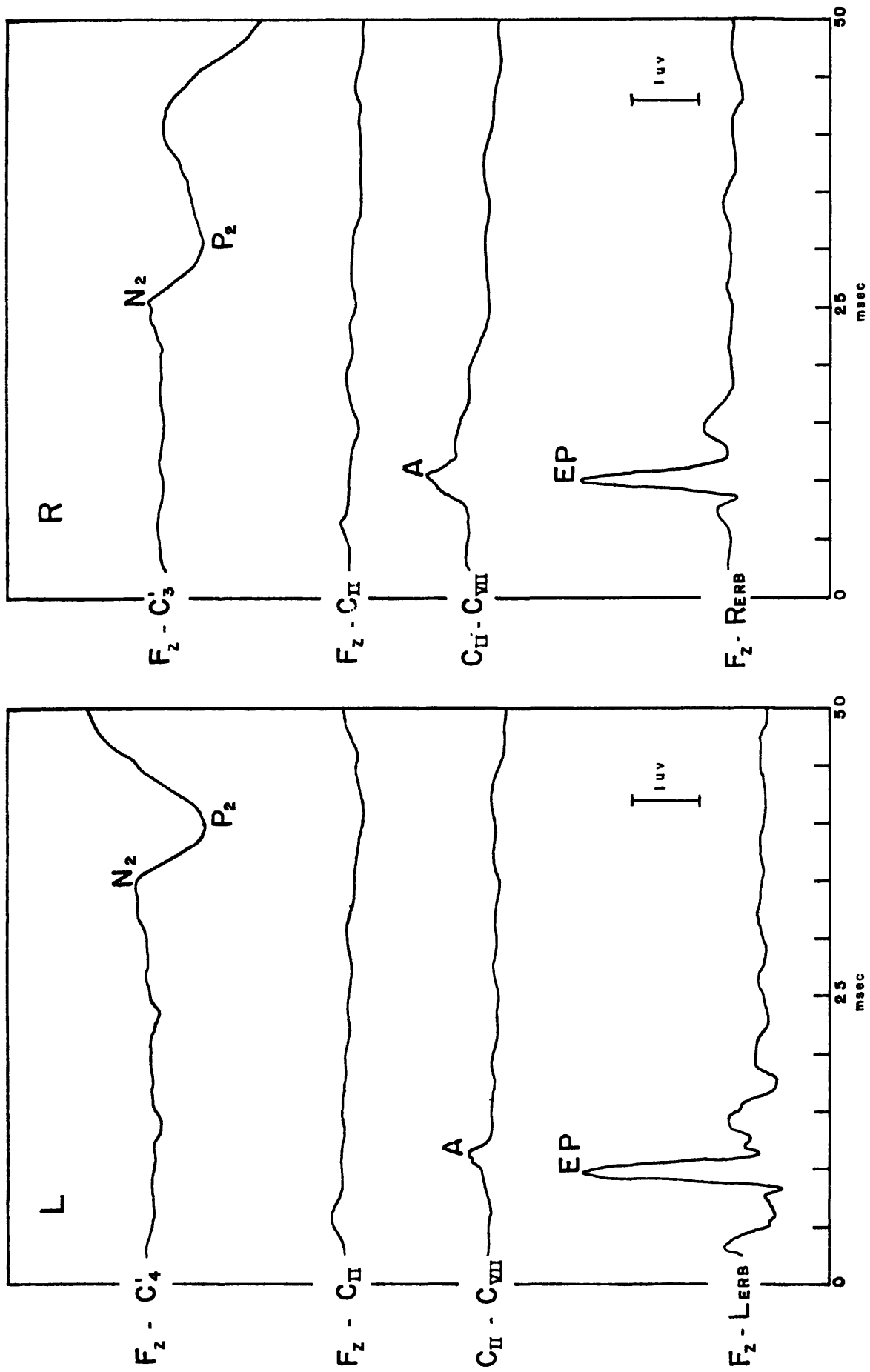


Fig. 3 — SER in a patient with retrobulbar neuritis confirming the diagnosis of MS. Note that there are no definite B waves and the cortical responses are severely delayed bilaterally but worse from the left median nerve stimulation.

## DISCUSSION

Although the genesis of the SER components is not yet completely clear they are considered of great clinical utility.

SER abnormalities have been described in multiple sclerosis (MS) <sup>2,6,11,22,25</sup> even in the absence of brainstem signs or clinically evident disturbances of specific sensory systems <sup>2</sup>. SER following median nerve stimulation was abnormal in 69% of MS patients with, and 51% of MS patients without sensory symptoms or signs <sup>6</sup>. The same author showed that unsuspected lesions were revealed in 41,37 and 24% of patients with MS by respectively the SER, BAER, and PSVER. The better sensitivity of the SER is presumably due to the greater length and amount of white matter tracts being tested. The SER therefore may be of value in the early diagnosis of this disease <sup>6,22</sup> and our Case 3. Abnormal SERs, have been found in patients with brachial plexus traction injuries <sup>17</sup>.

Abnormal interwave latencies between the EP response and the B wave have been reported in cervical spondylosis <sup>20</sup>.

The SER has been considered useful in the management of comatose patients <sup>4,12,24</sup>. In comatose patients with intact brainstem reflexes and normal BAER's the SER has a good prognostic value <sup>15</sup>. Chiappa (personal communication) claims that in general, comatose patients with normal N2 and P2 responses will have little or no disability; most of the patients with poorly defined N2 and P2 responses will suffer moderate to severe deficits; and 38% of patients without an N2-P2 died.

In brain death, the EP A and B waves are frequently preserved but N2 and P2 are absent <sup>12</sup>. Acute vascular infarcts involving subcortical white matter of thalamus may present an abnormal SER despite a normal CT-scan (case 2). Enhanced amplitudes of the cortical SER components appear to be characteristic in some forms of epilepsy, particularly myoclonic epilepsy, and it is not found in essential myoclonus <sup>13</sup>. The enhanced response may be limited to one side of the body or to the particular limb affected by the jerking.

Afferent activity travels centrally in large fibers coming from cutaneous and subcutaneous somaesthetic as well as joint muscle (Ia) and tendon (Ib) kinaesthetic or proprioceptive receptors. After entering the spinal cord, impulses will activate the following pathways: dorsal column-lemniscothalamic system, spinocervical-lemniscothalamic system, antero-lateral spinothalamic system and spino-cerebellar tracts <sup>7</sup>. These anatomic data may help explain the complexity of factors involved in the origin of the SER waves.

Electrical stimulation of the peroneal nerve at the knee as described by Cracco <sup>8,10</sup> has been a promising additional SER technique. The ascending volley in the spinal cord can be recorded from electrodes placed on the skin over the spine, neck and scalp. There are waves arising from the cauda equina (electrode L3), conus medullaris (electrode L1) and scalp. Waves are often difficult to record at the thoracic or cervical levels possibly because of the

desynchronization of the volley induced by differential conduction velocities in the spinal cord tracts activated. This relatively new test has been studied in MS patients and other neurologic disorders and seems to be sensitive in spinal cord white matter diseases. We have found this procedure of value in monitoring cord function during spinal corrective surgery.

#### SUMMARY

One technique used for short-latency somatosensory evoked response (SER) is described. SER following nerve stimulation is a unique non-invasive, clinical test used to evaluate the somatosensory pathways. It tests the physiological function of the median nerve, the brachial plexus, the C6-7 cervical roots, cervical spinal cord, the cuneate nuclei, the medial lemniscus, the thalamus, and the contralateral sensory cortex. It has been shown to be a reliable and useful clinical test particularly in multiple sclerosis and comatose patients. The promising technique of SER following peroneal nerve stimulation is mentioned.

#### RESUMO

##### *Potencial evocado somato-sensorial: aplicação em Neurologia.*

Potencial evocado somato-sensorial (PES) por estimulação elétrica do nervo mediano é a resposta elétrica produzida pela ativação do plexo braquial, raízes C6-7, medula cervical, sistema lemniscal do tronco cerebral, tálamo e córtex sensorial. Este teste clínico, não invasivo, permite a avaliação da integridade funcional da via somato-sensorial possibilitando a localização de lesões nos níveis acima apontados. O PES tem sido útil no estudo de comas, esclerose múltipla, doenças vasculares e outras patologias do sistema nervoso. PES por estimulação do nervo peroneiro parece ser muito sensível na detecção precoce do comprometimento da medula espinal.

#### REFERENCES

1. ALLISON T.; GOFF W. R.; WILLIAMSON P. D. & VANGILDER J. C. — On the neural origin of early components of the human somato-sensory evoked potential. *In: Clinical Uses of Cerebral, Brainstem and Spinal Somatosensory Evoked Potentials.* Prog. clin. Neurophysiol., vol. 7, Ed. J. E. Desmedt, 51-68 Karger, Basel, 1980.
2. ANZISKA B.; CRACCO R. Q.; COOK A. W. & FELD E. W.. — Somatosensory for field potentials: studies in normal subjects and patients with multiple sclerosis. *Electroenceph. clin. Neurophysiol.* 45:602, 1978.
3. ANZISKA B. & CRACCO R. W. — Short-latency somatosensory evoked potentials: studies in patients with focal neurological disease. *Electroenceph. clin. Neurophysiol.* 49:227, 1980.
4. CANT R. R. — Somatosensory and auditory evoked potentials in patients with disorders of consciousness: *In: Clinical Uses of Cerebral, Brainstem and Spinal Somatosensory Evoked Potentials.* Prog. clin. Neurophysiol., vol. 7, Ed. J. E. Desmedt, 282-291, Karger, Basel, 1980.



5. CELESIA G. G. — Somatosensory evoked potentials recorded directly from human thalamus and Sm I cortical area. *Arch. Neurol. (Chicago)* 36:399, 1979.
6. CHIAPPA K. H. — Pattern shift visual, brainstem auditory, and short-latency somatosensory evoked potentials in multiple sclerosis. *Neurology (Minneapolis)* 30:110, 1980.
7. CHIAPPA K. H.; CHOI S. K. & YOUNG R. R. — Short-latency somatosensory evoked potentials following median nerve stimulation in patients with neurological lesions. *In: Clinical Uses of Cerebral, Brainstem and Spinal Somatosensory Evoked Potentials. Prog. clin. Neurophysiol., vol. 7, Ed. J. E. Desmedt, 264-181 Karger, Basel, 1980.*
8. CRACCO R. Q. — Spinal evoked response: peripheral nerve stimulation in man. *Electroenceph. clin. Neurophysiol* 35:379, 1973.
9. CRACCO R. Q. — Scalp-recorded potentials evoked by median nerve stimulation: subcortical potentials, travelling waves and somatomotor potentials. *In: Clinical Uses of Cerebral, Brainstem and Spinal Somatosensory Evoked Potentials. Prog. clin. Neurophysiol., vol 7, Ed. J. E. Desmedt, 1-14 Karger, Basel, 1980.*
10. CRACCO R. Q.; CRACCO J. B. & ANZISKA B. J. — Somatosensory evoked potentials in man: cerebral, subcortical, spinal, and peripheral nerve potentials. *Am. J. EEG Technol.* 19:59-81, 1979.
11. EISEN A.; STEWART J.; NUDLEMAN K. & COSGROVE J. B. R. — Short-latency somatosensory responses in multiple sclerosis. *Neurology (Minneapolis)* 29:827, 1979.
12. GOLDIE W. D.; CHIAPPA K. H. & YOUNG R. R. — Brainstem auditory evoked responses and short-latency somatosensory evoked responses in the evaluation of deeply comatose patients. *Neurology (Minneapolis)* 29:581, 1979.
13. HALLIDAY A. M. & HALLIDAY E. — Cerebral somatosensory and visual evoked potentials in different clinical forms of myoclonus. *In: Clinical Uses of Cerebral, Brainstem and Spinal Somatosensory Evoked Potentials. Prog. clin. Neurophysiol. vol. 7, Ed. J. E. Desmedt, 292-310, Karger, Basel, 1980.*
14. HUME A. L. & CANT B. R. — Conduction time in central somatosensory pathways in man. *Electroenceph. clin. Neurophysiol.* 45:361, 1978.
15. HUME A. L.; CANT B. R. & SHAW N. A. — Central somatosensory conduction time in comatose patients. *Ann. Neurol.* 5:379, 1979.
16. JONES S. J. — Short-latency potentials recorded from the neck and scalp following median nerve stimulation in man. *Electroenceph. clin. Neurophysiol.* 43:853, 1977.
17. JONES S. J. — Investigation of brachial plexus traction lesions by peripheral and spinal somatosensory evoked potentials. *J. Neurol. Neurosurg. Psychiat. (London)* 42:107, 1979.
18. KRITCHEVSKY M. I. & WIEDERHOLT W. C. — Short-latency somatosensory evoked potentials. *Arch. Neurol. (Chicago)* 35:706, 1978.
19. NAKANISHI T.; SHIMADA Y.; SAKUTA M. & TOYOKURA Y. — The initial positive component of the scalp-recorded somatosensory evoked potential in normal subjects and in patients with neurological disorders. *Electroenceph. clin. Neurophysiol.* 45:26, 1978.
20. NEGAMY E. E. & SEDGWICK E. M. — Delayed cervical somatosensory potentials in cervical spondylosis. *J. Neurol. Neurosurg. Psychiat. (London)* 42:238, 1979.
21. PAPA KOSTOPOULOS D. & CROW H. J. — Direct recording of the somatosensory evoked potentials from the cerebral cortex of man and the difference between

- precentral and postcentral potentials. *In: Clinical Uses of Cerebral, Brainstem and Spinal Somatosensory Evoked Potentials.* Prog. clin. Neurophysiol. vol 7, Ed. J. E. Desmedt. 15-26, Karger, Basel, 1980.
22. SMALL D. G.; MATTHEWS W. B. & SMALL M. — Subcortical somatosensory evoked potentials in multiple sclerosis. *Electroenceph. clin. Neurophysiol.* 43:536, 1977.
  23. STOCKARD J. J. & SHARBROUGH F. W. — Unique contributions of short-latency auditory and somatosensory evoked potentials to neurologic diagnosis. *In: Clinical Uses of Cerebral, Brainstem and Spinal Somatosensory Evoked Potentials.* Prog. Clin. Neurophysiol. vol 7, Ed. J. E. Desmedt, 231-263, Karger, Basel, 1980.
  24. TORRE J. C.; TRIMBLE J. L.; BEARD R. T.; HANLON K. & SURGEON J. W. — Somatosensory evoked potentials for the prognosis of coma in humans. *Experimental Neurology* 60:304, 1978.
  25. TROJABORG W. & PETERSEN E. — Visual and somatosensory evoked cortical potentials in multiple sclerosis. *J. Neurol. Neurosurg. Psychiat.* (London) 42:323, 1979.
  26. WIEDERHOLT W. C. — Early components of the somatosensory evoked potential in man, cat and rat. *In: Clinical Uses of Cerebral, Brainstem and Spinal Somatosensory Evoked Potentials,* Prog. clin. Neurophysiol. vol 7, Ed. J. E. Desmedt 105-117, Karger, Basel, 1980.

*Departamento de Neurologia — Faculdade de Ciências Médicas — Universidade Estadual de Campinas — Caixa postal 1170 — 13100 Campinas, SP — Brasil.*