

PRIMARY HYPERPARATHYROIDISM SIMULATING MOTOR NEURON DISEASE

Case report

*Alzira Alves Siqueira Carvalho¹, Adriano Vieira², Hougelle Simplício²,
Satomi Fugygara², Solyon Maia Carvalho³, Moacyr Pezati Rigueiro⁴*

ABSTRACT - We report a case of a 26-year-old man who presented a lower motor neuron syndrome due to hyperparathyroidism. Electromyography showed neurogenic features with normal nerve conduction studies. Hypercalcemia led to the discovery of a primary hyperparathyroidism with gland hyperplasia. Following parathyroid surgery there was recovery of the neurological symptoms.

KEY WORDS: parathyroid gland, hyperparathyroidism, spinal muscular atrophy, gland hyperplasia.

Hiperparatiroidismo primário simulando doença do neurônio motor: relato de caso

RESUMO - Descrevemos o caso de homem de 26 anos que apresentou síndrome do neurônio motor inferior devido a hiperparatiroidismo. A eletromiografia mostrou aspecto neurogênico com estudos da condução normal. Hipercalcemia levou à descoberta de hiperparatiroidismo primário com hiperplasia da glândula. Após a cirurgia de ressecção da paratiróide, houve regressão dos sintomas neurológicos.

PALAVRAS-CHAVE: glândula paratiróidea, hiperparatiroidismo, atrofia muscular espinal, hiperplasia glandular.

The neurological clinical syndrome of hyperparathyroidism includes easy fatigability, weakness and especially amyotrophy, of proximal muscles with preserved reflexes in most cases. Neuromuscular symptoms resemble lower motor neuron disorders with or without upper motor neuron signs. Neurological complications are common but are minor in most cases; in some instances, however, they are so severe as to suggest a primary and even untreatable neurological disorder. Treatable neurological disorders mimicking motor neuron disease must be excluded and the calcium and phosphorus levels have to be measured since hyperparathyroidism can be cured as in the case we report.

CASE

A 26-year-old caucasian man presented with a one-year history of symmetric proximal weakness and leg pains, resulting in frequent falls and walking difficulties. He reported difficulty in swallowing, chewing, breathing and speaking. In addition and noted a chest deformity.

Examination revealed a short man with slight proxi-

mal muscle atrophy in the upper limbs and proximal and distal atrophy in the lower limbs (Fig 1). There were no fasciculations and both mental status and speech were normal, whilst cranial nerves were intact. Muscle power (according to MRC) was grade 4 in all proximal limbs. The sensory examination was normal. Muscle stretch reflexes were grade 2 in the upper and lower limbs with flexor-plantar responses bilaterally.

Laboratory studies including routine chemistries, creatinephosphokinase and thyroid function were normal. The first electrophysiological study (April 2002) showed a neurogenic pattern characterized by polyphasic motor unit potentials with decreased recruitment in several muscles of the upper and lower limbs. No fasciculations and fibrillations were seen. Nerve conduction studies were unremarkable. The molecular diagnosis for spinal muscular atrophy (SMA) - (SMN gene) was negative. Five months later, the patient was hospitalized with spontaneous femur fracture. Radiograms of upper and lower extremities showed a diffuse demineralization with areas of subperiosteal resorption. The serum calcium level was 13.5 mg/dl (8.8-10.5), the serum phosphate was 1,6 mg/dl (2,5-4,9), the magnesium was 1,3 mg/dl (1,8-2,4), the serum

Departamento de Neurologia Clínica, Hospital Santa Marcelina, São Paulo SP, Brasil (HSM): ¹Doutora em Medicina; Médica Assistente do Serviço de Neurologia Clínica, responsável pelo Serviço de Doenças Neuromusculares do HSM; ²Médico Residente do Serviço de Neurologia Clínica do HSM; ³Médico Assistente do Serviço de Neurologia Clínica do HSM; ⁴Doutor em Medicina; Médico Assistente do Serviço de Anatomia Patológica do HSM.

Received 21 June 2004, received in final form 14 August 2004. Accepted 5 October 2004.

Dra. Alzira A.S. Carvalho - Rua Jacques Felix 326/15 - 04509-001 São Paulo SP - Brasil. E-mail: alzirac@iconet.com.br

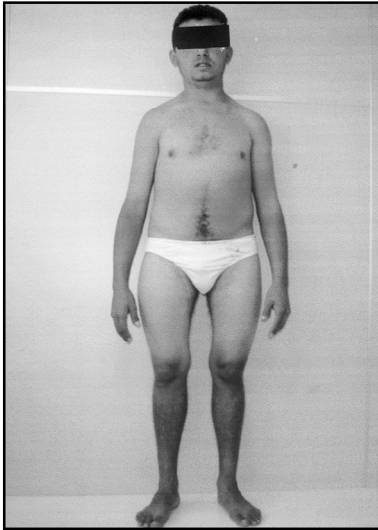


Fig 1. Proximal and distal muscle atrophy in the upper and lower limbs.

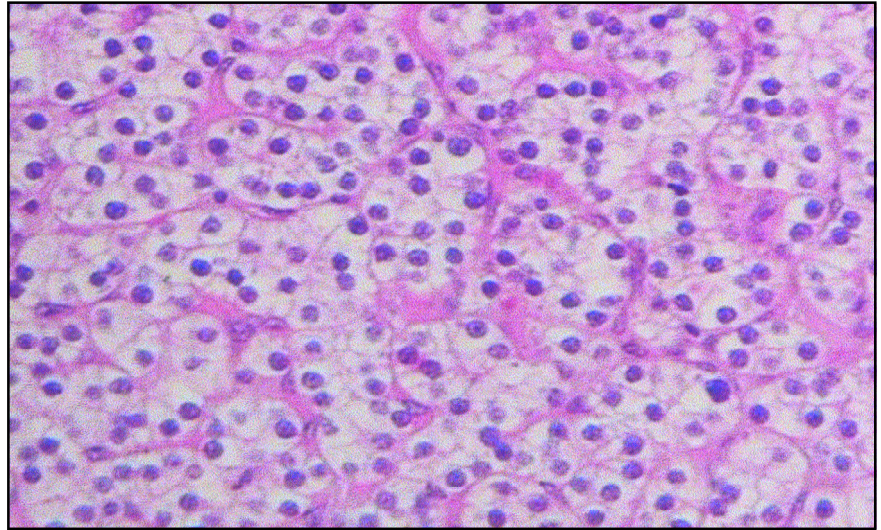


Fig 2. Gland hyperplasia.

parathyroid hormone (PTH) was 2018 pg/ml (15-65), the alkaline phosphatase was 1455 mg/dl (50-136) and the 24-hr urinary calcium excretion was 672 mg (42-352). Screening for autoimmune diseases resulted negative. Thyroid ultrasonography revealed increased tracer accumulation in parathyroid topography.

The patient underwent surgery of the parathyroid and the pathology showed diffuse parathyroid hyperplasia (Fig 2). Subsequently, a progressive recovery of neurological symptoms was observed despite the bone fracture. In June 2003, a new electrophysiological study showed a clear improvement in polyphasic motor unit potentials and decreased recruitment in only the left vastus medial and the tibialis anterior muscles. There was also improvement in calcium, phosphorus and PTH levels.

DISCUSSION

The anatomical localization of the neuromuscular involvement in hyperparathyroidism may be the same as amyotrophic lateral sclerosis (ALS) and SMA¹. There are few publications on primary hyperparathyroidism resembling SMA or ALS but only 3 with hyperplasia of the parathyroid. The remainder were regarding the adenoma. Most of these cases improved after resection of the parathyroid (Table 1).

In our report the hyperparathyroidism was associated with parathyroid hyperplasia. Patten et al.¹ had reported 2 cases of hyperplasia and neuromuscular symptoms but the electrophysiological findings were compatible with myopathy (cases 4 and 6). In 1984, Patten and Pages² reported a case resembling motor neuron disease and hyperplasia of the parathyroid. Patten et al.¹ described 16 cases

with neuromuscular symptoms associated with primary hyperparathyroidism and performed muscle biopsy which suggested neurogenic damage in all of them. However, the electrophysiological studies had a different pattern³ and only 6 patients showed lower and/or upper motor neuron signs (Table 1). In 1988, Verges et al.⁴ also described a patient with proximal weakness and quadriceps atrophy associated to parathyroid adenoma.

A clinicopathologic study of an 82-year-old man with progressive spinal muscular atrophy and parathyroid adenoma was reported by Dubas et al.⁵. Trebini et al.⁶ in 1993 published a case on a 57-year-old female, with hyperparathyroidism and motor neuron disease of the spinal muscular atrophy type. Pai et al.⁷ in 1997 reported a patient with possible MND who had recovered following parathyroid adenoma resection. However, the electrophysiological findings were not discussed. In 1998, Jackson et al.³ reported five patients meeting the El Escorial criteria for ALS and who also had hyperparathyroidism. In none of these cases, however, there was a clinical improvement documented. In 2001, Delmont et al.⁸ described a 72-year-old patient with distal weakness and atrophy of the upper extremities with EMG showing a lower motor neuron involvement associated with a primary hyperparathyroidism.

Our patient presented electrophysiological and clinical signs of lower motor neuron degeneration resembling a motor neuron disease (MND). Against this diagnosis the calcium level was high and the magnesium level was low, the molecular test for SMA was

Table 1. Previously reported patients with primary hyperparathyroidism and neuromuscular symptoms with improvement after surgery.

Author	Age	Number of cases	Sex	LMN	UMN	Parathyroid	Course
Patten et al. 1974	48	Case 1	F	PWALL	Hyperreflexia	Adenoma	
	52	Case 2	F	PW LL	NR	Adenoma	
	53	Case 3	F	PW LL+F+D	Hyperreflexia	Adenoma	I
	49	Case 4	M	Fatigab.	NR	Hyperplasia	
	77	Case 5	M	PW UL+LL	Absent	Adenoma	
	60	Case 6	F		NR	Hyperplasia	
Argov et al. 1979	64	Case 1	F	W + A	Hyperreflexia/BS	Adenoma	I
Patten and Pages 1984	40	Case 1	M	W+A	Hyperreflexia/BS	Adenoma	I*
	52	Case 2	F	PWA+F	Hyperreflexia	Hyperplasia	
Verges et al. 1988	74	Case 1	F	W+A	Absent	Adenoma	I
	24	Case 2	M		Absent	Adenoma	
Dubas et al. 1989*	82	Case 1	M	DA UL+ PW LL	Absent	Adenoma	Died**
Carnevale et al 1992	52	Case 1	F	PW LL	Hyperreflexia/BS	Not reported	I
Trebini et al. 1993*	57	Case 1	F	PW UL +LL	Absent	Adenoma	I
Pai et al. 1997	51	Case 1	M	PWA LL	NR	Adenoma	I
Delmont et al 2001*	72	Case 1	M	DAW UL	Absent	Adenoma	I

* case 2: died a month after second operation; ** died some days after operation; W, weakness; A: atrophy; PW, proximal weakness; UL, upper limbs; LL, lower limbs; F, fasciculations; PW, proximal weakness, DW, distal weakness; PA, proximal atrophy; DA, distal atrophy; D, dysphagia; BS, Babinski's sign; LMN, lower motor neuron; UMN, upper motor neuron, NR, not reported, I:improvement; *case resembling spinal muscular atrophy (EMG: denervation).

negative and there was regression of symptoms after the removal of the parathyroid. The absence of upper motor neurons signs makes an SLA diagnosis improbable.

Although the mechanism of neuronal damage remains unknown, the defect seems functional, as the neurological signs disappear after surgery or clinical treatment. The patterns of neurogenic atrophy seen in EMG suggest that the dysfunction affect the axon or the motor neuron itself. In most cases, there are three biochemical abnormalities: increased circulating PTH, hypophosphatemia and hypercalcemia. A direct effect of PTH on neural tissue has been reported as the possible cause of the disease⁹⁻¹¹. In fact the hyperparathyroidism can present as a severe neuromuscular disease similar to that seen in ALS or SMA patients, and it is therefore important to consider the hyperparathyroidism as one of the etiologies of the secondary motor neuron disorders.

Acknowledgments - We thank Prof. Mariz Vainzof for the study of DNA which searched for a deletion in the SMN gene .

REFERENCES

- Patten BM, Bilezikian JP, Mallette LE, Prince A, Engel K, Aurbach GD. Neuromuscular disease in primary hyperparathyroidism. *Ann Intern Med* 1974;80:182-193.
- Patten BM, Pages M. Severe neurological disease associated with hyperparathyroidism. *Ann Neurol* 1984;25:453-456.
- Jackson CE, Amato AA, Bryan WW, Wolfe GI, Sakhaee K, Barohn RJ. Primary hyperparathyroidism and ALS. *Neurology* 1998;50:1795-1799.
- Verges B, Wechsler B, Brunet P, Robin PM, Chigot JP, Godeau P. Formes neuromusculaires des hyperparathyroïdes. *Ann Med Interne* 1988; 139:254-257.
- Dubas F, Bertrand P, Émile J. Amyotrophie spinale progressive et adénome parathyroïdien. *Rev Neurol (Paris)* 1989;145:65-68.
- Trebini F, Appiotti A, Bacci R, Daniele D, Inglezic A. Complicanze neurologiche in corso di iperparatiroidismo. *Minerva Med* 1993;84:73-75.
- Pai MR, Raghuvver CV, Naik R, Shetty S, Shetty KB. Parathyroid adenoma masquerading as motor neuron disease. *Cytopathology* 1997;8:349-360.
- Delmont E, Roth S, Heudier P, et al. Hyperparathyroidie primitive, un diagnostic différentiel des maladies du motoneurone. *Rev Méd Interne* 2001;22:1253-1255.
- Baczynski R, Massry SG, Magott M, El-Bellessi S, Kohan R, Brantbar N. Effect of parathyroid hormone on energy metabolism of skeletal muscle. *Kidney Int* 1985;28: 73-85.
- Argov Z, Melamed E, Katz S. Hyperparathyroidism presenting with unusual neurological features. *Eur Neurol* 1979;18:338-340.
- Carnevale V, Minisola S, Romagnoli E, et al. Concurrent improvement of neuromuscular and skeletal involvement following surgery for primary hyperparathyroidism. *J Neurol* 1992;239:57.