

BRAIN SPECT IMAGING IN HUNTINGTON'S DISEASE BEFORE AND AFTER THERAPY WITH OLANZAPINE

CASE REPORT

*ELBA C. S. C. ETCHEBEHERE**, *MARIANA C. L. LIMA**,
*WALMIR PASSOS***, *JAIME A MACIEL JR****,
*ALLAN O. SANTOS**, *CELSO DARIÓ RAMOS**, *EDWALDO E. CAMARGO*****

ABSTRACT - Olanzapine, an atypical antipsychotic drug, was administered to a patient with Huntington's disease (HD) with marked choreiform movements. Brain SPECT with ^{99m}Tc -HMPAO was performed before and after treatment. Brain SPECT imaging has been performed in patients with HD in order to determine the status of basal ganglia perfusion. The use of brain SPECT with ^{99m}Tc -HMPAO before and after treatment in patients with HD has not been yet reported. The marked hypoperfusion of the basal ganglia on brain SPECT performed before therapy with olanzapine improved significantly after treatment.

KEY WORDS: Huntington's disease, brain SPECT, olanzapine, basal ganglia, ^{99m}Tc -HMPAO.

SPECT cerebral na doença de Huntington antes e após terapia com olanzapina: relato de caso

RESUMO - Olanzapina, um antipsicótico atípico, foi administrada a uma paciente com doença de Huntington (DH) com acentuados movimentos coreicos. O SPECT cerebral com HMPAO- ^{99m}Tc foi realizado antes da paciente iniciar qualquer tratamento e após tratamento com olanzapina. O SPECT cerebral tem sido realizado em pacientes com DH para avaliar a perfusão dos núcleos da base. O uso do SPECT cerebral com HMPAO- ^{99m}Tc antes e após terapia em pacientes com DH ainda não foi relatado. A acentuada hipoperfusão observada nos núcleos da base na imagem de SPECT cerebral, obtida antes da terapia com olanzapina, melhorou de forma significativa após o tratamento.

PALAVRAS CHAVE: doença de Huntington, SPECT cerebral, olanzapina, núcleos da base, HMPAO- ^{99m}Tc .

Huntington's disease (HD) is a hereditary degenerative disease characterized by movement disorders, personality and psychiatric changes and dementia. Histopathologically there is neuronal and neuroreceptor loss in the striatum. The use of brain SPECT imaging to evaluate basal ganglia (BG) perfusion in patients with HD is well established because it has been recognized that the functional changes precede the morphological changes. Abnormalities such as bilateral hypoperfusion of the BG have been described, as well as cortical hypoperfusion in severely ill patients. The use of brain SPECT imaging with ^{99m}Tc -HMPAO for treatment evaluation in patients with HD has not been

Division of Nuclear Medicine, Department of Radiology, Department of Psychology and Psychiatry and Department of Neurology, Faculdade de Ciências Médicas (FCM) da Universidade Estadual de Campinas (UNICAMP), Campinas, Brazil: *Assistant Professor, Division of Nuclear Medicine, Department of Radiology, FCM/UNICAMP; **Assistant Professor, Department of Psychology and Psychiatry, FCM/UNICAMP; ***Assistant Professor, Department of Neurology, FCM/UNICAMP; ****Professor of Radiology, Division of Nuclear Medicine, FCM/UNICAMP. Aceite: 24-junho-1999.

Elba C.S.C. Etchebehere, MD - Divisão de Medicina Nuclear, Departamento de Radiologia - Hospital das Clínicas UNICAMP - Caixa Postal 6142 - 13081-970 Campinas SP - Brasil. Fax 019 2511041. E-mail: elba@mn-d.com

reported. The purpose of this study is to evaluate the status of BG perfusion with ^{99m}Tc -HMPAO in a patient with HD before and after treatment with olanzapine.

CASE REPORT

A 34 year-old female patient with a strong family history of Huntington's disease began with choreiform movements at the age 29 and progressive loss of memory at the age 32. Prior to therapy the patient was submitted to brain SPECT imaging with ^{99m}Tc -HMPAO that revealed marked hypoperfusion of the left basal ganglia (BG). Semi-quantification of the BG, using the cerebellum as a reference, revealed: right BG = 0.91; left BG = 0.66 (normal = 0.97 ± 0.07 , using a control group of 50 normal volunteers; 25 females, 25 males, ages ranging from 19 to 44 years, mean 26.6 years).

Treatment with haloperidol resulted in very little improvement of her symptoms. A new brain SPECT imaging with ^{99m}Tc -HMPAO performed 2 years after the beginning of treatment with haloperidol revealed only slight improvement of the perfusion of the left BG. Semi-quantification of the BG, on this occasion, using the cerebellum as a reference, revealed: right BG = 0.90; left BG = 0.81 (normal = 0.97 ± 0.07).

The patient was then hospitalized, haloperidol was discontinued and treatment with 10 mg of olanzapine per day was begun. Five days later the choreiform movements had improved markedly. A brain SPECT with ^{99m}Tc -HMPAO performed 20 days after the beginning of treatment with olanzapine revealed marked improvement of the perfusion of the left BG (Fig 1). Semi-quantification of the BG, using the cerebellum as a reference revealed: right BG = 0.91; left BG = 0.92 (normal = 0.97 ± 0.07). The semi-quantification as well as the visual analysis demonstrated clearly an improvement of the perfusion of the BG, when compared to the study prior to treatment.

DISCUSSION

Huntington's disease is characterized by neuronal loss and neuroreceptor changes in the striatum, including a reduction of dopamine receptor density. There are many reports using brain SPECT imaging that describe BG hypoperfusion in patients with HD. These abnormalities are described, in general, as bilateral hypoperfusion of the BG, normally involving the head of the caudate, reflecting reduction of neuronal function¹⁻⁵, but hypoperfusion of the frontal⁶ and parietal lobes have been described in severely ill HD patients.

Olanzapine, an atypical antipsychotic drug, is a potent dopamine antagonist that reduces D_2 occupancy in the BG. Olanzapine also binds to many serotonin receptor subtypes with greater affinity for dopamine receptors, α_1 -adrenergic receptors, histaminergic H_1 receptors and muscarinic receptors. Olanzapine has less affinity than haloperidol for D_2 receptors. Brain SPECT studies with ^{123}I -IBZM have demonstrated a higher uptake of this tracer in patients treated with olanzapine than in those treated with haloperidol, therefore reflecting lower levels of D_2 occupancy⁷ by olanzapine when compared to haloperidol.

The beneficial action of these drugs is due to the blockage of the D_2 receptors of the striatum neurons that project to the external globus pallidus. The activity of these neurons, already impaired by HD, would be inhibited by the nigro-striatum dopaminergic afferent fibers. The therapeutic effect would be linked to D_2 receptor blockage which would increase the activity in the external globus pallidus-striatal pathway and improve the choreiform movements. Therefore, a greater therapeutic improvement with olanzapine would not be expected when compared to haloperidol, since olanzapine has less affinity for D_2 receptors. Thus, the therapeutic effect of olanzapine may not be related to the blockage of D_2 receptors. On the other hand, an improvement in perfusion of the BG, associated to an improvement in symptoms, suggests a possible beneficial effect of olanzapine on the metabolism of these neurons.

This patient has demonstrated that although neuronal loss and neuroreceptor changes occur in HD patients, there is probably a population of neurons that remain intact and capable of response to treatment. This was clearly demonstrated by the marked difference of ^{99m}Tc -HMPAO uptake by the BG before and after olanzapine therapy.

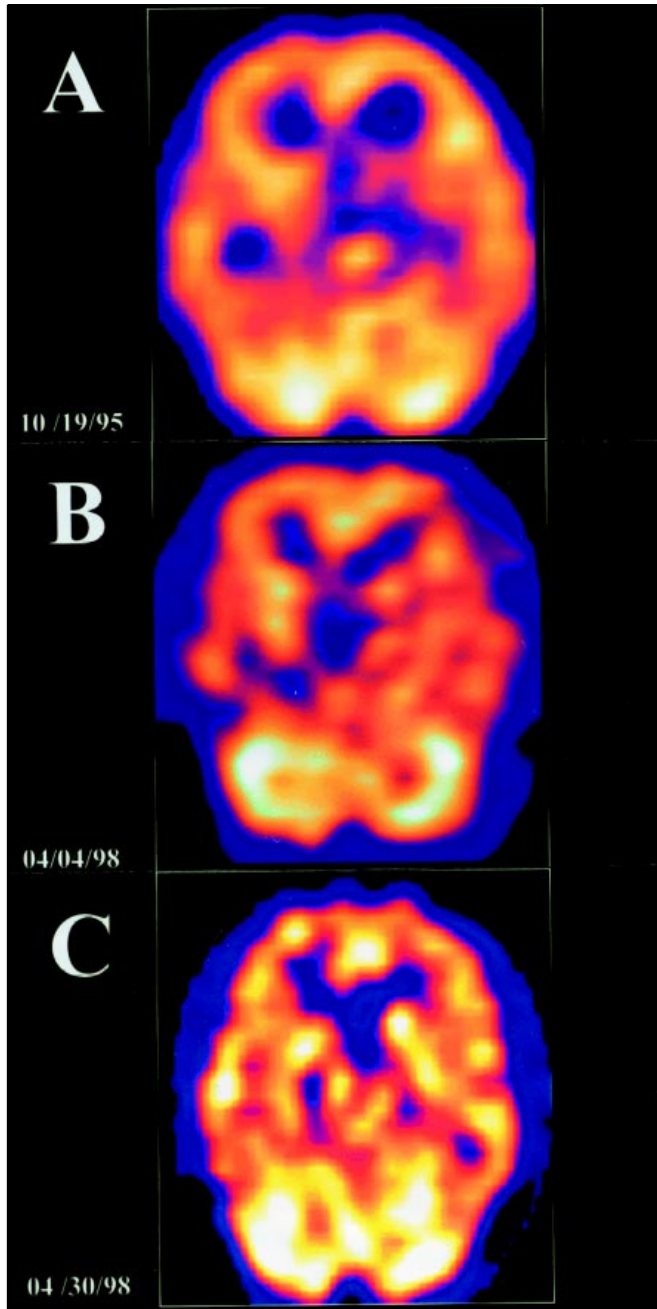


Fig 1. Brain SPECT imaging with ^{99m}Tc -HMPAO in a patient with Huntington's disease and severe choreiform movements. (A) Before treatment, there is marked hypoperfusion of the left basal ganglia. (B) After 2 years of treatment with haloperidol there is only slight improvement of the left basal ganglia perfusion. (C) After withdrawal of haloperidol and a 20-day trial with olanzapine there is marked improvement of left basal ganglia perfusion.

In conclusion, the improvement of BG perfusion with olanzapine in patients with HD is not simple to explain by the proposed mechanism of action of olanzapine. D₂ receptors are already reduced in number in these patients and non-functioning and olanzapine is preferentially a D₂ antagonist. These facts suggest that there may be another mechanism, perhaps not related to D₂ receptors, by which olanzapine acts on the BG and improves their perfusion. The use of ^{99m}Tc-HMPAO brain SPECT imaging before and after therapy in patients with HD may help to better understand the pathophysiology of this disease and the mechanism of action of these drugs.

REFERENCES

1. Harris GJ, Aylward EH, Peyser CE, et al. Single photon emission computed tomographic blood flow and magnetic resonance volume imaging of basal ganglia in Huntington's disease. *Arch Neurol* 1996;53:316-324.
2. Nagel JS, Ichise M, Holman BL. The scintigraphic evaluation of Huntington's disease and other movement disorders using single photon emission computed tomography perfusion brain scans. *Semin Nucl Med* 1991;21:11-23.
3. Ichise M, Toyama H, Fomazzari L, et al. Iodine-123-IBZM dopamine D2 receptor and technetium-99m-HMPAO brain perfusion SPECT in the evaluation of patients with and subjects at risk for Huntington's disease. *J Nucl Med* 1993;34:1274-1281.
4. Boecker H, Kuwert T, Langen KJ, et al. SPECT with HMPAO compared to PET with FDG in Huntington disease. *J Comput Assist Tomogr* 1994;18:542-548.
5. Botsch H, Oepen G, Deuschl G, et al. [SPECT studies with 99mTc-HMPAO in Huntington's chorea patients. *ROFO Fortschr Geb Rontgenstr Nuklearmed* 1987;147:666-668.
6. Gómez TE, Arias JA, Barrio AA, et al. Relation between frontal lobe blood flow and cognitive performance in Huntington's disease. *Neurologia* 1996;11:251-256.
7. Pilowsky LS, Busatto GF, Taylor M, et al. Dopamine D2 receptor occupancy in vivo by the novel atypical antipsychotic olanzapine—a 123I IBZM single photon emission tomography (SPET) study. *Psychopharmacology (Berl)* 1996;124:148-153.