

# LEOPARD SYNDROME, A NEURAL CREST DISORDER

## A CASE REPORT

*MARCO AURELIO LANA PEIXOTO \**  
*FRANCISCO O. L. PERPETUO \**  
*ROSCICLER P. DE SOUZA \*\**  
*DAIRTON MIRANDA \**  
*CIRO G. LOURES \**

Although disseminated lentigenes have long been noted to occur in association with a number of congenital abnormalities such as dermoglyphic changes<sup>4,36</sup>, mental retardation<sup>1,35</sup>, skeletal<sup>4,22,35,36</sup> and genital<sup>16,34,35</sup> abnormalities, ocular hypertelorism<sup>36</sup>, reduced stature<sup>16,34</sup>, EKG changes<sup>15,34</sup> and cardiopathies<sup>15,16,35</sup>, and deafness<sup>4</sup>, the mnemonic term Leopard syndrome was coined in 1969 by Gorlin et al.<sup>6</sup> to describe patients with multiple lentigenes (L), electro-cardiographic conduction defects (E), ocular hypertelorism (O), pulmonary stenosis (P), abnormalities of the genitalia (A), retardation of growth (R), and sensorineural deafness (D).

Only a minority of the reported cases show this complete spectrum of signs, suggesting a variable expressivity in the genetic transmission<sup>7</sup>. The syndrome has been considered a neural crest disorder<sup>17,23</sup> although abnormalities of some of the neural crest derivatives are yet to be described.

We report a case with a striking expressivity including additional findings such as multiple dental anomalies, macroglossia, basilar impression and platybasia, clitoral hypertrophy, anal ectopy and megacolon which to the best of our knowledge have not been found in previous cases. The presence of dental changes and megacolon in our patient, probably representing involvement of the dental papillae and myenteric plexus, may constitute a further evidence that the syndrome results from abnormalities of the neural crest elements.

## CASE REPORT

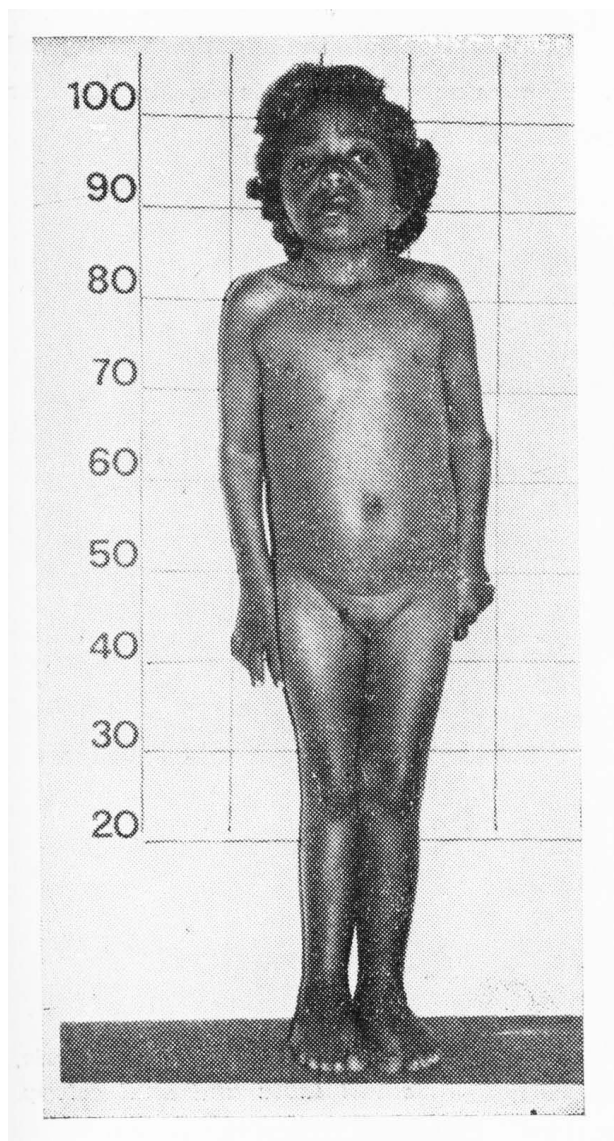
An 8-year-old girl was admitted to the hospital with a history of constipation of up to 21 days, exertional dyspnea and fatigue. She was born at 38 weeks gestation by elective cesarean section. Birthweight was 2635g. The mother was then 41 years, gravida 9, in good health and had an uncomplicated pregnancy. At birth the child was

---

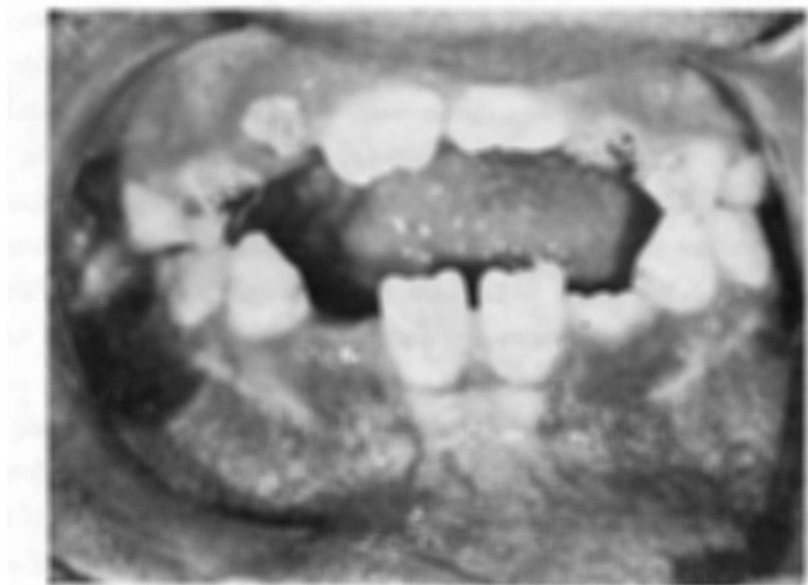
From the Department of Neurology, Federal University of Minas Gerais Medical School and Instituto Hilton Rocha, Belo Horizonte, Brasil: \* Assistant Professor; \*\* Resident in Neurology.

noted to have difficulty in sucking and swallowing. She only got head control by 2 years and walked at 4 years of age. At 5 she started to produce some verbal sounds but no real words could be formed. Dark-brown spots all over her body began to appear when she was 4 years old and progressively increased in number. Her mother had diffuse lentigenes but no other abnormality. The father was in good health and had no lentigenes. Two of the mother's siblings had multiple lentigenes mainly in the face and upper trunk, were mentally retarded and partially deaf. Four of the patient's sisters also had multiple lentigenes over the face, neck, trunk and limbs but no other abnormalities were observed on examination. Her three other siblings were not available for examination.

Physical examination revealed a mentally slow deaf-mute child with numerous brownish-black spots measuring 0.1 to 0.4cm in diameter and distributed all over the body surface axillary vaults, palms and soles. Mucosal surfaces were spared and there was no pigmentary defect in the retinae. "Café-au-lait" and "café-noir" spots were not found. The child had a triangular face, bilateral proptosis, epicanthal folds, hypertelorism, strabismus, prognathism and large and low-implanted ears (Figure 1). Marked dental displacement, irregularities and hypoplasia of the enamel (Figure 2), macroglossia and high arched palate were also noted. Skeletal anomalies included short stature winging of the scapulae, genu valgum, laterally rotated pes planus and hyper-

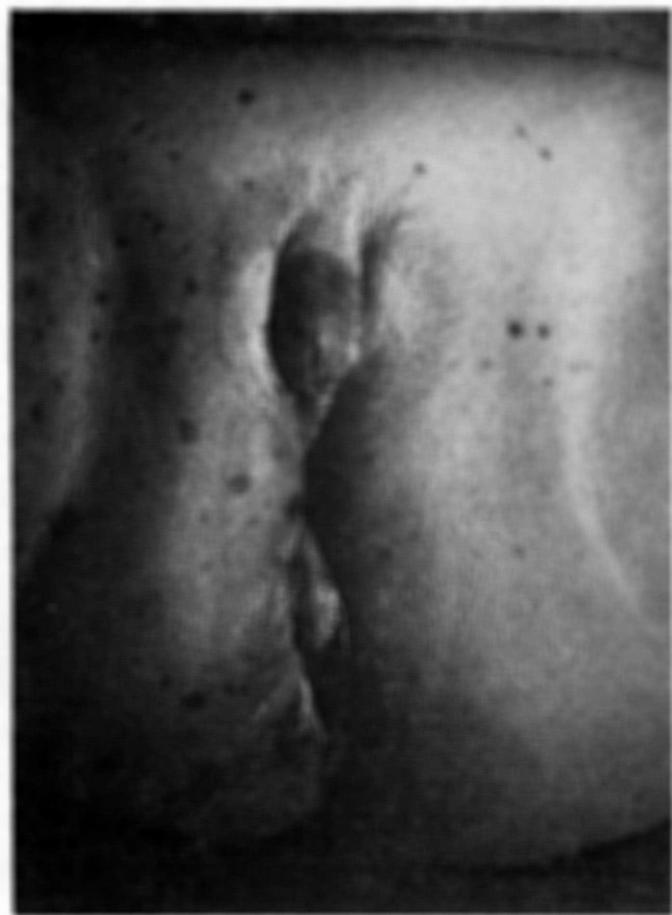

*Fig. 1 — Multiple lentigenes, left strabismus, proptosis, voluminous abdomen and genu valgum.*



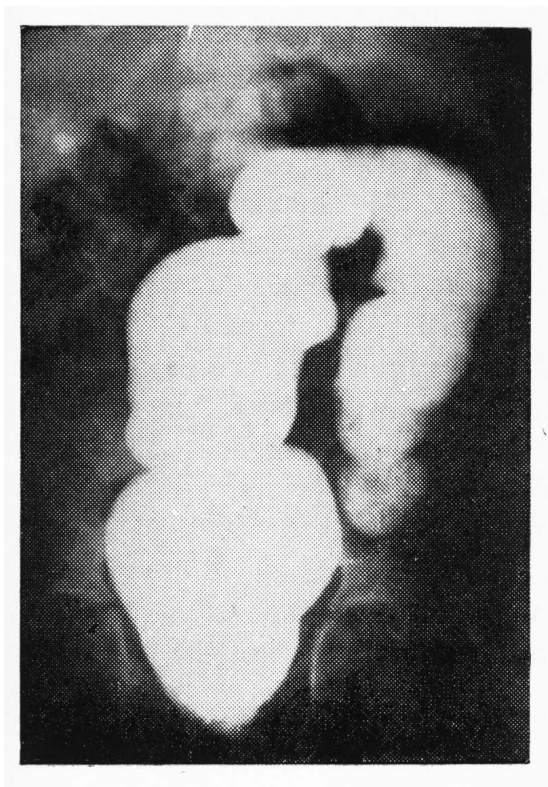
*Fig. 2 — Multiple dental anomalies.*

flexibility of joints. The abdomen was voluminous and hypersonant to percussion. Multiple fecalomas could be easily palpated. Examination of the genitalia disclosed small labia and marked clitoral hypertrophy. The anus was ectopic in an anterior midline position, very close to the vaginal opening (Figure 3).



*Fig. 3 — Hypertrophy of the clitoris, small labia and anal ectopy.*

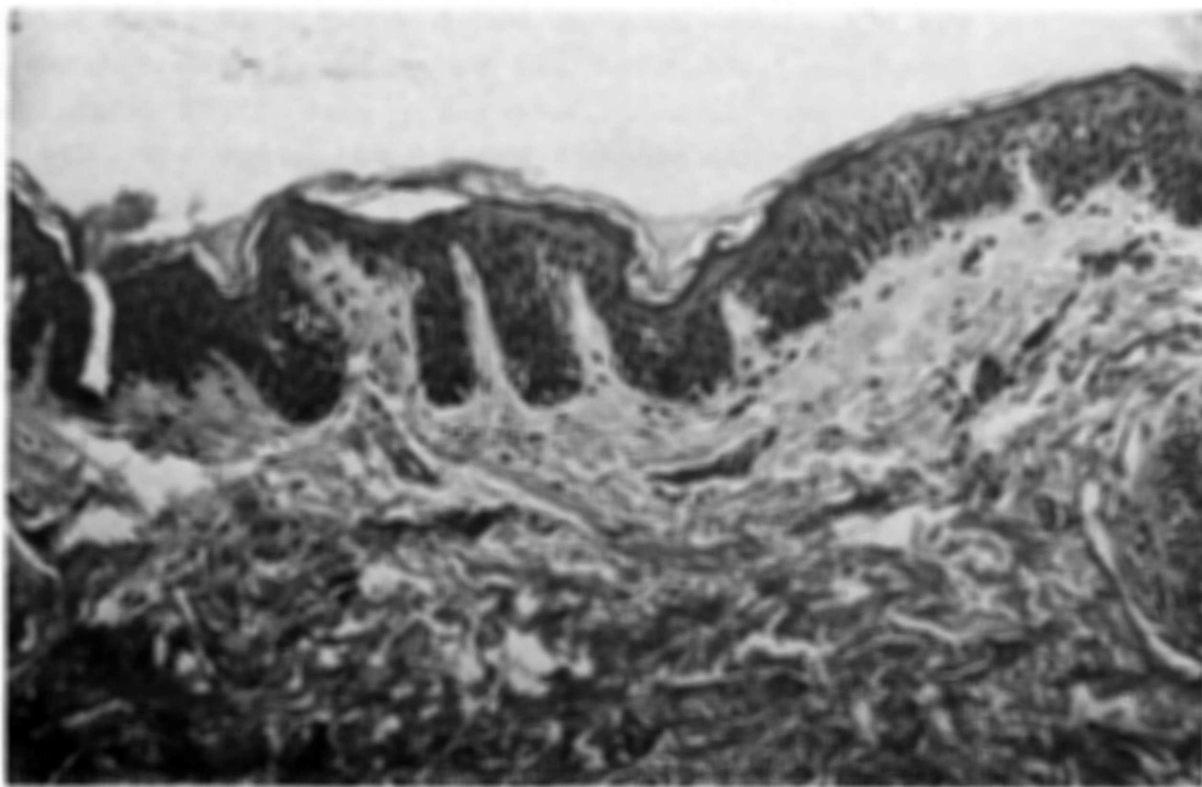
There were a left divergent strabismus and a bilateral sensorineural deafness. The head circumference was 48cm. Muscle tone and tendon stretch reflexes were decreased. Plantar responses were flexor. The palms and plants had a rubbery consistency. Sensation and coordination were normal. There was a grade IV/VI rough ejection systolic murmur best heard over the pulmonic area but no ejection click. Hemogram, blood sugar, BUN, transaminases, aldolase, LDH, CPK and serum electrophoretic pattern were all within normal limits. The electrocardiogram showed the QRS axis oriented at 115°, dominant S waves in  $V_5$  and  $V_6$  and a sinus tachycardia of 125 beats per minute. Catheterization of the right side of the heart demonstrated valvular pulmonic stenosis. An electroencephalogram showed occasional sharp waves in the temporal and occipital areas bilaterally. The skull, chest, spine, abdomen, upper and lower extremities were examined radiographically. Skull films showed mild irregularities of the inner table, moderate prognathism, platybasia and basilar impression. X-rays of the epiphyses were compatible with 6 years of age. A 2.5cm separation between the pubic symphysis was observed on pelvis X-ray. Barium enema revealed a striking megacolon (Figure 4). Biopsy of a dark-brown lesion from the left infrascapular area showed elongation of the rete ridges and moderate hyperplasia of melanocytes in the basal layer. There were also some melanophages in the dermis (Figure 5).



*Fig. 4 — Barium enema demonstrating megacolon.*

#### COMMENTS

The occurrence of congenital abnormalities in generalized lentigo was first reported by Zeisler and Becker<sup>36</sup> in 1936, who described a patient with multiple lentigenes, ocular hypertelorism, pectus carinatum and prognathism. Since then attention has been drawn to the association of multiple defects with the diffuse lentigenes syndrome. The term lentigenes derives the Latin word "lentigo" for



*Fig. 5 — Histologic section of pigmented lesion showing elongated rete ridges and hyperplasia of melanocytes in the basal layer.*

lentil-shaped spot<sup>11</sup> but there has been some dispute about the nomenclature of the syndrome. The term "Lentiginose profuse" was coined by Darier in 1902 and indicates the abundance of the dermatologic lesions. "Touraine's centrofacial lentiginosis"<sup>8</sup> and "multiple lentigenes syndrome"<sup>26</sup> also only emphasize the cutaneous aspect of the syndrome neglecting its other important features. In the 1960s the term "cardiocutaneous syndrome" was employed to describe patients with the association of generalized lentigenes and electrocardiographic changes<sup>8,34</sup>. Disagreement about the appropriate term to be used soon appeared because of the complexity of the syndrome<sup>6,26</sup>. The acronym "Leopard syndrome" has then been used as a mnemonic aid although only a minority of patients present all the salient features of the syndrome. The adjective "little" has been added to emphasize the short stature of the probands<sup>21</sup>.

The syndrome is an autosomal dominant inherited condition with a high penetrance and a markedly variable expressivity. However a few sporadic cases have been reported<sup>18,31</sup>. The fact that most cases have been transmitted through females suggests that gonadal hypoplasia in males may be of greater significance<sup>6,7</sup>.

Lentigenes are a characteristic component of the syndrome despite their absence in the majority of patients<sup>7</sup>. They are usually small — from pinpoint dots to 0.5 cm in diameter and numerous all over the body surface although the neck trunk and limbs are predominantly affected. They tend to spare the mucosae and retina. Interesting enough was the unilateral distribution of

lentigenes in the case reported by Cappon<sup>1</sup>. Microscopically they are characterized by an increased number of epidermal melanocytes and elongated club-shaped rete ridges that penetrate deeply within the dermis. The papillary epidermal pattern is deformed and there is accumulation of the pigment in the dermis as well as in the cells of the deeper layers of the epidermis<sup>12,23,24</sup>. Lentigenes are differentiated from freckles mainly in appearing at an earlier age — 2 to 5 years and 6 to 8 years respectively — having no increase in number with exposure to sunlight presenting deep and waivered rete ridges and a greater number of melanocytes per unit skin are<sup>6,7,24</sup>.

Many electrocardiographic changes have been described in Leopard syndrome<sup>4,15,17,21,27,31</sup>, most of them due to conduction defects and congenital cardiac malformations. A characteristic EKG anomaly is a superiorly oriented mean QRS axis in the frontal plane, usually between 60° and 120°<sup>7</sup>.

Ocular hypertelorism is the most common ocular abnormality<sup>3,6,7,9,29,36</sup>, but bilateral ptosis<sup>17,18</sup> epicanthal folds<sup>6,7</sup>, strabismus and early break of ocular convergence<sup>3,25,26</sup>, nevi of the iris<sup>3</sup>, nystagmus<sup>25</sup>, exophthalmos<sup>14</sup> and refraction disorders<sup>3,7</sup> have all been described. These signs contribute to a rather typical facies with a triangular shape, broad nasal bridge, prognathism and low-set ears. Biparietal bossing<sup>7,20</sup>, asymmetry and flattening of the occiput<sup>19</sup>, and microcephaly<sup>3</sup> have also been reported.

Valvular pulmonary stenosis as seen in our case is the most frequent cardiac abnormality resulting from thickening of the valvular cusps by mixomatous tissue<sup>7</sup>. Other cardiac abnormalities include obstructive hypertrophic cardiomyopathy<sup>7,15</sup>, aortic stenosis<sup>14</sup>, subaortic and subpulmonic stenosis<sup>15,19</sup> and congenital mitral insufficiency<sup>4</sup>.

Genital abnormalities in our case comprised small labia and clitoral hypertrophy. There was also ectopic positioning of the anus. Such findings have not been reported previously. On the other hand delayed puberty<sup>16</sup>, late menarch<sup>33</sup> and absence or hypoplasia of an ovary<sup>6,16</sup> are known to occur in association with Leopard syndrome. In males hypospadias cryptorchidism or descend of only one testis are very common findings<sup>8,7,9,16,17,34,35</sup>.

Growth retardation and skeletal anomalies are often observed, 85 per cent of the patients being below the twenty-fifth percentile for both height and weight<sup>7</sup>. Mandibular prognathism, retrognathism, pectus carinatum or excavatum, pterygium colli, flattening of the chest, winging of scapulae, dorsal kyphosis, severe scoliosis, bony fusion of cervical vertebrae, spina bifida occulta, L<sub>5</sub> sacralization, S<sub>1</sub> lumbalization, pubic hypotrophy, thoracolumbar gibbosity, subluxation or deformation of head of femur, hypermobility of joints, shortening of phalanges and halux valgum have been observed<sup>5,6,7,8,9,10,14,15,19,20,26,29,30,34,35</sup>. Skull X-rays may show demineralization of cranial vault, irregularities of the inner table, abnormalities of the sella, incomplete synostosis of sutures, hyperostosis, increased diploic vascularization and facial sinus asymmetry<sup>5,17,19</sup>. Microcephaly was found in one child<sup>3</sup>. Our patient is the first one to be described with platybasia and basilar impression.

Sensorineural deafness has been observed in about 15 per cent of cases<sup>7</sup> the lesion occurring either in the organ of Corti<sup>2</sup> or in the auditory bipolar cells<sup>23</sup>. Other anomalies found in probands include mental retardation, poor speech development<sup>19</sup>. Interdigital webs<sup>15,25,26</sup>, primary dentition delay<sup>21,31</sup>, receptive aphasia and slow nerve conduction<sup>19</sup>. The electroencephalogram may show slow activity for age<sup>18,19</sup> or a spike-and-wave pattern<sup>10</sup>.

Our patient has some abnormalities which have not been described in the already broadened concept of Leopard Syndrome such as macroglossia, multiple dental anomalies, basilar impression and platybasia, megacolon, hypertrophy of clitoris and anal ectopy. When one considers the possible pathogenesis of the syndrome some of these new features are expected to be found. It has been suggested<sup>18,23</sup> that Leopard Syndrome results from an anomaly of neural crest elements which give origin to pigmented cells of the epidermis, portions of the sympathetic nervous system including chromaffin cells of the adrenal medulla and of the gut, myenteric plexus and Schwann cells. The neural crest cells also contribute to the formation of the dental papillae and otic vesicles. Therefore, it is likely that most of the abnormalities found may be explained by a derangement of these elements. The presence of megacolon and dental anomalies in our case representing involvement of the myenteric plexus and dental papillae may constitute a further evidence in support of Leopard Syndrome as a neural crest disorder.

#### SUMMARY

A case of Leopard syndrome with full clinical expression is reported. In addition to the cardinal signs of the syndrome this patient presented some abnormalities which have not been previously described such as macroglossia, multiple dental anomalies, basilar impression and platybasia, megacolon, hypertrophy of clitoris and anal ectopy. The presence of dental anomalies and megacolon may represent involvement of the dental papillae and myenteric plexus favoring the view that the syndrome results from a derangement of the neural crest elements.

#### RESUMO

*Síndrome de Leopard, distúrbio da crista neural: relato de um caso.*

A síndrome de Leopard é uma condição autossoma dominante de variável expressão fenotípica. Uma minoria apenas dos pacientes apresenta todos os componentes da síndrome, ou seja, lentigenes múltiplas (L), alterações eletrocardiográficas (E), hipertelorismo ocular (O), estenose pulmonar (P), anormalidades genitais (A), retardo de crescimento (R), e surdez neurosensorial (D). Descrevemos o caso de uma criança com todos os componentes da síndrome além de outras anomalias não descritas anteriormente, tais como macroglossia, alterações dentárias, megacolon, ectopia anal e hipertrofia do clitoris, impressão

basilar e platibasia. A presença de alterações dentárias e megacolon, representando envolvimento das papilas dentárias e de plexo mioentérico, derivados da crista neural, constitui nova evidência que favorece a hipótese de ser a síndrome de Leopard resultante de anomalia dos elementos da crista neural.

## REFERENCES

1. CAPPON, D. — A case of unilateral lentigenes with mental deficiency. *Brit. J. Derm.* 60:371, 1948.
2. CAPUTE, A. J.; RIMOIN, D. L.; KONIGSMARK, B. W.; ESTERLY, N. B. & RICHARDSON, F. — Congenital deafness and multiple lentigenes. *Arch. Derm.* 100:207, 1969.
3. DOCIU, I.; GALACTIION-NITELEA, O.; SIRJITA, N. & MURGU, V. — La lentiginose centro-faciale de Touraine: a propos de 7 cas. *Prèsse Méd.* 79:1111, 1971.
4. FORNEY, W. R.; ROBINSON, S. J. & PASCOE, D. J. — Congenital heart disease, deafness and skeletal malformations: a new syndrome? *J. Pediatr.* 68:14, 1966.
5. FALACTION-NITELEA, O. & DOCIU, I. — Lentiginosis et anomalies de development. *Dermatologica* 148:108, 1974.
6. GORLIN, R. J.; ANDERSON, R. C. & BLAW, M. — Multiple lentigenes syndrome. *Amer. J. Dis. Child.* 117:652, 1965.
7. GORLIN, R. J.; ANDERSON, R. C. & MOLLER, J. H. — The Leopard (multiple lentigenes) syndrome revisited. *Laryngoscope* 81:1674, 1974.
8. KRAUNZ, R. F. & BLACKMAN, J. R. — Cardiocutaneous syndrome continued. *New Eng. J. Med.* 279:325, 1968.
9. KORO Xenides, G. T.; WEBB, N. D. Jr.; MOSCHOS, C. B. & LEHAN, P. H. — Congenital heart disease, deaf-mutism and associated somatic malformations occurring in several members of one family. *Amer. J. Med.* 40:615, 1970.
10. LASSONDE, M.; TRUDEAU, J. G. & GIRARD, C. — Generalized lentigenes associated with multiple congenital defect (Leopard syndrome). *Canad. Med. Ass. J.* 103:293, 1970.
11. LEIDER, M. & ROSENBLUM, M. — A dictionary of Dermatological Words, Terms and Phrases. McGraw-Hill, New York, 1968.
12. LEVER, W. F. — *Histopatology of the Skin.* Lippincot, Philadelphia, 1967.
13. LYNCH, P. J. — Leopard syndrome. *Arch. Derm.* 107:119, 1970.
14. MACEWEN, G. B. & ZAHARKOW, W. — Multiple lentigenes syndrome: a case report of a rare familial syndrome with orthopaedic considerations. *Clin. Orthop.* 97:34, 1973.
15. MATTHEWS, N. L. — Lentigo and electrocardiographic changes. *New Eng. J. Med.* 278:780, 1968.
16. MOYNAHAN, E. J. — Multiple symmetrical moles, with psychic and somatic infantilism and genital hypoplasia: first male case of a new syndrome. *Proc. Roy. Soc. Med.* 55:959, 1962.
17. MOYNAHAN, E. J. — Progressive cardiomyopathic lentiginosis: first report of autopsy findings in a recently recognized inheritable disorder (autosomal dominant). *Proc. Roy. Soc. Med.* 63:448, 1970.



18. MOYNAHAN, E. J. & POLANI, P. — Progressive profuse lentiginosis, progressive cardiomyopathy, small stature and other developmental anomalies: a new familial syndrome. XIII International Dermatology Congress, Springer-Verlag, Munich, 1967.
19. NORDLUND, J. J.; LERNER, A. B.; BRAVERMAN, I. M. & MCGUYRE, J. S. — The multiple lentigenes syndrome. Arch. Derm. 107:259, 1973.
20. PERNOT, C.; WORMS, A. M. & HENRY, M. — Les syndromes cardio-cutanées génétiques. Nouv. Presse Méd. 36:2395, 1973.
21. PICKERING, D.; LASKI, B.; MACMILLAN, D. C. & ROSE, V. — "Little leopard" syndrome: description of 3 cases and review of 24. Arch. Dis. Child. 46:85, 1971.
22. PIPKIN, A. C. & PIPKIN, S. B. — A pedigree of generalized lentigo. J. Hered. 41:79, 1950.
23. POLANI, P. E. & MOYNAHAN, E. J. — Progressive cardiomyopathic lentiginosis. Quart. J. Med. 41:205, 1972.
24. SELMANOWITZ, V. J. — Lentiginosis profusa syndrome (multiple lentigenes syndrome). Acta. Derm. (Stockolm) 51:387, 1971.
25. SELMANOWITZ, V. J. & ORENTREICH, N. — Lentiginosis profusa in daughter and mother: multiple granular cell "myoblastomas" in the former. Arch. Derm. 107:615, 1970.
26. SELMANOWITZ, V. J.; ORENTREICH, N. & FELSENSTEIN, J. M. — Lentiginosis profuse syndrome (Multiple lentigenes syndrome). Arch. Derm. 104:393, 1971.
27. SMITH, R. F.; PULICICCHIO, L. F. & HOLMES, A. V. — Generalized lentigo: electrocardiographic abnormalities, conduction disorders and arrhythmias in three cases. Amer. J. Cardiol. 25:501, 1970.
28. SOMERVILLE, J. & BONHAM-CARTER, R. E. — The heart in lentiginosis. Brit. Heart. J. 34:58, 1972.
29. SOMMER, A.; CONTRAS, S. B.; CRAENEN, J. M. & HOSIER, D. M. — A family study of the leopard syndrome. Amer. J. Dis. Child. 121:520, 1973.
30. TOURAINÉ, A. — La melanoblastose neurocutanée. Bull. Soc. Franc. Derm. Syph. 51:421, 1941.
31. VICKERS, M. R. & MACMILLAN, D. C. — Profuse lentiginosis, minor cardiac abnormalities and small stature. Proc. Roy. Soc. Med. 62:1011, 1969.
32. WAANSON, S. L.; SANTEN, R. J. & SMITH, D. W. — Multiple lentigenes syndrome: new findings of hypogonadotrophism, hyposmia and unilateral renal agenesis. J. Pediatr. 78:1037, 1971.
33. WALTHER, R. J. — Cardiocutaneous syndrome. New Eng. J. Med. 278:1127, 1968.
34. WALTHER, R. J.; POLANSKI, R. J. & GROTS, I. A. — Electrocardiographic abnormalities in a family with generalized lentigo. New Eng. J. Med. 275:1220, 1968.
35. WATSON, G. H. — Pulmonary stenosis, café-au-lait spots, and dull intelligence. Arch. Dis. Child. 42:303, 1967.
36. ZEISLER, E. P., & BECKER, S. W. — Generalized lentigo: its relation to systemic nonelevated nevi. Arch. Derm. Syph. 33:109, 1936.