

UNUSUAL MANIFESTATIONS OF NEUROCYSTICERCOSIS IN MR IMAGING

Analysis of 172 cases

Lázaro Amaral², Murilo Maschietto¹, Roberta Maschietto¹, Ricardo Cury¹, Nelson Fortes Ferreira², Renato Mendonça², Sérgio Santos Lima³

ABSTRACT - Purpose: The typical manifestations of neurocysticercosis are described widely in the literature. The purpose of this study is to demonstrate the uncommon presentations of different forms of neurocysticercosis in MR imaging. **Method:** A retrospective analysis of 172 cases of neurocysticercosis in MR studies was carried out over a period of 13 years. One hundred and four males and 68 females with a mean age of 32 ± 3.7 years were studied. The studies were performed on 1.5 T GE MR units and T1 was used before and after gadolinium injection, T2 and gradient-echo (T2*) sequences. **Results:** The authors divided the unusual manifestations of neurocysticercosis into: intraventricular, subarachnoid, spinal, orbital, intraparenchymatous, and reactivation of previously calcified lesions. The results obtained were: intraparenchymatous 95 cases (55.23%); intraventricular 27 cases (15.69%); subarachnoid 20 cases (11.63%); spinal 6 cases (3.49%); orbital 1 case (0.58%); reactivated lesion 1 case (0.58%); association of intraventricular and intraparenchymatous 12 cases (6.98%); association of subarachnoid and intraparenchymatous 6 cases (3.49%); association of subarachnoid and intraventricular, 4 cases (2.32%). **Conclusion:** MR imaging is a sensitive and specific method in the analysis of different forms of unusual manifestations of neurocysticercosis, which should appear in the differential diagnosis of parenchymal, ventricular, spinal, cisternal, and orbital lesions.

KEY WORDS: cysticercosis, parasites, MRI, subarachnoid space.

Manifestações incomuns na ressonância magnética da neurocisticercose: análise de 172 casos

RESUMO - Objetivo: as manifestações típicas da neurocisticercose já são bem conhecidas. O papel deste estudo foi demonstrar os aspectos incomuns da neurocisticercose na ressonância magnética. **Método:** foram analisados 172 casos de ressonância magnética de neurocisticercose na Med Imagem num período de 13 (treze) anos em aparelhos GE de 1.5T Signa (Horizon, LX e CVI). Dos casos analisados, foram diversas as formas de apresentação, incluindo intraventricular, intraespinhal, cisternal, orbital, formas atípicas parenquimatosas (simulando tumores), forma miliar e evolução não usual (reativação). **Conclusão:** A ressonância magnética é método sensível e específico na avaliação das numerosas formas de apresentação atípica da neurocisticercose, as quais devem constar no diagnóstico diferencial de lesões intraventriculares, cisternais, orbitárias e parenquimatosas.

PALAVRAS-CHAVE: cisticercose, parasitas, ressonância magnética, espaço subaracnóide.

The typical manifestations of neurocysticercosis are widely described in the literature. The purpose of this study is to demonstrate the uncommon aspects of the different forms of neurocysticercosis in magnetic resonance imaging (MRI).

METHOD

A retrospective analysis of MRI exams of 172 neurocysticercosis patients, performed between 1989 and 2002,

was carried out. There were 104 males and 68 females with a mean age of 32.3 years. The studies were performed on 1.5T GE MRI units with sequences SE T1WI pre- and postcontrast (Gd-DTPA), FSE T2WI, FLAIR and Gradient echo (T2*WI).

RESULTS

Neurocysticercosis presentations were divided into: intraventricular, subarachnoid, spinal, orbital and in-

MEDIMAGEM - Hospital Beneficência Portuguesa, São Paulo SP, Brasil: ¹Médico estagiário do setor de ressonância magnética; ²Médico neurorradiologista; ³Chefe do Departamento de Imagens

Received 29 November 2002, received in final form 20 February 2003. Accepted 8 March 2003.

Dr. Lázaro Amaral - Rua Luiz Gottschalk 151/111 - 04008-070 São Paulo SP - Brasil. E-mail: lazden@terra.com.br

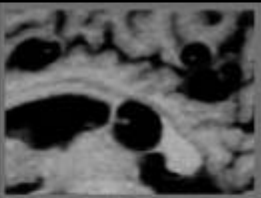
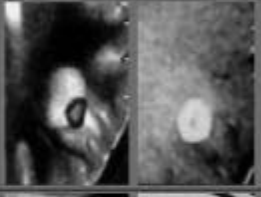
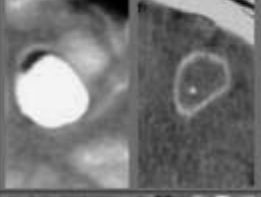
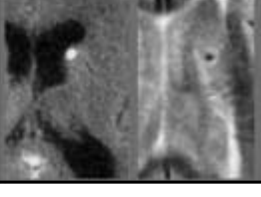
First stage	Vesicular	Cyst + Scolex Non enhancement	
Second stage	Coloidal	Ring enhancement Edema	
Third stage	Granular nodular degeneration	Decreased enhancement and edema Begins calcification	
Fourth stage	Involution	Obvious calcification on CT and MRI (T2*WI)	

Table 1. Stages of cysticerci on MRI.

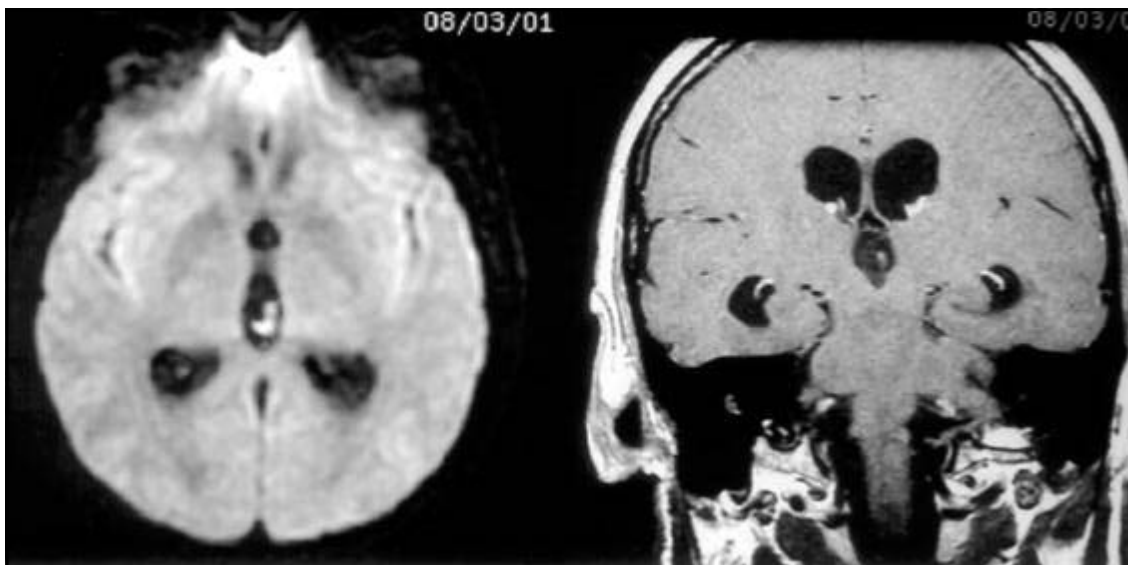


Fig 1. MRI - Axial Diffusion and Coronal T1WI 3mm thick slices postcontrast (Gd-DTPA): Cysticercus in the third ventricle. This lesion was not visible on the other sequences.

traparenchymatous. The results obtained were: intraparenchymatous (95 cases or 55.23%), intraventricular (27 cases or 15.69%), subarachnoid (20 cases or 11.63), spinal (6 cases or 3.49%), orbital (1 case or 0.58%), reactivated lesion (1 case or 0.58%), association of intraventricular and intraparenchymatous (12 cases or 6.98%), association of subarachnoid

and intraparenchymatous (6 cases or 3.49%), association of subarachnoid and intraventricular (4 cases or 2.33%).

DISCUSSION

Cysticercosis affects 50 million people around the world, with a prevalence of 3 to 6% of the population

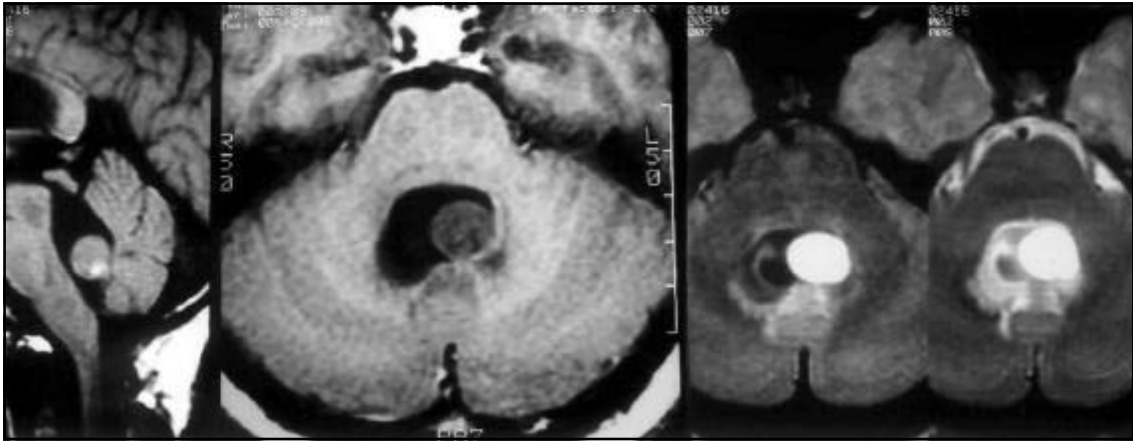


Fig 2. MRI Sagital T1WI, Axial T1WI and Axial T2WI: Cysticercus in the IV ventricle with high protein content.

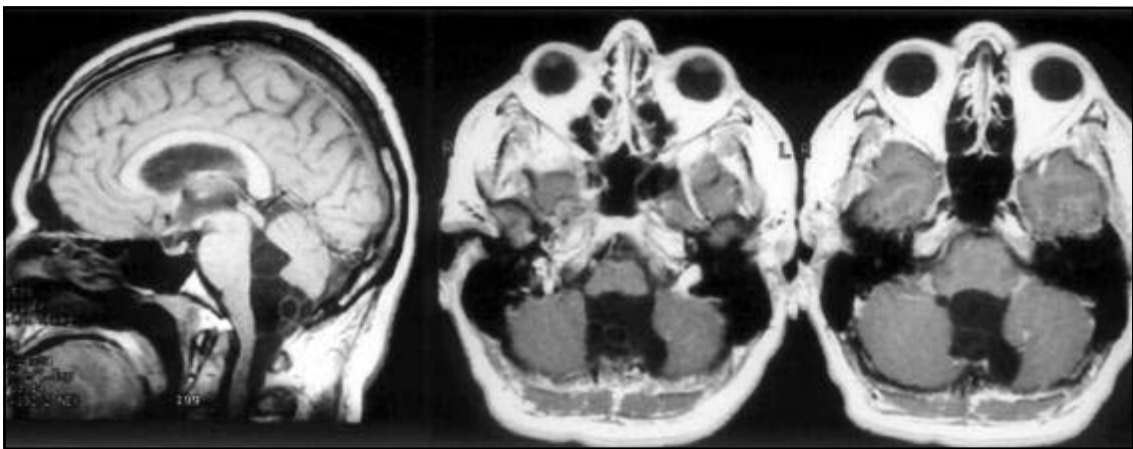


Fig 3. MRI Sagital T1WI and Axial T1WI postcontrast (Gd-DTPA): Racemous form in the cisterna magna with invagination into the IV ventricle.

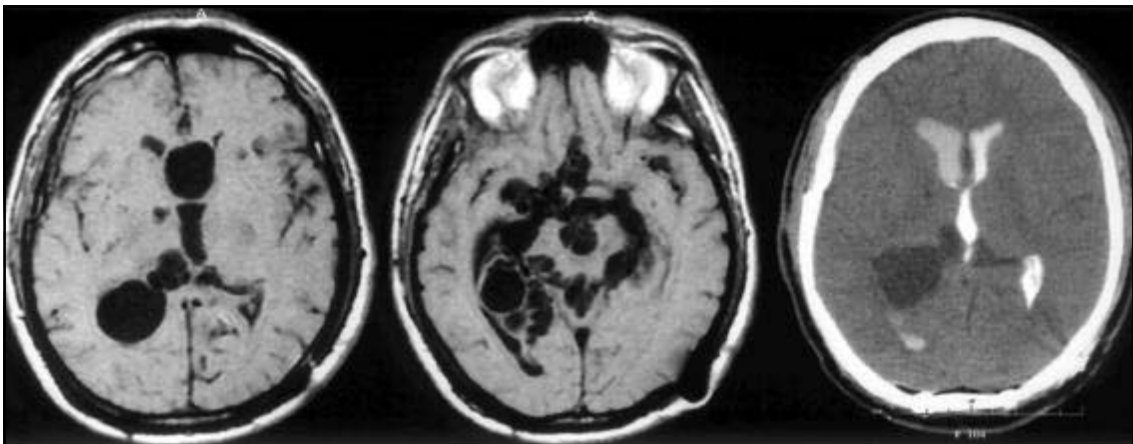


Fig 4. MRI Axial T1WI and CT Cisternography: Racemous form in the basal cisterns with cyst within the ventricular atrium.

in endemic areas such as Central and South America, East Europe, Africa and some regions in Asia^{1,2}. Cysticercosis is the most common parasitic infection of the central nervous system (CNS) and it is caused by *Taenia solium*'s invasion in its larval stage. CNS in-

volvement occurs in 60 to 90% of patients with cysticercosis³⁻⁵. The severity of neurocysticercosis depends on the location of the parasite in important tissues, as for example the orbit and the CNS, being the latter a frequent cause of seizures in Brazil⁶.

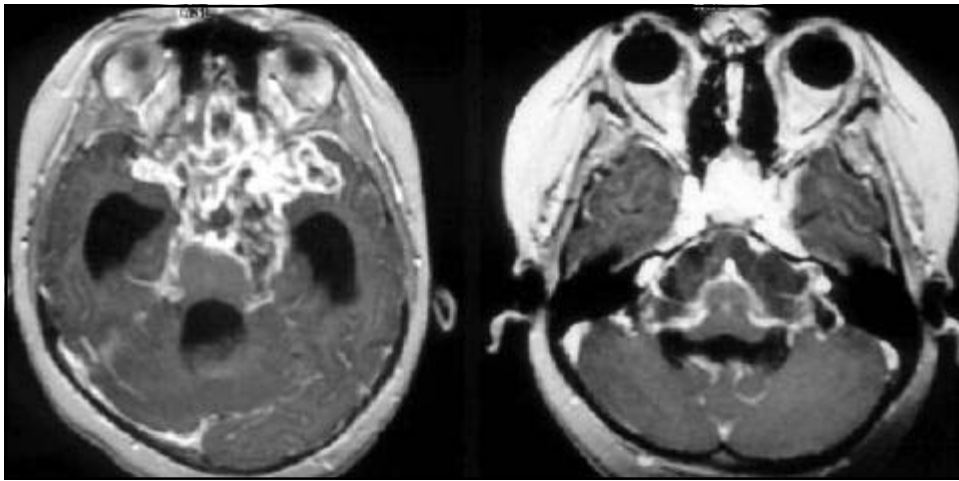


Fig 5. MRI Axial T1WI postcontrast (Gd-DTPA): Multiple cysts in the basal cisterns with arachnoiditis.

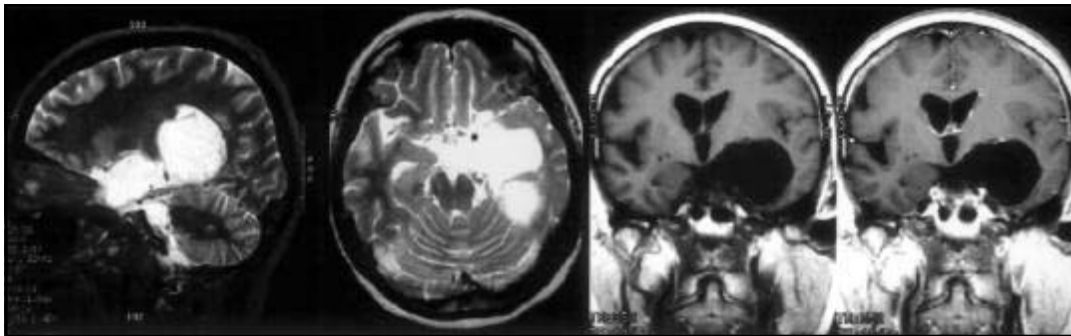


Fig 6. MRI Sagittal T2WI, Axial T2WI, Coronal T1WI pre- and postcontrast (Gd-DTPA): bulky cyst in the supra sellar cistern and in the left coroid fissure.

When invasion of the CNS occurs, the cysticerci develop in four stages identified by MRI (Table 1). With didactic purpose, the unusual forms of neurocysticercosis were divided into: intraventricular, subarachnoid, spinal, orbital, intraparenchymatous and reactivation of previously calcified lesion.

Intraventricular neurocysticercosis

The ventricular system is the second most common site of neurocysticercosis². It is frequently caused by *Cysticercus cellulosae*, however *Cysticercus racemosus* can also infect the ventricular system. The intraventricular form of the disease is found in more than 54% of patients with intracranial cysticercosis studied by MRI^{1,2}.

It most commonly affects the IV ventricle (54%-64%), followed by the III ventricle (23%-27%), the lateral ventricles (11% - 14%) and Sylvius aqueduct (9%)^{7,8}. In our study we had 43 intraventricular, being 69% located in the IV ventricle, 12% in the III ventricle, 12% in the lateral ventricles and 7% in the Sylvius aqueduct. Computed tomography (CT) does not fre-

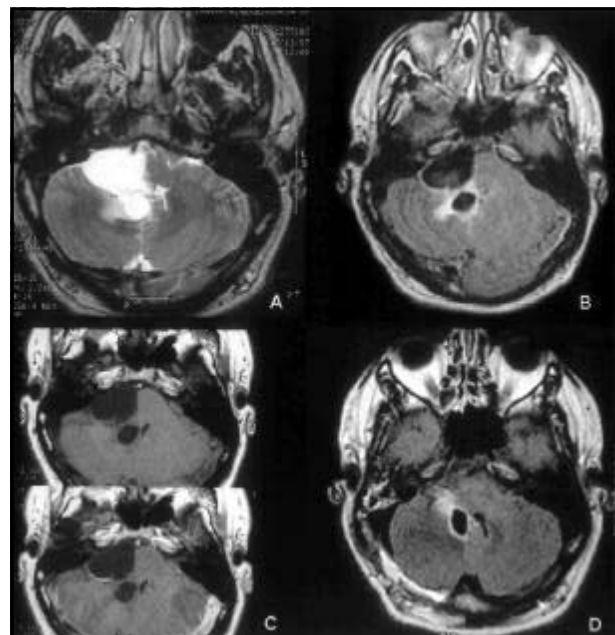


Fig 7. MRI Axial T2WI(A), Axial flair(B), Axial T1WI pre- and postcontrast (Gd-DTPA). Bulky cystic lesion in the right CPA cistern and small cyst in the right IV ventricle recess/ Axial Flair(D) after surgery: Removal of the cyst in the right CPA cistern and residual cyst within the IV Ventricle.

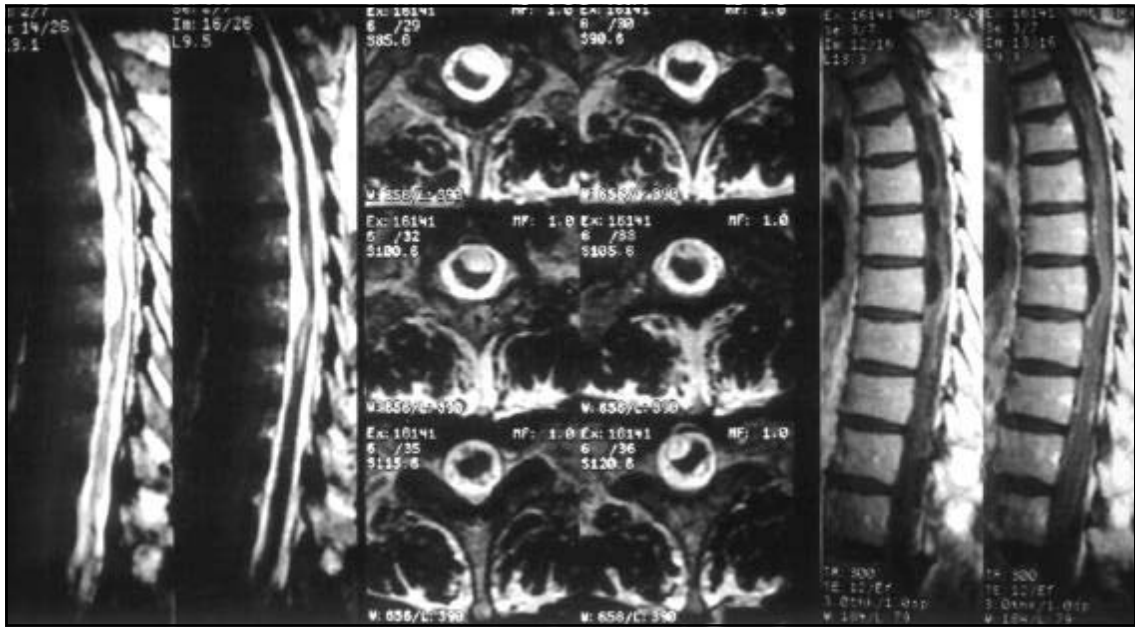


Fig 8. MRI Sagittal T2WI, Axial T1WI and Sagittal T1WI postcontrast (Gd-DTPA): Multiple cystic lesions in intradural-extramedullary situation leading to spinal cord compression.

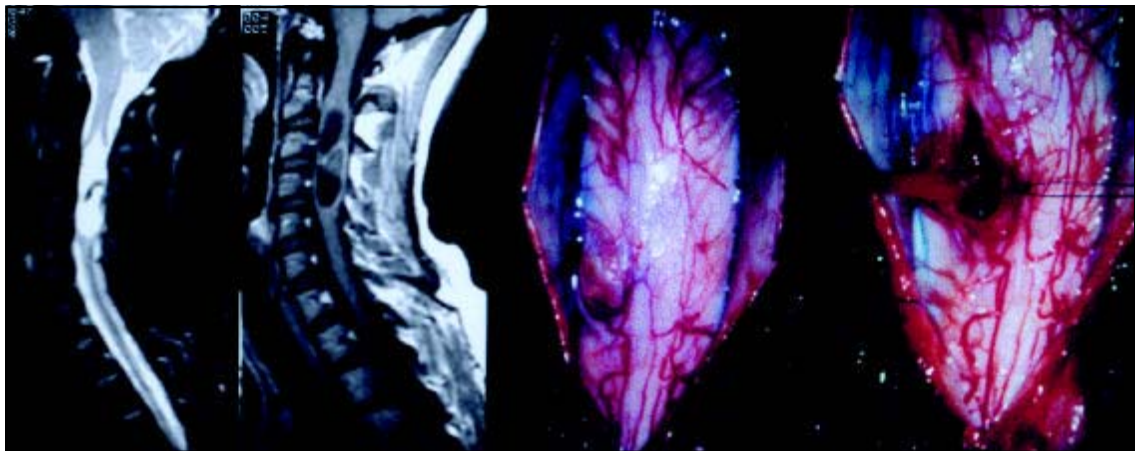


Fig 9. MRI Sagittal T2WI and Sagittal T1WI: Intramedullary cystic lesions and pictures of the surgical removal of them.

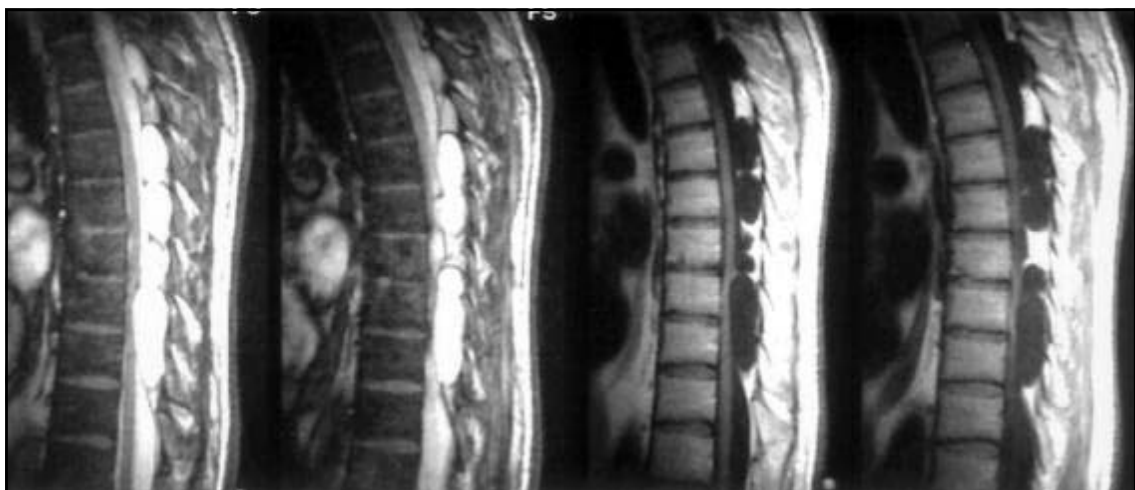

Fig 10. MRI Sagittal T2WI and Sagittal T1WI: Multiple cystic lesions in extra dural situation.

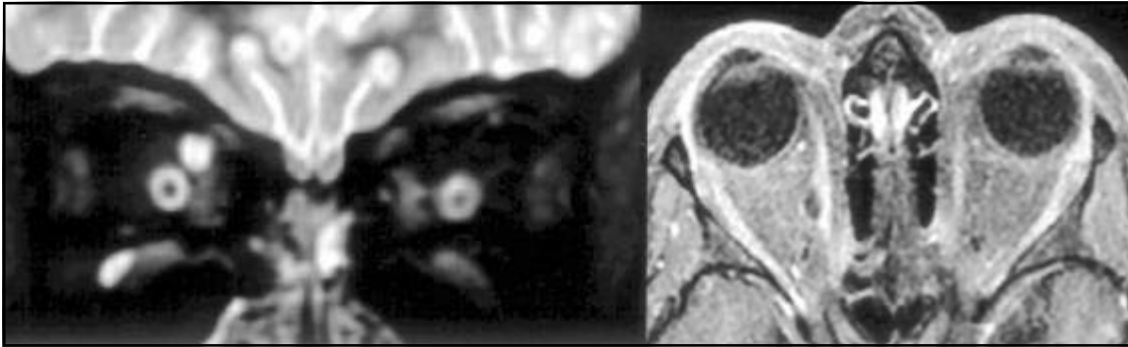


Fig 11. MRI Coronal T2WI and Axial T1WI with Fat saturation postcontrast (Gd-DTPA). Small cystic lesion in the right medial rectus muscle.

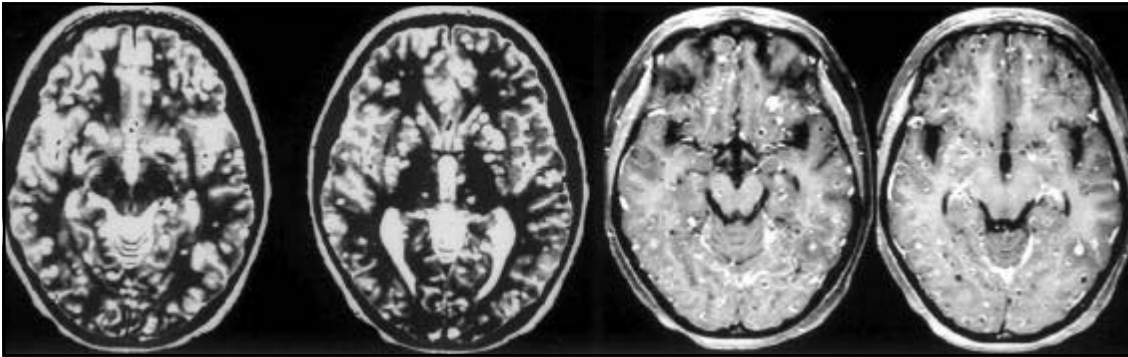


Fig 12. MRI Axial T2WI and T1WI postcontrast (Gd-DTPA):Miliary form.

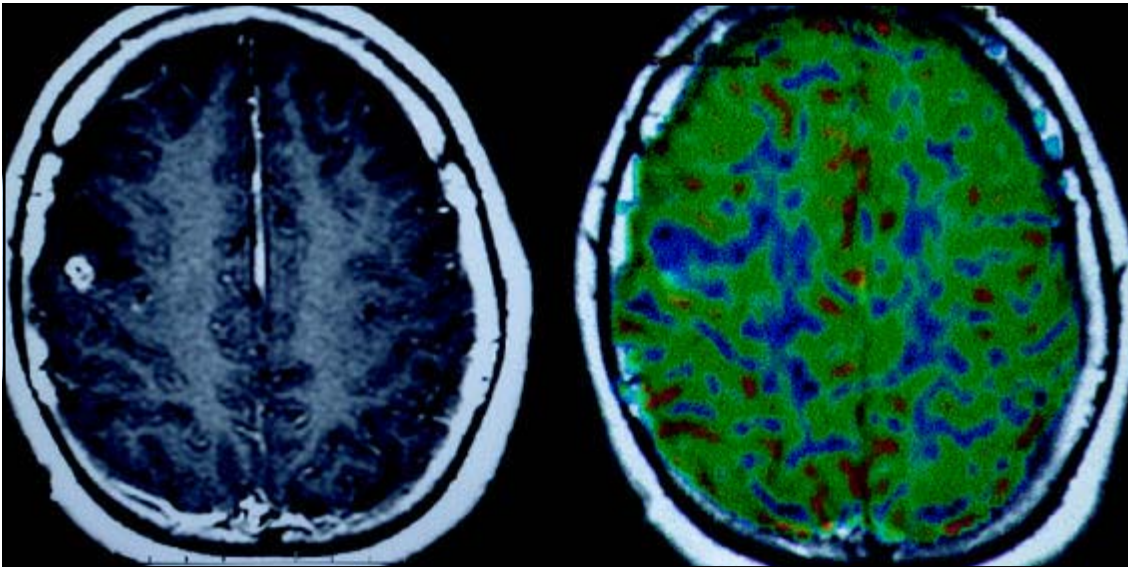


Fig 13. MRI T1WI postcontrast (Gd-DTPA) - ring enhanced lesion in the frontal lobe. MR PWI - without high perfusion. Follow-up confirmed cysticercosis.

quently show these lesions, because their density is similar to that of the cerebrospinal fluid (CSF). On MRI they can present hyperintensity on T1WI in comparison to the CSF due to their protein content. The *C. racemosus* does not have scolex and multiply by wall proliferation. The *C. cellulosae* has scolex and one vesi-

cle. When there is scolex, it is hyperintense on T1WI and generally does not enhance. The cyst is frequently mobile within the ventricles, and can cause acute hydrocephalus. Usually they migrate from the lateral ventricle to the III ventricle and after that to the IV ventricle through the Sylvius aqueduct (Figs 1, 2, 3 and 4).

They are frequently associated with aqueductal stenosis, which could be secondary to coexistent ependymitis, appearing as wall enhancement near the parasite or adhesion by a previous inflammatory process.

Subarachnoid neurocysticercosis

Both the *C. cellulosae* and the *C. racemosus* affect the subarachnoid space, being the latter more frequent⁹. The incidence of cysternal involvement is estimated at 3.5% of all neurocysticercosis cases², being the third most common site². In our study, 30 cases presented in this location. They involve basal cisterns, mainly the supra selar, perimesencephalic, magna and Sylvian fissures.

The cystic masses are multiloculated, do not enhance after gadolinium chelates injection and determine cysternal expansion and deformity. They are related to local inflammatory reaction which can cause leptomeningeal thickening, fibrosis and localized calcifications, most probably representing chronic meningitis (Fig 5). The inflammatory response could lead to vasculitis, affecting the basal perforating vessels, resulting in infarction¹⁰.

The major differential diagnosis are: arachnoid cyst, neuroglial cyst and epidermoid tumor (Figs 6 and 7).

Spinal neurocysticercosis

Cysticercosis may involve the spinal space and/or the spinal cord in CSF less than 1% of the cases, being more frequent the involvement of the subarachnoid space than the spinal cord^{2,9}. The forms observed are: intradural- extramedullary in 54% of the cases, intramedullary in 17% and association of intramedullary and intradural-extramedullary in 17%. Extra dural is very rare with few cases reported.

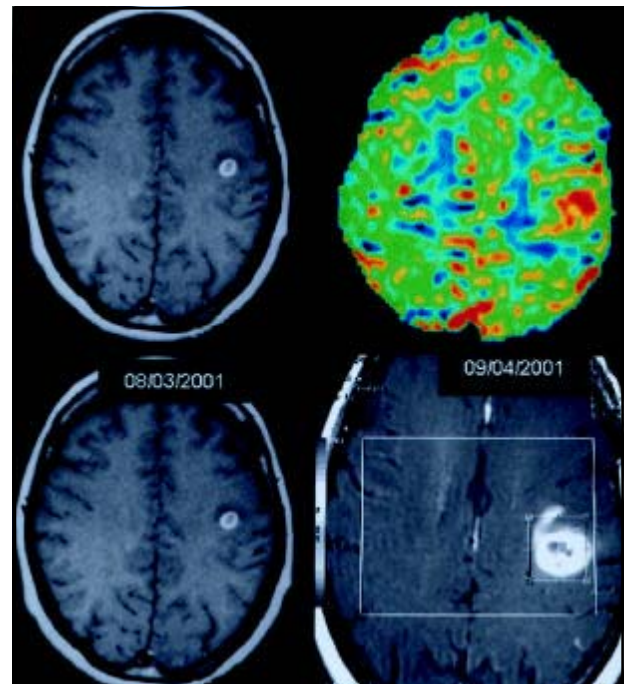


Fig 14. Similar lesion in the left frontal lobe with high perfusion. Follow-up confirmed GBM.

The intradural-extramedullary involvement occurs predominantly due to larval dissemination from brain to the spinal subarachnoid space¹¹. The cysticercus in the subarachnoid space leads to inflammatory reaction and collagen proliferation, being the clinical signs of spinal cysticercosis caused by direct compression of neurological tissue or due to inflammatory reaction. (Ex. arachnoiditis)

The intramedullary cysticercosis results mainly from hematogenic dissemination of extra CNS infectious focuses. The thoracic spine is the most involved in this presentation, because this is the most vascularized spinal segment. For the same reason the cere-

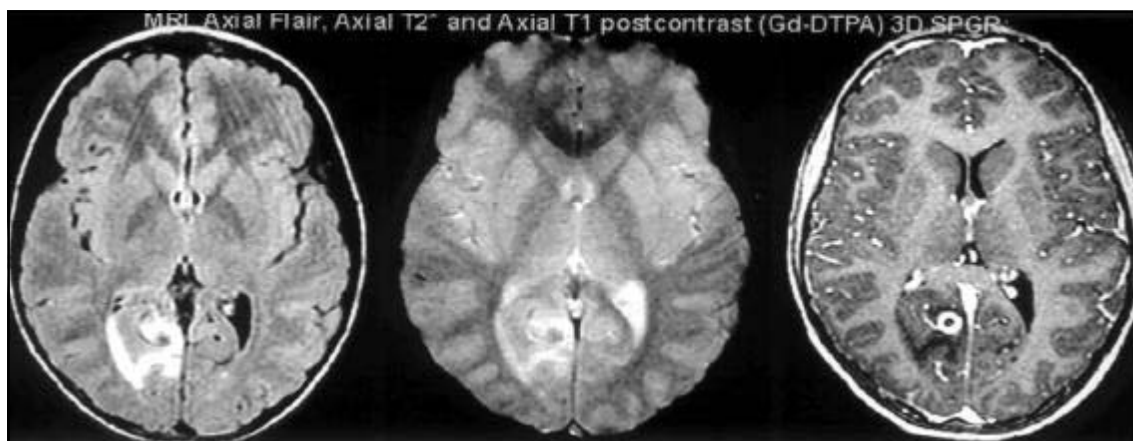


Fig 15. Ring lesion with surrounding edema.

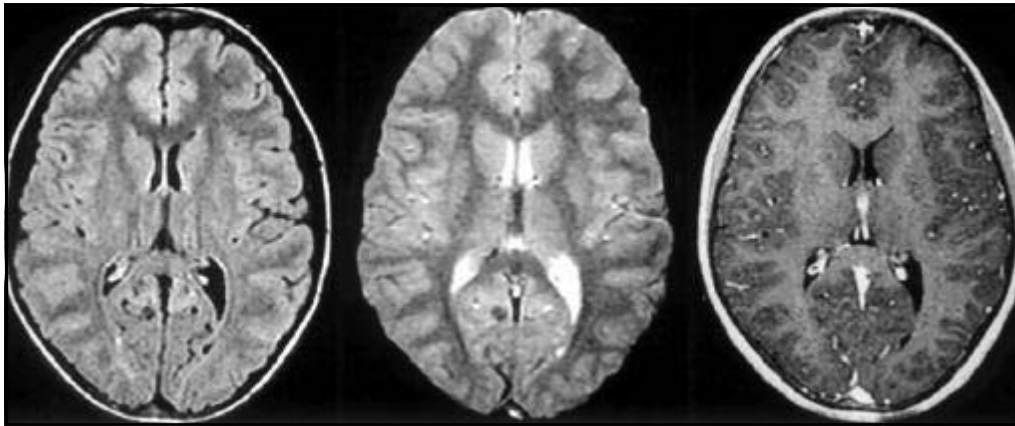


Fig 16. Calcified lesion without surrounding edema.

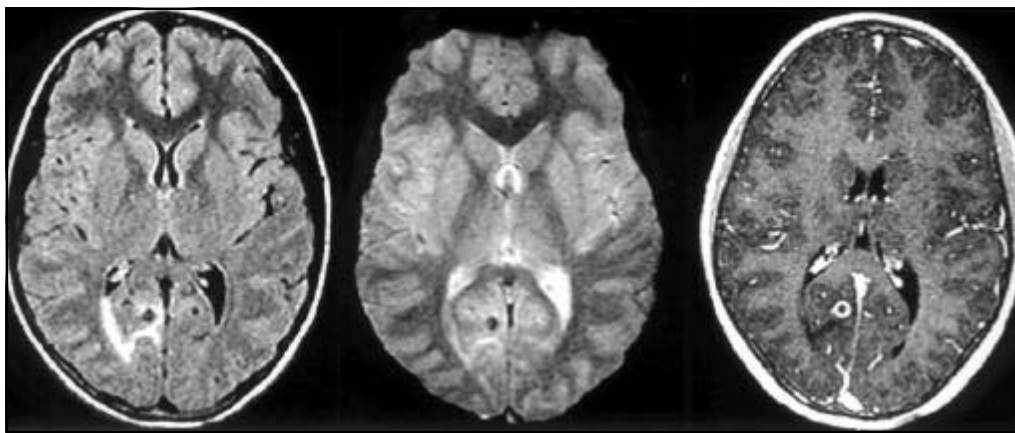


Fig 17. Calcified lesion with late reactivation and perilesional edema.

bral involvement of neurocysticercosis is much more frequent than the spinal one¹¹.

Of the six cases with spinal neurocysticercosis of our casuistic, three were intradural and extramedullary (Fig 8), two were intramedullary (Fig 9) and one was extradural (Fig 10).

Orbital neurocysticercosis

The cysticercus reaches the orbit through the chorioid vessels, having primitive sub-retinian location. During its development the cysticercus needs more space and it either stays in the primitive site and leads to retinal detachment or it perforates the retina with vitreous invasion. Inside the orbit it can induce inflammatory reaction and blindness in 8% of patients¹².

The orbital cysticercosis outside the eyeball generally involves the extra-ocular muscles, leading to myositis which determines motor restriction and squint. The treatment of choice is the surgical removal. Occasionally, the cyst can resolve spontaneously.

On T1 weighted non-contrasted images the parasite appears hyperintense, simulating primary choroidal melanoma. On T2WI the lesion appears hypointense. The differential diagnosis should include retinoblastoma (in children), primary melanoma and metastasis (in older patients)¹³. In our study we had identified only one case involving the orbital extrinsic muscles (Fig 11).

Atypical forms of intraparenchymatous neurocysticercosis

There are two atypical forms of intraparenchymatous presentations: miliary and pseudotumoral.

The miliary form represents massive cysticercus infestation of the CNS and is characterized by multiple small cystic formations diffusely spread out in the brain parenchyma. It is a rare form of presentation, being observed in only one of our cases (Fig 12).

In some cases, neurocysticercosis can present itself with forms indistinguishable from primary or secondary tumors. The solitary lesions can be large

or small, solid or cystic, and can present themselves with wall enhancement or mural nodule, being or not surrounded by edema. The main differential diagnosis of this kind of lesion should include gliomas, hemangioblastomas, neuronal cell tumors (gangliogliomas) and echinococcus. Lesions involving the superior cerebellar vermis in children can be indistinguishable from meduloblastomas or astrocytomas.

In our 113 intraparenchymatous cases, the majority of the non calcified lesions simulated tumors. In one of them, increased MR Perfusion weighted images (PWI) helped us to differentiate cysticercosis from GBM (Figs 13 and 14).

Reactivation of neurocysticercosis

Cerebral calcified lesions in patients with previous neurocysticercosis represent cysticercus's death (immunologic inactivity). In recent studies some theories try to explain the peri-lesional edema in previously calcified lesions¹⁴⁻¹⁶. A plausible explanation proposed is that calcified lesions contain dead cysticercus antigens in insoluble and inaccessible forms and for some reason not yet clarified it could be recognized by the host triggering inflammatory reaction.

It is not well known, why only some calcified lesions trigger inflammatory response.

In our study we had only one case of reactivation of a previously calcified lesion (Figs 15, 16 and 17).

CONCLUSION

MRI is a sensitive and generally specific method in the analysis of different forms of unusual mani-

festations of neurocysticercosis, which should appear in the differential diagnosis of parenchymal, intraventricular, spinal, cysternal and orbital lesions.

REFERENCES

1. Creasy JL, Alarcon JJ. Magnetic resonance imaging of neurocysticercosis. *Top Magn Reson Imaging* 1994;6:59-68.
2. Shandera WX, White AC Jr, Chen JC, Diaz P, Armstrong R. Neurocysticercosis in Houston, Texas: a report of 112 cases. *Medicine* 1994;73:37-52.
3. Latovitzki N, Abrams G, Clark C, Mayeux R, Ascherl Jr G, and Sciarra D. Cerebral cysticercosis. *Neurology*, 1978;28:838-842.
4. Schultz TS, and Ascherl J Cerebral cysticercosis: occurrence in the immigrant population. *Neurosurgery* 1982;3:164-169.
5. Zee C, Segall HD, Miller C, et al. Unusual neuroradiological features of intracranial cysticercosis. *Radiology* 1980;137:397-407.
6. Veronesi R, Spina-França A, Focaccia R. Neurocysticercosis. In: Veronesi R (ed). *Doenças infecciosas e parasitárias*. 8. Ed. Rio de Janeiro: Guanabara Koogan, 1991:820-826.
7. CDC. Editorial note. *JAMA* 1992;2567:1183-1184.
8. Thornton CA, Houston S, Latif AS. Neurocysticercosis and human immunodeficiency virus infection: a possible association. *Arch Neurol* 1992;49:963-965.
9. Byrd SE, Locke GE, Biggers SK, et al. The computed tomographic appearance of cerebral cysticercosis in adults and children. *Radiology* 1982;144:819-823.
10. Levy AS, Lillehei KO, Rubistein D, Steres JC. Subarachnoid neurocysticercosis with occlusion of the major intracranial arteries: case report. *Neurosurgery* 1995;36:183-188.
11. Leite CC, Jinkins JR, Escobar BE, et al. MR imaging of intramedullary and intradural: extramedullary spinal cysticercosis. *Am J Roent*. 1997;169:1713-1717.
12. Silberrt PL, Gubbay SS, Khangure M. MRI findings in a case of neurocysticercosis. *Med J Aust* 1993;159:185-186.
13. Castillo M, Salgado P, Rojas R, et al. Unusual imaging manifestation of neurocysticercosis. *Internat J Neuroradiol* 1996;2:168-175.
14. Nash TE, Patronas NJ. Edema associated with calcified in neurocysticercosis. *Neurology* 1999;53:777-785.
15. Shith T, Pilon L, Keystone J, Kercharczyk W. Persistent MR contrast enhancement of calcified neurocysticercosis lesion. *Am J Neuroradiol* 1998;19:79-82.
16. Litt AW, Mohuchyt T. Neurocysticercosis. *Radiology* 1999;211:472-476.