

Pain-related nociceptive evoked potential and skin wrinkle test in small fiber neuropathy

Potencial evocado nociceptivo relacionado à dor e teste de enrugamento cutâneo na neuropatia de fibras finas

Otto Jesus HERNÁNDEZ FUSTES¹, Cláudia Suemi Kamoi KAY¹, Paulo José LORENZONI¹, Renata Dal-Prá DUCCI¹, Michelle Zonkowski RIBAS², Lineu Cesar WERNECK¹, Rosana Herminia SCOLA¹

A 58-year-old woman with clinically probable small fiber neuropathy (SFN)¹, with normal electroneuromyography, was evaluated with pain-related nociceptive evoked potential (PREP) with a concentric planar electrode stimulation on the dorsum of the hands and feet² and skin wrinkle test (SWT)³. The PREP showed N1 latency delay (Figure 1), compatible with the change in SWT induced by water, which indicated a Grade 0 pattern (Figure 2), as can be seen in sympathetic autonomic small fiber dysfunction.

New electrophysiological tools, combined with SWT and specific neurological examination, contribute to the diagnosis of SFN.

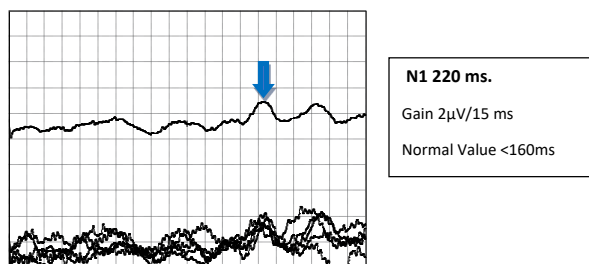


Figure 1. Pain-related nociceptive evoked potential.

Multiple-choice questions with related answers are given in Supplementary Material. The following material is available online for this article: https://www.arquivosdeneuropsiquiatria.org/wp-content/uploads/2022/02/ANP_2021327_material-suplementar_16-02.pdf

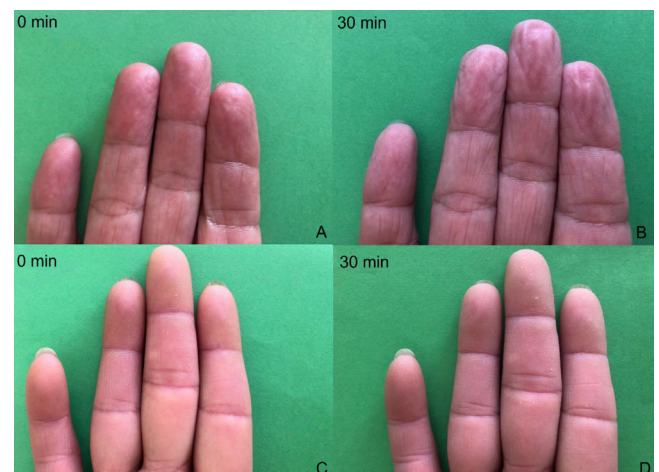


Figure 2. Skin wrinkle test. Patient (C and D). Normal test (A and B).

References

- Cazzato D, Lauria G. Small fibre neuropathy. *Curr Opin Neurol*. 2017 Oct;30(5):490-9. <https://doi.org/10.1097/WCO.0000000000000472>
- Hernandez Fustes OJ, Kay CSK, Lorenzoni PJ, Ducci RDP, Werneck LC, Scola RH. Somatosensory evoked potentials in clinical practice: a review. *Arq Neuro-Psiquiatr*. 2021 sEP;79(9):824-31. <https://doi.org/10.1590/0004-282X-ANP-2020-0427>
- O'Riain S. New and simple test of nerve function in hand. *Br Med J*. 1973 Sep;3(5881):615-6. <https://doi.org/10.1136/bmj.3.5881.615>

¹Universidade Federal do Paraná, Complexo Hospital de Clínicas, Departamento de Clínica Médica, Serviço de Neurologia, Serviço de Doenças Neuromusculares e Desmielinizantes, Curitiba PR, Brazil.

²Universidade Federal do Paraná, Curitiba PR, Brazil.

OJHF: <https://orcid.org/0000-0003-0778-5376>; CSKK: <https://orcid.org/0000-0003-0173-0809>; PJJ: <https://orcid.org/0000-0002-4457-7771>; RDPD: <https://orcid.org/0000-0002-1673-5074>; MZR: <https://orcid.org/0000-0002-9952-1556>; LCW: <https://orcid.org/0000-0003-1921-1038>; RHS: <https://orcid.org/0000-0002-3957-5317>

Correspondence: Otto J. H. Fustes; Email: otto.fustes@hc.ufpr.br.

Conflict of interest: There is no conflict of interest to declare.

Authors' contributions: All authors worked extensively on the manuscript and approved this submitted version; OJHF: conceived the idea for the article, which was written and critically reviewed by all authors.

Received on August 11, 2021; Received in its final form on October 18, 2021; Accepted on October 27, 2021.