

# CELLULAR SCHWANNOMA

## A RARE SPINAL BENIGN NERVE-SHEATH TUMOR WITH A PSEUDOSARCOMATOUS APPEARANCE

### Case report

*José Alberto Landeiro<sup>1</sup>, Carlos Henrique Ribeiro<sup>1</sup>,  
Alexandre C. Galdino<sup>1</sup>, Elizabeth Taubman<sup>2</sup>, Alfredo J. Guarisch<sup>3</sup>*

**ABSTRACT** - We report a case of cellular schwannoma, a rare benign nerve-sheath tumor in a 27 year-old woman. It was presented as a voluminous lesion in the paraspinal region that caused lumbar vertebral body destruction. These features, in association to the microscopic aspects of a hypercellular, pleomorphic neoplasm may lead to a false impression of a malignant tumor. Therefore, it is important to have an accurate examination to confirm the benign nature of this tumor thus avoiding unnecessary therapy.

**KEY WORDS:** cellular schwannoma, benign nerve-sheath tumor, bone destruction.

#### **Schwannoma celular: um tumor benigno com características malignas. Relato de caso**

**RESUMO** - Apresentamos caso de schwannoma celular, um tumor raro da bainha nervosa em mulher de 27 anos. Tratava-se de volumosa lesão que ocupava e destruía o corpo da 4ª vértebra lombar e invadia o retroperitônio. Estes dados associados com achados microscópicos de hiper celularidade, pleomorfismo e atividade mitótica podem dar a falsa impressão de malignidade. Apurado estudo histopatológico e imunohistoquímico confirma a natureza benigna da lesão evitando terapias desnecessárias.

**PALAVRAS-CHAVE:** schwannoma celular, tumor benigno da bainha nervosa, destruição óssea.

Cellular schwannoma, a well-recognized and unusual variant of benign schwannomas, due to its atypical features, may lead to an erroneous diagnosis of malignancy in about 28% of the surgical biopsy and resection specimens<sup>1-3</sup>. First described by Woodruff et al.<sup>4</sup> in 1981, the cellular schwannoma accounts for approximately 5% of the benign peripheral nerve sheath tumors, affects predominately middle-aged adults and occurs mostly as a slowly-growing tumor in the paravertebral region of the medistinum and retroperitoneum<sup>5</sup>. It may show bone erosion and neurological symptoms caused by compression of the nerve roots, and is histopathologically characterized by the presence of compact spindle cells arranged into fascicles, variable nuclear hyperchromasia and pleomorphism, lack of Verocay bodies and typical predominance of Antoni A areas, and

occasional increased mitoses and foci of necrosis<sup>6,7</sup>. Immunohistochemistry and ultrastructural analysis are essential to confirm the diagnosis and to avoid overtreatment with its complications.

We present a case of a cellular schwannoma with histopathological and immunohistochemistry analyses, treated by surgical resection.

#### **CASE**

This 27-year-old woman was presented to our institution for evaluation of intense low-back pain. The patient noted the symptoms 18 months prior to presentation. She has denied numbness or paresthesia symptoms. The pain radiated down the posterior aspect of her right thigh, leg and dorsum muscles of her right foot, and was exacerbated by coughing, sneezing and straining. There was no sign of motor deficit. The patient noted progressive worsening of

<sup>1</sup>Serviço de Neurocirurgia do Hospital da Força Aérea do Galeão, Rio de Janeiro RJ, Brasil (HFAG); <sup>2</sup>Neuropatologista do HFAG; <sup>3</sup>Cirurgião e oncologista do HFAG.

Received 17 May 2003. Accepted 21 August 2003.

*Dr. José Alberto Landeiro - Rua Conde de Bonfim 211/310 - 20520-050 Rio de Janeiro RJ - Brasil.*

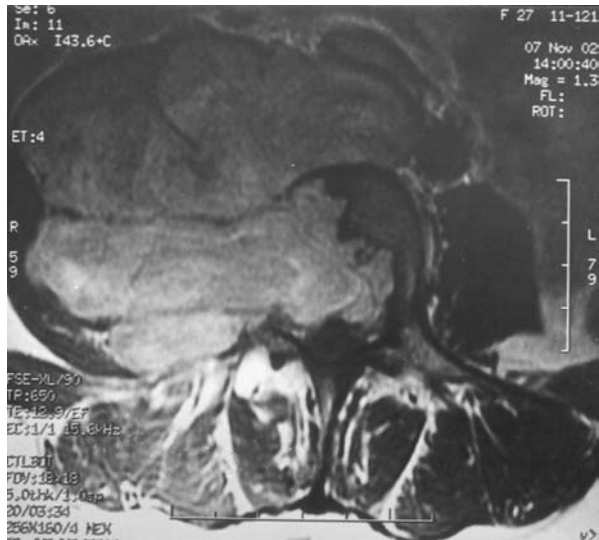

Fig 1. Preoperative axial T1MRI demonstrate a lesion destroying vertebral body and invading the retroperitoneum.

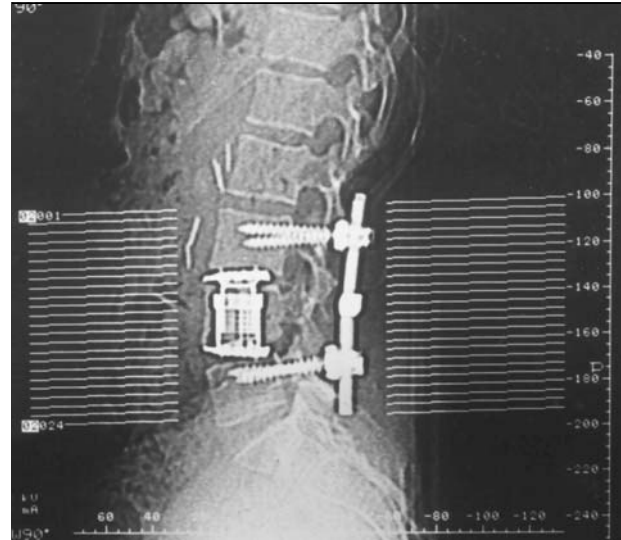


Fig 2. Postoperative CT after lumbar vertebral body reinforcement using titanium mesh cage and posterior instrumentation.

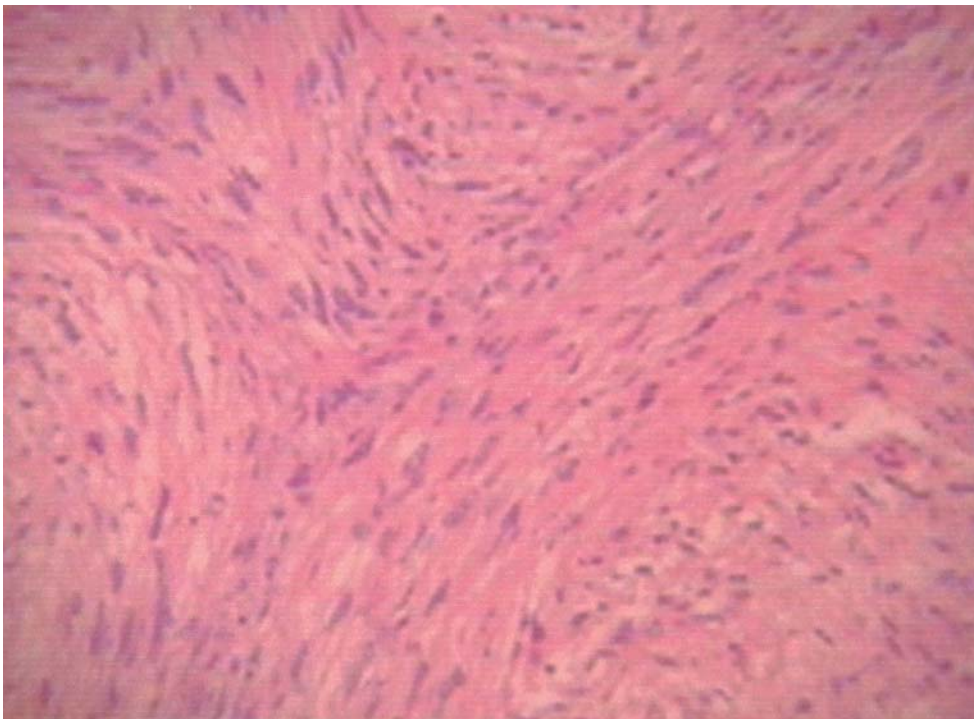


Fig 3. Interlacing fascicles of bipolar spindle cells (HE 400X).

pain in the ensuing months. Neurological examination revealed a patellar hippo-reflex with no other alterations, and there was no history of trauma. She underwent a lumbosacral radiography, computed tomography (CT) and magnetic resonance imaging (MRI) and these investigations showed a large paravertebral mass causing the erosion of the L4 vertebral body with L4 nerve root involvement, and extending to the contiguous soft tissues. An angiography study showed intense mass enhancement and an endovascular embolization was performed. A two-step sur-

gical treatment was performed requiring anterior and posterior access to stabilize and excise the tumor. In a first procedure, anterior access permitted the complete resection of the tumor, L4 corpectomy and anterior stabilization of the lumbar spine. A second surgery was performed one week after with laminectomy and transpedicular stabilization of L3, L4 and L5 vertebral bodies (See Figs 1 and 2).

*Histopathological and Immunohistochemical Findings (Figs 3 and 4)* - The tumor was solid and partially encapsula-

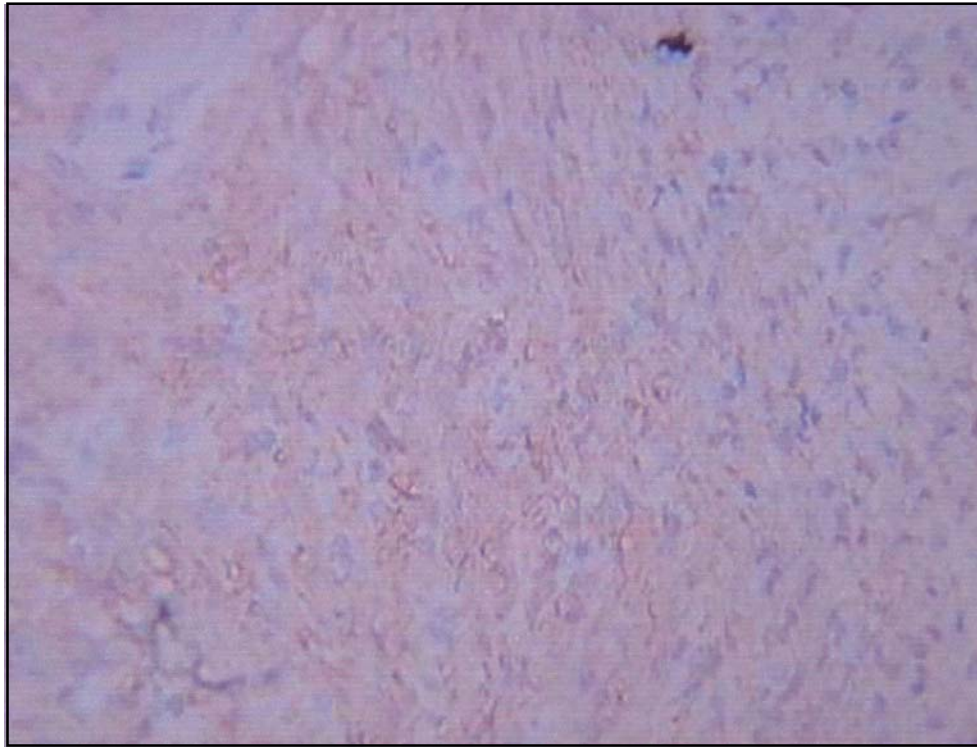


Fig 4. The tumor cells were immunocytochemically positive for S-100 protein.

ted, the anterior portion revealed a well-defined capsule although it lacked posteriorly (at this point, on MR images, there was an infiltrative process with lumbar vertebral destruction). This lesion showed compact spindle-cells areas, densely populated, forming a fascicular, storiform and whorled-growth pattern. Sometimes, there was a "herring-bone" arrangement giving the tumor a fibrosarcoma-like appearance. The packed cells had eosinophilic cytoplasm with indistinct membrane and a wavy, fusiform and hyperchromatic nucleus. Low mitotic activity was also detected but atypical mitosis and necrosis were not observed. It shares some microscopic features with the classic schwannoma such as foci of hyalinized blood vessels, foamy histiocytes (xantoma cells) and lymphocytes collections but in contrast to the classic form, this variant is devoid of Verocay bodies (cellular palisades) and Antoni B areas (loose, myxoid regions). An immunohistochemical examination showed some degree of positivity for GFAP (glial fibrillary acidic protein) and a strong expression for S-100 protein providing then support for a Schwann cell derivation.

## DISCUSSION

Cellular schwannoma was first described by Woodruff et al.<sup>4</sup> in 1981 and is a highly cellular nerve-sheath benign tumor, which arises in spinal nerves. The tumor has a female predominance, a median age of 55 years (15-79 years) and most of them are located in the retroperitoneum or mediastinum<sup>2</sup>. Its radiologic and histologic appearance mimicks that of a malignant neoplasm, but its benign nature is esta-

blished after adequate examination. The outcome is favorable without metastatic spread and this is the principal reason for delineating it as a separate entity<sup>8</sup>.

The present case illustrates a quite large tumor presented in the paravertebral region of the retroperitoneum. It also involves the spine above the sacrum level (L4) showing a purely lytic destructive lesion. The radiological findings would lead to the erroneous diagnosis of a soft tissue sarcoma<sup>1,4,5,8,9</sup>. However, the microscopic features in this case of a nerve-sheath benign tumor are distinct from the malignant ones. Also, this benign neoplasm failed to reveal any metastatic potential<sup>8,10</sup> or caused patient's death but it may recur if incompletely excised.

The typical tumor is solitary and at least partially encapsulated. The cut surface is firm, grayish-white in color but showing irregular yellow patches. The light microscopic findings readily demonstrate a thick capsule often with lymphoid aggregated and many fascicular areas with increased cellularity like Antoni A areas of a classic schwannoma. These are compactly arranged in spindle cells, whorls, sheets or bundles. They have an eosinophilic cytoplasm and elongated, wavy nuclei often hyperchromatic and slightly pleomorphic. Verocay bodies are not present within the cellular schwannoma<sup>11</sup>. Also of note, aggregated of foamy histiocytes (lipid laden histio-

cytes), hyalinized and thick-walled blood vessels and rare mitotic figures were also seen.

Distinction from other tumors exhibiting spindle cells fascicles (fibrosarcoma, synovial sarcoma, malignant fibrous histiocytoma and malignant peripheral nerve-sheath tumor) is somewhat difficult and it has been suggested that the schwannoma cellular should be included in the group of the so-called pseudosarcomas<sup>8</sup>. Unlike these malignant tumors, the schwannoma cellular reveals a strong and diffuse reactivity for S-100 and an unevenly distributed reactivity for GFAP on immunohistochemistry study<sup>9,12</sup>. Furthermore, the clinical course is benign and the recommended treatment is surgical excision<sup>13,14</sup>.

In conclusion cellular schwannoma, a pseudosarcomatous entity, is a rare benign neoplasm that may cause bone erosion and reveals histological features of a pleomorphic and hypercellular tumor but the gross total resection appears to be the curative treatment yielding favorable results, and no adjuvant therapy being necessary<sup>2</sup>. Distinction from malignant tumors is possible if we use strict criteria on histological and immunohistochemical analyses, avoiding occasional mistaken diagnoses.

## REFERENCES

1. Alberghini M, Zanella L, Bachinni P, Bertoni F. Cellular Schwannoma: a benign neoplasm sometimes overdiagnosed as sarcoma. *Skeletal Radiol* 2001;30:350-353.
2. Casadei GP, Scheithauer BW, Hirose T, Manfrini M, Van Houton C, Wood MB. Cellular Schwannoma a clinicopathologic, DNA flow cytometric, and proliferation marker study of 70 patients. *Cancer* 1995;75:1109-1110.
3. Henke AC, Salomão DR, Hughes JH. Cellular Schwannoma mimics a sarcoma: an example of a potential pitfall in aspiration cytodiagnosis. *Diagn Cytopathol* 1999;20:312-316.
4. Woodruff JM, Godwin TA, Erlandson RA, Susin M, Martini N. Cellular Schwannoma: a variety of Schwannoma sometimes mistaken for a malignant tumor. *Am J Surg Pathol* 1981;5:733-744.
5. Megahed M, Ruzicka T. Cellular Schwannoma. *Am J Dermatopathol* 1994;16:418-421.
6. Deruaz JP, Janzer RC, Costa J Cellular Schwannomas of the intracranial and intraspinal compartment: morphological and immunological characteristics compared with classical benign schwannomas. *J Neuropathol Exp Neurol* 1993;52:114-118.
7. Kindblom LG, Ahlden M, Meis-Kindblom JM, Stenman G Immunohistochemical and molecular analysis of p53, MDM2, proliferating cell nuclear antigen and Ki67 in benign and malignant peripheral nerve sheath tumors. *Virchows Arch* 1995;427:19-26.
8. Fletcher CD, Davies SE, McKee PH. Cellular Schwannoma: a distinct pseudosarcomatous entity. *Histopathology* 1987;11:21-35.
9. Yamamoto K, Miyagawa J, Katsura H, et al. Retroperitoneal cellular Schwannoma: report of a case diagnosed by the presence of S-100 protein. *Jpn J Med* 1991;30:487-490.
10. Looding P, Kindblom LG, Angervall L, Stenman G. Cellular Schwannoma: a clinicopathologic study of 29 cases. *Virchows Arch A Pathol Anat Histopathol* 1990;416:237-248.
11. White W, Shiu MH, Rosenblum MK, Erlandson RA, Woodruff JM. Cellular Schwannoma. A clinicopathologic study of 57 patients and 58 tumors. *Cancer* 1993;15;66:1266-1275.
12. Seppala MT, Haltia MJ. Spinal malignant nerve-sheath tumor or Cellular Schwannoma? A striking difference in prognosis. *J Neurosurg* 1993;79:528-532.
13. Patocskai EJ, Tabatabaian M, Thomas MJ. Cellular Schwannoma: a rare presacral tumor; *Can J Surg* 2002;45:141-144.
14. Takeyama M, Koshino T, Nakazawa A, Nitto H, Nakamura J, Saito T. Giant intrasacral cellular schwannoma treated with high sacral amputation; *Spine* 2001;15;26:216-219.