

# THROMBOLYTIC THERAPY FOR ACUTE EXTRA-CRANIAL ARTERY DISSECTION

## Report of two cases

Osama O. Zaidat<sup>1</sup>, Jose Americo M. Fernandes Filho<sup>1</sup>, Gurwant Singh<sup>1</sup>, Jose I. Suarez<sup>1,2</sup>

**ABSTRACT** - Extra-cranial arterial dissection accounts for 10% of strokes in young people. Information on safety of thrombolytic administration in this group is limited. The literature, however, does not favor use of thrombolytics for myocardial ischemia when peripheral arterial dissection coexists. Based on the clinical and radiological features, two patients who presented with acute stroke secondary to arterial dissection were considered for thrombolysis. One of them received intra-venous recombinant tissue plasminogen activator (rtPA), and the other patient received intra-arterial rtPA. There were no post thrombolysis complications. This report supports feasibility of administering thrombolytics in acute ischemic strokes resulting from extra-cranial arterial dissection. Future larger studies are necessary to determine the efficacy, safety and long-term outcome in this patient population.

**KEY WORDS:** thrombolysis, stroke, dissection, internal carotid artery.

### **Terapia trombolítica em disseções arteriais cérvico-cefálicas agudas: relato de dois casos**

**RESUMO** - Disseção arterial cérvico-cefálica corresponde a 10 % dos acidentes vasculares cerebrais (AVC) em jovens. Informação sobre a segurança da administração de trombolíticos neste grupo é limitada. A literatura médica, entretanto, não favorece o uso de trombolíticos em isquemia miocárdica na coexistência de disseção arterial periférica. Baseado nas características clínicas e radiológicas, dois pacientes com AVC agudo secundário a disseção arterial foram considerados para terapia trombolítica. Um deles recebeu rtPA intravenoso e o outro paciente recebeu rtPA intra-arterial. Não houve complicações pós-trombólise. Este relato suporta a possibilidade do tratamento destes pacientes com terapia trombolítica. Estudos maiores são necessários para determinar a eficácia, segurança e resultados a longo prazo nesta população de pacientes.

**PALAVRAS-CHAVE:** trombólise, acidente vascular cerebral, disseção, artéria carótida interna.

Strokes in young adults resulting from spontaneous dissection of the cervical segment of the extra-cranial carotid artery are being reported with increasing frequency<sup>1-8</sup>. Ischemia may result from occlusion of the internal carotid artery (ICA) and distal stump embolization to the distal intra-cranial arteries, and may account for major morbidity and mortality in young stroke victims. Anticoagulation has been used for this condition but caution has been advised due to the risk of extending the dissection<sup>5</sup>. The lack of therapeutic options has been a limiting factor for the clinical recovery of stroke victims, until the advent of thrombolytic therapy. Experience is limited in the use of thrombolytics for acute ischemic strokes resulting from acute extra-cranial arterial dissection.

We report our experience with two patients who received this treatment.

### **CASES**

*Case 1.* 21-year old right-handed man, presented within an hour of onset of symptoms. He was agitated, globally aphasic, had left gaze preference, right homonymous hemianopsia and right hemiplegia with a National Institute of Health Stroke Scale (NIHSS) of 21. Head CT scanning did not reveal intra-cranial hemorrhage (Fig 1). Intravenous recombinant tissue plasminogen activator (rtPA) was administered (0.6 mg/kg) after the family consented. There were no post-thrombolysis complications. Patient was taken for an immediate cerebral angiogram for possible intra-arterial thrombolysis according to our institutional review board (IRB) approved protocol for acute stro-

---

From the Department of Neurology<sup>1</sup> & Neurosurgery<sup>2</sup>, University Hospitals of Cleveland, Case Western Reserve University, Cleveland, Ohio, USA. Presented in part at the XIX Brazilian Congress of Neurology, Salvador, BA. October 2000.

Received 9 April 2001, received in final form 14 July 2001. Accepted 25 July 2001.

Osama O. Zaidat, MD - University Hospital of Cleveland / Department of Neurology - 11100 Euclid Avenue / Fifth Floor Hanna House - Cleveland, OH 44106 USA. FAX 1 216/844-5066 . E-mail: ooz@po.cwru.edu

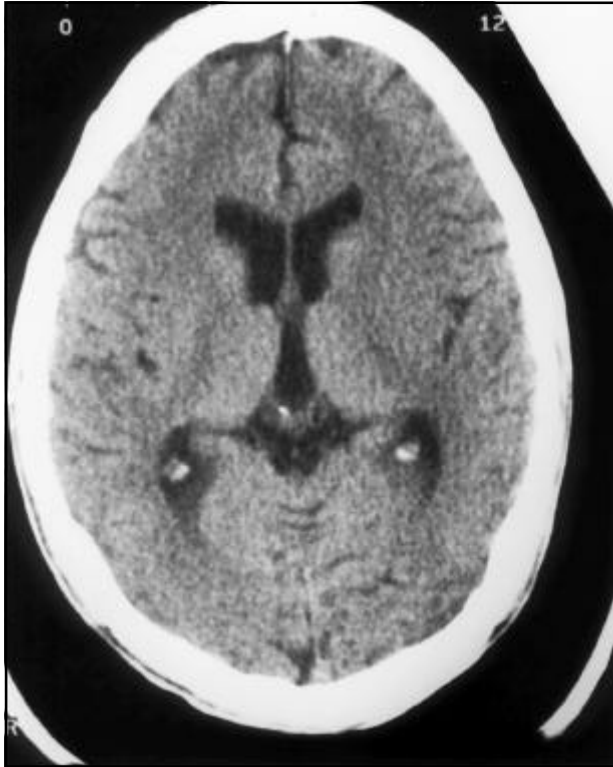


Fig 1. Head CT scan pre thrombolysis without intra-cranial hemorrhage.

ke. The cerebral angiogram revealed left ICA dissection with tapering and occlusion, and poor collateral flow to the left middle cerebral artery (MCA) from the contralateral anterior circulation (Fig 2). Due to the presence of complete occlusion and technical difficulty in placing the catheter in close proximity to the clot for administering the rtPA, the procedure was halted. The rest of the 0.9mg/kg intravenous dose was completed. NIHSS improved to

15 at 72 hours and the patient was discharged in stable condition. Nine months later he was independent and able to walk with braces with only some word finding difficulty. Follow-up magnetic resonance angiography (MRA) showed partial recanalization of left ICA and MCA. One year later MRA of both intra and extracranial circulation was normal (Fig 3).

**Case 2.** 43-year old left-handed woman with history of dilated cardiomyopathy presented with left gaze preference and right hemiplegia of three hour duration. She also had right homonymous hemianopsia, right hemineglect and hemihypesthesia to primary sensations (NIHSS of 27). Head CT scan was normal. She was considered for intra-arterial thrombolysis, as approved by our IRB, since she presented 3 hours after the onset of symptoms. Her family consented for intra-arterial thrombolysis with rtPA. Cerebral angiogram showed left ICA dissection as well as a clot at the bifurcation of the left MCA and proximal part of anterior cerebral artery (ACA). Thrombolysis was administered with partial recanalization. There were no post-thrombolysis complications. Hospital and clinical course were unchanged, despite improvement in NIHSS to 23 on 72 hours examination. She remained dependent with severe disability at 18 months follow up.

## DISCUSSION

Strokes related to dissection of extra-cranial cervical arteries may range between 6.2% to 10% in young adults (less than 40 years of age), with an estimated annual incidence in the United States of at least 2.6 per 100,000 persons<sup>3</sup>. Abrupt onset of pain usually localized to the head, face or neck is part of the chief complaint in more than 60% of patients<sup>3,6</sup>, and ultimately resolve in 95% of patients<sup>8</sup>. Horner's syn-

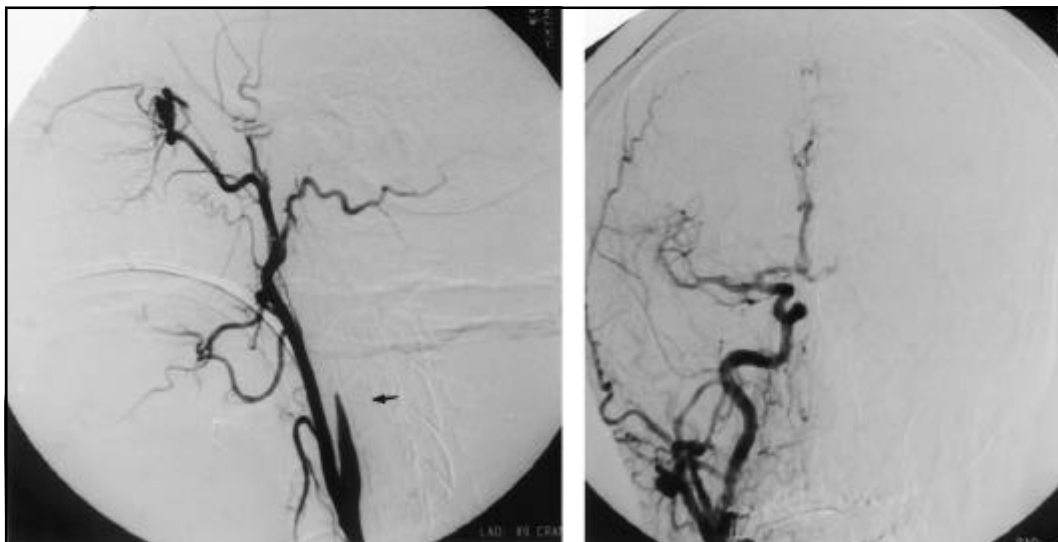


Fig 2. Angiogram demonstrating left internal carotid artery dissection with occlusion (left, arrow). Poor collateral flow to left middle cerebral artery (right).

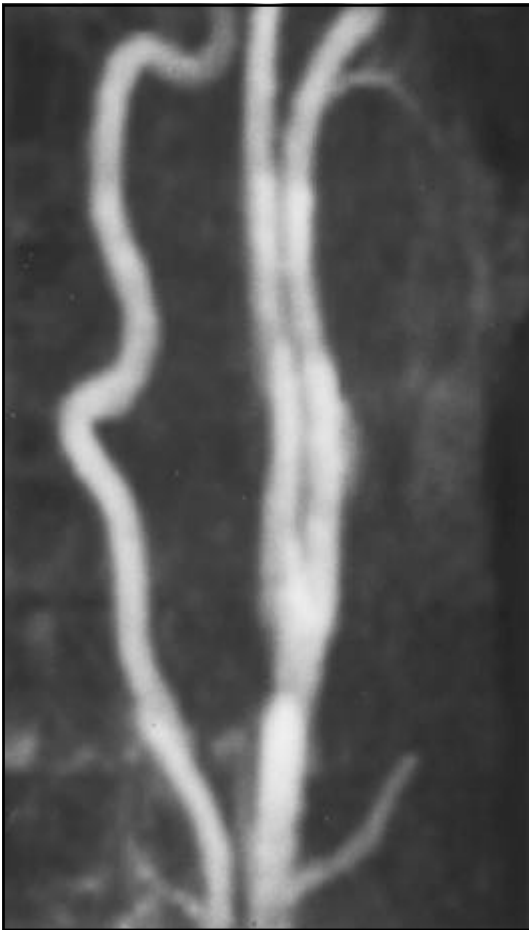

Fig 3. MRA of extra-cranial left internal carotid artery reveals normal lumen 1 year later.

drome ipsilateral to the dissection is present in 14% to 58% of affected patients<sup>4</sup>. Signs of cerebral ischemia are often delayed and will eventually occur in 53% to 90% of the patients<sup>4</sup>. With the turning and extension of the head, ICA is stretched over the lateral articular surface and the pedicle of the axis vertebra, resulting in injury to the vessel, and usually a hemorrhage within the media splits the vessel wall<sup>3</sup>. Subintimal dissections tend to cause narrowing of the arterial lumen, and subadventitial dissections tend to cause arterial dilatation<sup>8</sup>. Dissection often originates 2 cm distal to the bifurcation and extends rostrally a variable distance to the base of the skull<sup>3</sup>. Exposure of the basement membrane leads to platelet aggregation with thrombus formation. Thrombi can be clinically occult, extend and occlude the vessel, or embolize<sup>9,10</sup>.

Embolic strokes in the territory of ICA are associated with high morbidity and mortality, therefore anticoagulation in the presence of carotid dissec-

tion seems to be a reasonable choice in the acute phase of the event. Endovascular treatments, such as stent placement, are an option for symptomatic patients and have been used successfully<sup>11</sup>. However, they are still experimental. For patients who develop stump emboli in the presence of arterial dissection, the role of thrombolytics is unclear. We treated two such patients with spontaneous ICA dissection. Patient one who was only 21 years old received IV tPA within 3 hours of the symptom onset, and had no complications. Significant improvement was seen within hours after treatment and the patient was independent at 9 months. The first patient was younger than the second patient who received intra-arterial tPA within 6 hours of the symptom onset, and who failed to show any clinical improvement. Neither patient had complications related to the administration of thrombolytic therapy.

Our report suggests that thrombolysis might be feasible for acute embolic strokes resulting from arterial dissection without causing worsening of arterial wall tearing. The results are in agreement with Derex et al.<sup>1</sup> and Jacobs et al.<sup>9</sup> who suggested that IV rtPA might be safe when given within seven hours and 3 hours of stroke onset respectively, in presence of cervicocerebral artery dissection. No conclusion can be drawn at this time regarding the safety and efficacy of thrombolytic therapy in this clinical setting. Larger studies are needed to clarify these issues.

## REFERENCES

1. Derex L, Nighoghossian N, Turjman F, et al. Intravenous tPA in acute ischemic stroke related to internal carotid artery dissection, *Neurology* 2000;54:2159-2161.
2. Bogousslavsky J, Despland PA, Regli F, et al. Spontaneous carotid dissection with acute cortical stroke. *Arch Neurol* 1987;44:137-140.
3. Stahmer SA. Carotid and vertebral artery dissections. *Emergency Medicine Clinics of North America* 1997;15:677-699.
4. Ast G, Woimant F, Georges B, et al. Spontaneous dissection of the internal carotid artery in 68 patients. *Eur J Med* 1993;2:466-472.
5. Adams HP, Aschenbrener CA, Kassell NF, et al. Intracranial hemorrhage produced by spontaneous dissecting Intracranial aneurysm. *Arch Neurol* 1982; 39:773-776.
6. Anson J, Crowell RM. Cervicocranial arterial dissection. *Neurosurgery* 1991;29:89-96.
7. Mokri B, Sundt TM Jr, Houser OW, Piepgras DG. Spontaneous dissection of the cervical internal carotid artery. *Ann Neurol* 1986; 19:126-138.
8. Luken MG III, Ascherl GF Jr, Correll JW, et al. Spontaneous dissecting aneurysms of the extracranial internal carotid artery. *Clin Neurosurg* 1979; 26:353-375.
9. Jacobs A, Rudolf J, Neveling M, et al. Systemic thrombolytic therapy of cerebro-cervical artery dissections: risk or benefit? [abstract]. *Cerebrovas Dis* 1999; 9(Suppl 1):100.
10. Rudolf J, Neveling M, Grond M, Schmulling S, et al. Stroke following internal carotid occlusion - a contraindication for intravenous thrombolysis? *Eur J Neurol* 1999;6:51-55.
11. Levy DI. Endovascular treatment of carotid artery occlusion in progressive stroke syndromes: technical note. *Neurosurgery* 1998;42:186-191.