

Three territory sign in cancer-related acute ischemic stroke

Sinal de três territórios arteriais em acidente vascular cerebral isquêmico agudo relacionado a câncer

Marcelo Houat DE BRITO^{1,2,3}, Gabriela Almeida PIMENTEL^{1,2}, Marcos Fernando de Lima DOCEMA¹, Mateus Correa da TRINDADE¹

A 64-year-old man, on regular use of apixaban due to atrial fibrillation (AF), was admitted to the hospital with sudden right upper limb weakness. Brain MRI (Figure 1) demonstrated a Three Territory Sign (TTS, bilateral anterior and posterior circulation acute ischemic diffusion-weighted imaging lesions). Complimentary etiologic investigation diagnosed an adenocarcinoma of the ascending

colon by full-body 18F-FDG PET/CT (Figure 2), followed by a local biopsy.

TTS is a highly specific marker and six times more frequently observed in malignancy-related than AF-related ischemic stroke¹. The prothrombotic state of malignancy occurs due to the ability of tumor cells to activate the coagulation system².

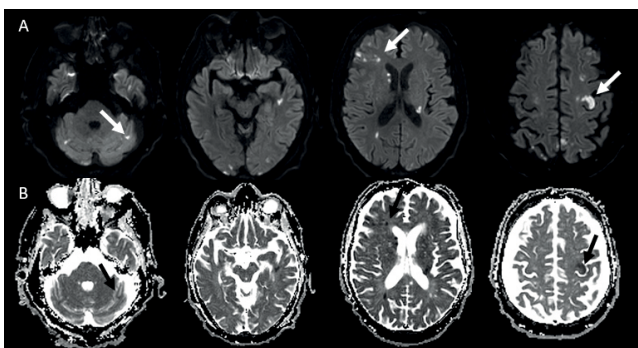


Figure 1. Brain MRI diffusion-weighted image — DWI (Row A) showing multiple high signal intensity lesions in the cerebral and cerebellar hemispheres involving three different vascular territories (Three Territory Sign), with apparent diffusion coefficient — ADC (Row B), showing the same lesions with low signal intensity.

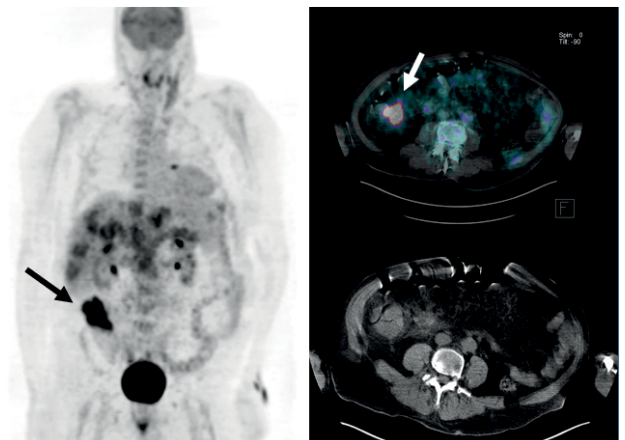


Figure 2. FDG-PET/CT showing hypermetabolic alterations compatible with cecum/ascending colon tumor (arrows) extending to adjacent adipose planes.





References

1. Nouh AM, Staff I, Finelli PF. Three Territory Sign: An MRI marker of malignancy-related ischemic stroke (Trousseau syndrome). *Neurol Clin Pract*. 2019 Apr;9(2):124-8. <https://doi.org/10.1212/CPJ.0000000000000603>
2. Caine GJ, Stonelake PS, Lip GY, Kehoe ST. The hypercoagulable state of malignancy: pathogenesis and current debate. *Neoplasia*. 2002 Nov-Dec;4(6):465-73. <https://doi.org/10.1038/sj.neo.7900263>

¹Hospital Sírio-Libanês, São Paulo SP, Brazil.

²Universidade de São Paulo, Faculdade de Medicina, Hospital das Clínicas, Departamento de Neurologia, São Paulo SP, Brazil.

³Instituto do Câncer do Estado de São Paulo, São Paulo SP, Brazil.

Marcelo Houat DE BRITO  <https://orcid.org/0000-0001-7521-1388>; Gabriela Almeida PIMENTEL  <https://orcid.org/0000-0002-6576-850X>; Marcos Fernando de Lima DOCEMA  <https://orcid.org/0000-0002-7560-1463>; Mateus Correa da TRINDADE  <https://orcid.org/0000-0003-1572-8072>

Correspondence: Marcelo Houat de Brito; E-mail: marcelohbrito@gmail.com

Conflict of interest: There is no conflict of interest to declare.

Received on December 13, 2019; Received in its final form on March 08, 2020; Accepted on March 19, 2020.