

Investigation of magnetic resonance imaging texture analysis as an aid tool for characterization of refractory epilepsies

Investigação da análise de textura em imagem de ressonância magnética como auxílio para caracterização de epilepsias refratárias

Maurício Martins Baldissin¹, Edna Marina de Souza²

ABSTRACT

Refractory epilepsies are syndromes for which therapies that employ two or more antiepileptic drugs, separately or in association, do not result in control of crisis. Patients may present focal cortical dysplasia or diffuse dysplasia and/or hippocampal atrophic alterations that may not be detectable by a simple visual analysis in magnetic resonance imaging. The aim of this study was to evaluate MRI texture in regions of interest located in the hippocampi, limbic association cortex and prefrontal cortex of 20 patients with refractory epilepsy and to compare them with the same areas in 20 healthy individuals, in order to find out if the texture parameters could be related to the presence of the disease. Of the 11 texture parameters calculated, three indicated the existence of statistically significant differences between the studied groups. Such findings suggest the possibility of this technique contributing to studies of refractory epilepsies.

Keywords: refractory epilepsies, magnetic resonance, texture analysis.

RESUMO

Epilepsias refratárias compreendem síndromes para as quais as terapias que empregam duas ou mais drogas antiepilépticas, isoladamente ou em associação, não resultam no controle da frequência das crises. Portadores podem apresentar displasias corticais focais ou difusas e/ou alterações atróficas hipocâmpais que, em alguns casos, não são detectáveis por uma simples análise visual nas imagens de ressonância magnética. Nesse contexto, o objetivo deste estudo foi avaliar a textura de imagens de RM em regiões de interesse localizadas nos hipocâmpos, córtex de associação límbico e córtex pré-frontal de 20 pacientes com epilepsia refratária e compará-las às mesmas áreas de um grupo de 20 indivíduos saudáveis. Dos 11 parâmetros de textura calculados, três indicaram a existência de diferenças estatisticamente significantes entre os grupos estudados. Tais achados sugerem a possibilidade desta técnica contribuir para os estudos das epilepsias de difícil controle.

Palavras-chave: epilepsias refratárias, ressonância magnética, análise de textura.

Refractory epilepsies involve syndromes for which the therapies that employ two or more antiepileptic drugs (AEDs), separately or in association, do not result in control of crisis frequency^{1,2}. In Brazil, among the people affected by epilepsy, totaling approximately 3 million, 30% are refractory to drug therapy³.

Among patients with refractory epilepsy, 40% present hippocampal atrophy in cases of temporal lobe epilepsy (TLE)^{4,5} and 35% present focal cortical dysplasia (FCD) in cases of extratemporal epilepsy⁶.

FCD is characterized by alterations in the microarchitecture of the cerebral cortex, in which dysmorphic neurons (giant, dysplastic) and balloon cells may or may not be observed. The presence or absence of abnormal cells results in two possible classifications for FCD. In type 1 FCD, we can observe the loss of the laminar pattern of the cortex without the presence of abnormal cells; in type 2 FCD, in turn, there is the presence of dysplastic neurons or balloon cells associated with loss of cortical lamination. In the magnetic resonance imaging (MRI), the FCD findings include thickening of

¹Departamento de Neurologia, Faculdade de Ciências Médicas, Universidade Estadual de Campinas, Campinas SP, Brazil;

²Departamento de Engenharia Biomédica, Faculdade de Engenharia Elétrica e Computação, Universidade Estadual de Campinas, Campinas SP, Brazil;

Correspondence: Maurício Martins Baldissin; Clínica de Neurodiagnose; Avenida Dr. Pedro Soares de Camargo 543 / sétimo andar / conj. 73/74; 13208-080 Jundiaí SP - Brasil; E-mail: contato@neurodiagnose.com.br

Conflict of interest: There is no conflict of interest to declare.

Received 17 June 2013; Received in final form 03 July 2013; Accepted 10 July 2013.

the cortex, abnormal cortical signals and blurring in areas in cortico-subcortical transition. Of the patients that present epilepsy associated with FCD, approximately 55% are refractory to the medication⁶.

TLE is a syndrome in which the ictal activity starts in the temporal lobe, where it is possible to observe the occurrence of mesial temporal sclerosis (MTS), which besides the hippocampus can also affect neighboring structures such as the amygdala and the entorhinal cortex, like shows the Figure 1. In MRI, it is possible to observe atrophies both of the hippocampus and of the other temporal lobe structures^{5,7}. Of the patients affected by this syndrome, 40% are refractory to the medication⁵.

Nevertheless, many patients with a clinical picture of refractory epilepsy present visibly normal MRI and no volumetric abnormality in the brain structures⁵⁻⁹. Various studies show that TLE involves the mesial limbic structures, which are abnormal in many patients. The surgical removal of these areas can contribute to crisis control¹⁰⁻¹².

MRI is a diagnostic imaging technique broadcast that has been widespread since the early 80s. It is a method that enables the obtainment of images of organs with high spatial resolution without the use of ionizing radiation. The technique is used extensively in neurology, both for structural and functional evaluations. The versatility of the image capture parameters and the diversity of data processing tools enable its adaptation to a vast array of clinical situations.

In this study we used MRI processing by texture analysis, which is being increasingly explored in clinical surveys. This is because histological modifications may be revealed as alterations in the MRI signal detected by this technique. In this case, the statistical parameters of texture of these images may be different from those observed for normal subjects¹³⁻¹⁶.

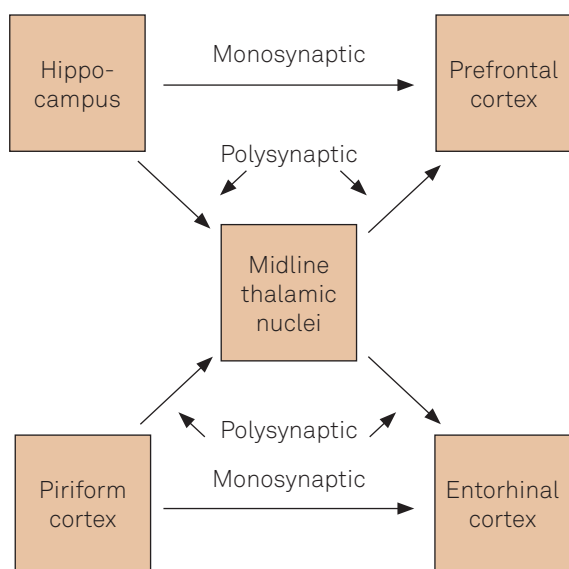


Figure 1. Model of propagation of epileptic seizures in refractory epilepsies. Adapted of Thom and Bertram¹⁰.

The texture of an MRI image, in this study, refers to the appearance, structure and arrangement of the objects along it. It is a descriptor with the potential to distinguish between superficial characteristics of objects in the image, such as uniformity, roughness and smoothness. Although there are several ways of describing the texture of images, the approach that has been applied most often to medical images is the co-occurrence matrix, which is based on the distribution of the grey levels in a given region of interest (ROI) of the evaluated image and on their neighborhood relations¹⁷⁻¹⁹.

The application of different approaches of the texture analysis technique to the study of epilepsy is not new. In 2001, Yu et al. found alterations of texture in the hippocampus contralateral to the one that presented atrophy in patients with TLE²¹. In 2003, Bonilha et al. confirmed the efficiency of this technique in detecting hippocampal sclerosis (HS) in cases of mesial temporal lobe epilepsy (MTLE)²⁰. As a result, they observed that most of the texture parameters calculated made it possible to distinguish differences between the sclerotic hippocampal and contralateral tissues of patients and the normal hippocampal tissues of control subjects.

Bernasconi²² and Antel et al.²³ employed another texture analysis approach to evaluate cortical thickening in FCDs. With the characterization of the texture of dysplastic lesions, they drew up a computational algorithm with the objective of automatically detecting, in the form of a study, dysplastic lesions. Algorithms of this nature, in the cases where validation by histological analysis is possible, may contribute even further to the diagnosis of epilepsies.

Taking into account the panorama of refractory epilepsies and the perspectives that arise with texture analysis, this study was aimed at verifying whether there are statistically significant differences of texture between brain structures of patients and of healthy subjects when we evaluate the limbic association cortex, the prefrontal cortex and the hippocampi.

METHOD

The group of patients selected by the criteria of the Neuroimaging Laboratory of State University of Campinas (UNICAMP) was composed of subjects with distinct clinical symptoms. This selection took into consideration the fact that, despite the profile of the symptoms and of their clinical evolution, the simple visual analysis of the MRI did not detect alterations at the time of the study, in which the patients were already considered refractory to the AEDs. The choice of the patients was based on recent models in which it is proposed that any region of the brain can originate the epileptic crisis and recruit other areas through interaction of the limbic, cortical and subcortical structures¹⁰.

This retrospective study involved the selection of MRI scans of 20 patients with refractory epilepsy, aged between

21 and 41 years (average=32±8 years, 66% men), besides another 20 healthy subjects as a control group, aged between 26 and 48 years (average=29±4 years, 55% men) without a history of neurological diseases. The age of crisis onset for the studied group ranged between 2 and 28 years (average=12.1±6.9 years). It is a unpaired study. Both the images of the patients and of the control subjects were normal upon visual and volumetric analysis by the radiologist. All the images were acquired in the Achieva3T[®] scanner (Philips, Netherlands), and the project was approved by the Committee of Ethics in Research of Medical School of Jundiai.

Table 1 presents the types of crises of each one of the patients studied and the age at onset of the crises.

The textures of the hippocampi and of cortical portions (prefrontal cortex and limbic association cortex) were evaluated in all the patients. Coronal T2-weighted images (TR=2000 ms, TE=30 ms, section thickness=3 mm) were used in the hippocampal analyses. T2 images provide a more precise anatomical location of the temporal lobe structures, enabling the detection of hippocampal atrophies in the TLEs. Sagittal T1 images (TR=7.1 ms, TE=3.2 ms, section thickness=1 mm) were used for the limbic association cortex and prefrontal cortex study, since they present better contrast for the detection of cortical malformations.

The texture analyses were executed in the MaZda software (Lodz, Poland). This software was used to define, for each subject, ROIs in the left and right hippocampi, in the prefrontal cortex and in the limbic association cortex, as presented in Figure 2.

Table 1. Types of symptoms presented by the patients studied and age at onset of crisis.

Patient	Symptoms	Age at onset of crisis
1	Tonic-clonic crisis	17
2	Absence	10
3	Complex partial crisis	6
4	Tonic-clonic crisis	12
5	Tonic crisis, absence	28
6	Nocturnal epilepsy	9
7	Absence, tonic-clonic crisis	11
8	Oral automatisms, tonic-clonic crisis	19
9	Oral automatisms, absence	4
10	Tonic crises	13
11	Nocturnal epilepsy, myoclonia	6
12	Myoclonia, tonic-clonic crisis	13
13	Tonic crises	2
14	Complex partial crisis	12
15	Oral automatisms, myoclonia	7
16	Absence	21
17	Tonic crises	24
18	Complex partial crisis	8
19	Absence	15
20	Tonic crisis, absence	5

A slice of the T1 image was selected for each subject for evaluation of the cortical areas, with a slice of the T2 image for evaluation of the hippocampi, as these are the ones that provided the best visual representation of the areas studied. Small ROIs (minimum of 15 x 15 pixels) were used in the evaluation of the cortical tissues, in order to reduce the influence of brain sulci and gyri in the texture analysis.

The statistical parameters of texture were calculated from the grey level co-occurrence matrix^{17,18}. This matrix enables the obtainment of statistical information from the distribution of pixel pairs along the image. The matrix was used as a basis to calculate the following statistical parameters: angular second moment (ASM), contrast (CO), correlation (COR), inverse difference moment (IDM), entropy (E), sum entropy (SE), difference entropy (DE), sum variance (SV), difference variance (DV), sum average (SA) and sum of squares (SS). These parameters were calculated for five distances between pixels (d=1, 2, 3, 4 and 5 pixels) and, taking, for each one of the parameters, the mean of the values obtained for four image sweep directions (0°, 45°, 90°, 135°). The statistical parameters cited provide different information about the same evaluated ROI. For example, ASM assesses uniformity; the entropy measurements assess disorganization among the image pixels; contrast can detect the presence of edges and rough spots in the image. The statistical significance of the differences found between the group of patients and the control group was verified with the t-Student test. The significance level used was 5%.

RESULTS

Table 2 presents the means and standard deviations of the values of the texture parameters calculated for the left hippocampus for each studied group in the MRI, together with the p-values obtained by Student's t-test. Only parameters that presented significant differences among the groups are shown.

Table 3 presents the results obtained in the MRI analyses of the right hippocampus of patients and control subjects, using a method similar to that adopted in the left hippocampus. As for Table 2, only parameters that presented significant differences among the groups are shown.

There is not significant differences among the groups for the cortical areas studied (pre-frontal cortex and limbic association cortex).

DISCUSSION

According to Table 2, the parameters obtained by this study that resulted in statistically significant differences between the group of patients and the control group for left

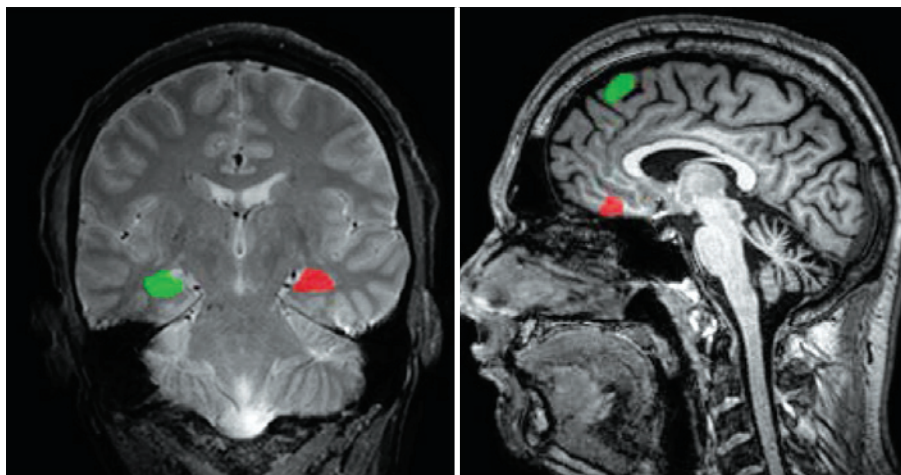


Figure 2. Left: T2 coronal MRI image presenting the regions of interest for analysis of the hippocampi. Right: T1 sagittal MRI image presenting the ROIs for the analysis of cortical portions.

Table 2. Results obtained in the analysis of the left hippocampus in the MRI. The table shows the texture parameters that presented statistically significant differences between the group of patients and the control group.

Distance	Parameter	Patients Mean±SD	Controls Mean±SD	p
d=5	COR	0.12±0.14	0.22±0.13	0.04
d=5	SA	47.14±13.68	38.56±11.73	0.04

COR: correlation;SA: sum average; SD: standard deviation.

Table 3. Results obtained in the analysis of the right hippocampus in the MRI. The table shows the texture parameters that presented statistically significant differences between the group of patients and the control group.

Distance	Parameter	Patients Mean±SD	Controls Mean±SD	p
d=3	COR	0.35±0.14	0.22±0.13	<0.01
d=3	DV	8.05±6.13	13.76±11.38	0.04
d=4	COR	0.21±0.15	0.08±0.13	<0.01
d=5	COR	0.14±0.14	0.03±0.12	0.01

COR: correlation; DV: difference variance; SD: standard deviation.

hippocampus were: COR and SA for distance of five pixels. Table 3 shows that COR and DV presented statistically significant differences between the group of patients and the control group for the right hippocampus. COR presented statistically significant differences for distances of three, four and five pixels and DV presented significant differences for distance of three pixels. Given that COR is related to the linear dependence between neighbor pixels, we observed that for the patients, for both hippocampi, there is a tendency of difference in the pixels linear dependence when compared to controls.

For the left hippocampus, the SA also present statistically significant differences between the group of patients and the control group. This suggest that the mean of sum of gray levels tends to distribute in different forms in patients and controls, pointed to texture differences between these groups. In

the right hippocampus, the DV present statistically significant differences between the group of patients and the control group. Given that this parameter is related to dispersion of distribution of differences between the gray levels of the imaging, the findings suggest that there is a tendency to existence of different distributions of gray levels in patients when compared to controls, pointed also to differences of hippocampi texture of these groups. To verify that the texture alterations of the images are related with modifications of hippocampal tissue it would be necessary to compare the data with the histopathological analyses of the areas in question.

The findings obtained seem to be in agreement with observations found in the literature, that the main neurons of the hippocampus are vulnerable to a varied range of insults, such as hypoxia, ischemia, trauma and hyperglycemia^{10,24}.

Since the necroscopic studies of Sommer²⁴ and Bratz²⁵, it has been observed that in patients with epilepsy, the hippocampus presents neuronal loss accompanied by fibrosis, gliosis, volume contraction and tissue thickening⁷. As mentioned, the analyses of Yu et al. detected alterations of texture in the hippocampus contralateral to that presenting atrophy in patients affected by TLE²¹. In the study by Bonilha et al.²⁰, the authors observed alterations of texture in the sclerotic and contralateral hippocampi of patients with epilepsy when compared with the healthy subjects. Indeed, in this study, we observe bilateral alterations of texture in the hippocampi of the patients when compared with the control group. It is interesting to note that this occurred for the group as a whole, regardless of the type of epileptic crisis presented. This might be related to structural modifications that may result from the epileptic crises – which would explain the finding, in spite of the heterogeneity of the group of patients. We can therefore assume the possibility that hippocampal alterations result, in turn, in the refractoriness of epileptic crises.

According to the hypothesis of Bernasconi²², FCDs appear in MRI images as a thickening of the cortex combined with a hypotensive signal in the T1 images when compared with the normal cortical tissues, as they can be made up of

dysmorphic neurons (giant, dysplastic) and balloon cells. However, there is also the type of dysplasia in which there is loss of the laminar pattern of the cortex without the presence of abnormal cells⁹, which may hinder the detection of these lesions in the visual analysis of MRI images. However, for to the cortical, limbic and prefrontal portions evaluated, we not found statistically significant differences between the group of patients and the control group.

Recent models, as shown in Figure 1, indicate the involvement of cortical areas in the propagation of seizures in refractory epilepsy. However, this study found no changes in the texture of the images to corroborate with these models.

Concluding, in this work we found significant differences between the group of epilepsy patients and that of control subjects in the parameters COR and SA, for the left hippocampus, and COR and DV, for the right hippocampus.

This study opens up a perspective on the use of this technique beyond surveys. With subsequent studies, covering a larger number of subjects (patients and control subjects) and the use of histological techniques, if the findings are corroborated, we will be able to have yet another useful tool to assist in the evaluation of MRI images of patients with refractory epilepsy.

References

- Berg AT, Berkovic SF, Brodie JM, et al. Revised terminology and concepts for organization of seizures and epilepsies: report of the ILAE Commission on Classification and Terminology, 2005-2009. *Epilepsia* 2010;51:676-685.
- Palmini A, Calcagnotto M.E, Cendes F. Epilepsias refratárias: diagnóstico síndrômico, topográfico e etiológico. In: Guerreiro CAM, Guerreiro MM, Cendes F, Lopes-Cendes I (Eds). *Epilepsia*. São Paulo: Lemos, 2000:369-378.
- Fernandes PT, Noronha ALA, Sander J, et al. National epilepsy movement in Brazil. *Arq Neuropsiquiatr* 2007;65:55-57.
- Cendes F. Progressive hippocampal and extrahippocampal atrophy in drug resistant epilepsy. *Curr Opin Neurol* 2005;18:173-177.
- Kobayashi E, Cendes F, D'Agostino MD, et al. Hippocampal atrophy and T2-weighted signal changes in familial mesial temporal lobe epilepsy. *Neurology* 2003;60:405-410.
- Barkovitch J, Kuzniecky R, Dobyns W, Jackson G, Becker L, Evrard P. A classification scheme for malformations of cortical development. *Neuropediatrics* 1996;27:59-63.
- Cendes F, Cook MJ, Watson C, et al. Frequency and characteristics of dual pathology in patients with lesional epilepsy. *Neurology* 1995;45:2058-2064.
- Urbach H, Sassen R, Wellmer J. Epilepsy syndromes. In: Urbach H (Ed). *MRI in epilepsy*. *Med Radiol* 2013;15-19.
- O'Muircheartaigh J, Richardson MP. Epilepsy and the frontal lobes. *Cortex* 2010;48:144-155.
- Thom M, Bertram M. Temporal lobe epilepsy. *Handbook of Clinical Neurology* 2010;107:284-299, Elsevier.
- Beleza P, Pinho J. Frontal lobe epilepsy. *J Clin Neurosci* 2011;18:593-600.
- Gavaret M, McGonigal A, Badier JM, et al. Physiology of frontal lobe seizures: pre-ictal, ictal and inter-ictal relationships. *Suppl Clin Neurophysiol* 2004;57:400-407.
- Lerski RA, Straughan K, Schad LR, et al. Image texture analysis: an approach to tissue characterization. *MRI* 1993;11:873-887.
- Freeborough PA, Fox NC. MR texture analysis applied to the diagnosis and tracking of Alzheimer disease. *IEEE Transact Med Imag* 1998;17:475-479.
- Mathias JM, Tofts PS, Losseff NA. Texture analysis of spinal cord pathology in multiple sclerosis. *MRI* 1999;42:929-935.
- Schad LR, Blüml S, Zuna I. MR tissue characterization of intracranial tumors by means of texture analysis. *MRI* 1993;11:889-896.
- Haralick RM, Shanmugam K. Textural features for images classification. *IEEE Transact Syst Man Cybernetics* 1979;3:610-621.
- Haralick RM. Statistical and structural approaches to texture. *Proc IEEE* 1979;67:786-804.
- Castellano G, Bonilha L, Li LM, Cendes F. Texture analysis of medical images. *Clin Radiol* 2004;1061-1069.
- Bonilha L, Kobayashi E, Castellano G, et al. Texture analysis of hippocampal sclerosis. *Epilepsia* 2003;12:1546-1550.
- Yu O, Roch C, Namer IJ, et al. Existence of contralateral abnormalities revealed by texture analysis in unilateral intractable hippocampal epilepsy. *MRI* 2001;19:1305-1310.
- Bernasconi A. Advanced MRI analysis methods for detection of focal cortical dysplasia. *Epilept Disord* 2003;5:81-84.
- Antel SB, Collins DL, Bernasconi N, et al. Automated detection of focal cortical dysplasia lesions using computational models of their MRI characteristics and texture analysis. *Neuroimage* 2003;19:1748-1759.
- Sommer W. Erkrankung des Ammonshornes als aetiologisches Moment der Epilepsie. *Arch Psychiatr Nervenkr* 1880;10:631-675.
- Bratz E. Ammonshorn befunde bei epileptikern. *Arch Psychiatr Nervenkr* 1889;32:820-835.