

## VON HIPPEL-LINDAU'S DISEASE

### REPORT OF THREE CASES AND REVIEW OF THE LITERATURE

LUIZ F. BLEGGI-TORRES\*\*\*, LÚCIA DE NORANHA\*, J. FILLUS NETO\*\*,  
JOSÉ E. QUEIROZ TELLES\*\*, LUIZ E. MADALOZZO\*\*\*

---

**SUMMARY** - The authors present the autopsy findings of two related patients and the biopsy findings of a third member of the family. The oldest member was 34 years old at death and on postmortem examination he had haemangioblastomas in the retina, cerebellum, medulla and spinal cord. Other findings were renal cell carcinoma, phaeochromocytoma, cysts of kidney and pancreas, hydromyelia and atypical meningiomas. His brother died when 30 years old. The autopsy revealed haemangioblastomas of cerebellum, renal cell carcinoma and a clear cell cystadenoma of epididymus. The third patient was the daughter of the first and presented with headache and dizziness. CT-scan showed a cerebellar haemangioblastoma. Epidemiological considerations on the commonest visceral and CNS lesions and a review of current diagnostic criteria are discussed.

**KEY WORDS:** von Hippel-Lindau's disease, angiomatosis, phakomatosis.

#### **Doença de von Hippel-Lindau: relato de três casos e revisão da literatura**

**RESUMO** - Os autores relatam os achados de autópsia de dois pacientes de uma mesma família e o diagnóstico por biópsia de hemangioblastoma de um terceiro membro desta mesma família. O primeiro paciente tinha 34 anos por ocasião do óbito e os achados de necrópsia mostraram hemangioblastoma de retina, cerebelo, bulbo e medula espinhal, além de carcinoma renal, feocromocitoma, lesões císticas de rim e pâncreas, hidromiélia e meningiomas atípicos. Seu irmão morreu com 30 anos de idade e a autópsia revelou hemangioblastomas de cerebelo, carcinoma renal e cistoadenoma de células claras de epididimo. A terceira paciente era filha do primeiro paciente e apresentou cefaléia e ataxia. A tomografia computadorizada mostrou lesão cerebelar cística e a biópsia confirmou tratar-se de hemangioblastoma. São feitas considerações epidemiológicas sobre lesões viscerais e do sistema nervoso mais comumente encontradas, além de discutir critérios diagnósticos.

**PALAVRAS-CHAVE:** doença de von Hippel-Lindau, angiomatose, facomatose.

---

Von-Hippel-Lindau's disease (vHL) is a rare autosomal dominant disorder with incomplete penetrance and variable expression affecting 1:100000 inhabitants initially described by Turner in 1887<sup>17,19</sup>. It was characterized as a clinical entity by Lindau (1926) who described the occurrence of central nervous system and visceral abnormalities including haemangioblastomas of the cerebellum, retina and spinal cord, pancreatic and renal cell carcinoma and cysts, and phaeochromocytoma<sup>5</sup>.

In the present study we present the post-mortem findings of two familial cases and a further case of the same family operated by cerebellar haemangioblastoma; so far no similar reports have been documented in the Brazilian literature.

---

Section of Neuropathology and Electron Microscopy\*, Departments of Pathology\*\* and Neurosurgery\*\*\*, Hospital de Clínicas. Federal University of Paraná, Curitiba, Brazil. Aceite: 8-junho-1995.

Luiz F. Bleggi Torres, MD, PhD - Section of Neuropathology and Electron Microscopy, Hospital de Clínicas, Rua General Carneiro 181 - 80060-900 Curitiba PR - Brazil.

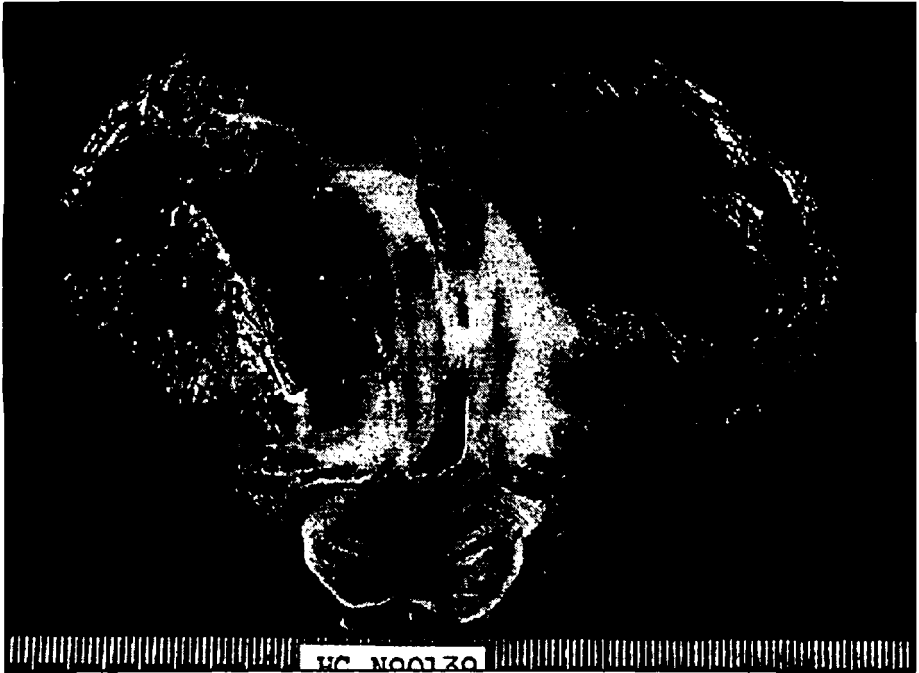

Fig 1A. Section of cerebellum of Case 1 showing old cystic lesion due to previous surgery in the right hemisphere (R) and a cystic haemangioblastoma with mural nodule in the left hemisphere (L).

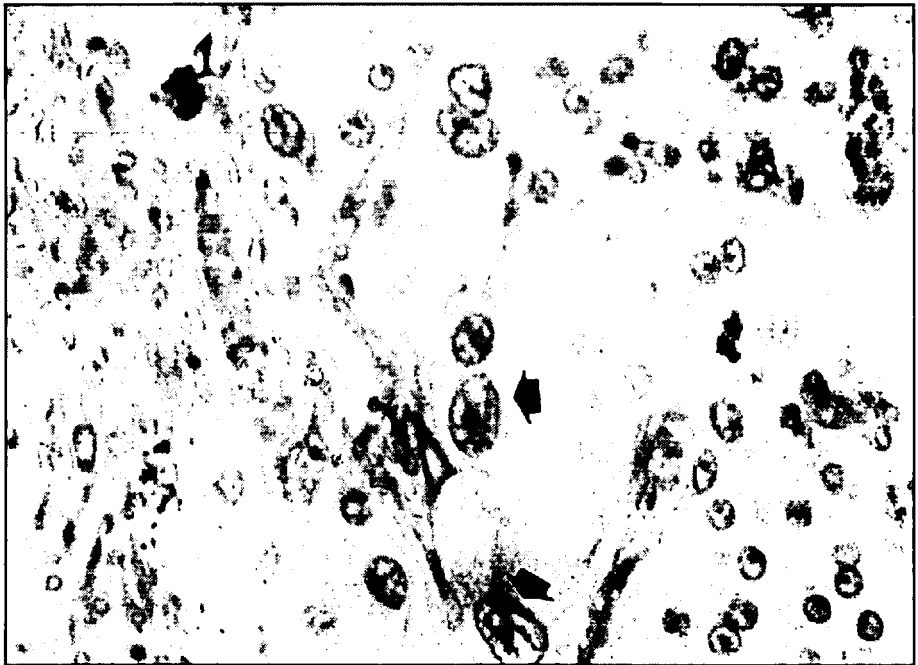


Fig 1B. Histological section of meningioma showing atypical cells (arrow) and a somewhat sheet-like arrangement. HE x 400.

## CASE REPORTS


**Patient 1-** a 34-year old male patient presented with dizziness, nausea, motor incoordination and ataxic gait. Physical examination showed absence of ocular reflexes and angioma of the retina in the left eye. The patient had undergone a posterior fossa craniotomy 15 years ago in another hospital and no report of the biopsied material was available. A recent CT-scan showed a solid-cystic lesion of the cerebellar vermis, hydrocephalus, cystic lesions of the pancreas and right kidney and a tumour of the left kidney. He received a ventricular-peritoneal CSF shunt but showed mental depression and died two weeks after admission of lung infection. Post-mortem examination showed fibrous scarring tissue affecting the right cerebellar hemisphere compatible with the previous craniotomy and capillary haemangioblastomas affecting left cerebellar hemisphere (Fig 1A), medulla and cervical spinal cord with areas of hemorrhage. There was also dilatation of the spinal canal at cervical level. Further CNS findings included two nodular tumours attached to the dura in the right frontal area which on histological examination were considered as atypical meningioma. (Fig 1B). Visceral abnormalities included bronchopneumonia, multiple renal and pancreatic cysts, bilateral renal cell carcinomas and pheochromocytoma of left adrenal.

**Patient 2-** a 30 year old male, brother of Patient 1, presented with a month's history of headache, nausea, difficulty in walking, photophobia and dysarthria. Cerebral angiography showed three nodules in the cerebellum compatible with vascular tumours (Fig 2). Fundoscopy and abdominal ultrasound scan were unremarkable. He received a ventricular-peritoneal CSF shunt and died ten days after admission of pulmonary thrombo-embolism. Post-mortem examination confirmed the presence of three haemangioblastomas in the cerebellum, multiple pancreatic cysts, absence of right kidney, a left solid-cystic renal cell carcinoma with metastases to lung and subcutaneous tissue. There was a clear cell epididymal tumour and pheochromocytoma of left adrenal gland.

**Patient 3-** a 17 year old girl, daughter of Patient 1, presented with dizziness, nausea, vomiting and headache. Neurological examination showed nystagmus. Fundoscopy with angioma of right retina. CT-scan showed a posterior fossa tumour. The patient underwent craniotomy and biopsy material showed a capillary haemangioblastoma of the cerebellum (Fig 3).



Fig 2. Cerebral angiography of Case 2 showing haemangioblastomas with tangles of small vessels (arrows).



*Fig 3. Histological section of haemangioblastoma of Case 3 showing finely vacuolated stromal cells (arrow head) and numerous thin-walled blood vessels (V). HE x 400.*

## COMMENTS

The symptoms of vHL disease appear between 15 and 45 years, what is confirmed in our cases, and male and female patients are affected in similar proportions. The age of the patients by the time of diagnosis is decreasing due to modern tomographic, magnetic resonance and ultrasound techniques<sup>17,18,20</sup>. The lesions that commonly cause clinical manifestations are haemangioblastomas of the cerebellum (responsible for up to 40% of the initial manifestations) and retina. In the present cases, all the haemangioblastomas were in the cerebellum and two of the patients had a retinal tumor. The symptoms at clinical diagnosis were headache, dizziness, nausea, vomiting, motor incoordination, ataxic gait, photophobia and dysarthria. The mortality of vHL disease is due mainly to cerebellar tumours and renal cell carcinomas with age of death ranging from the fourth to fifth decade<sup>10</sup>.

The retinal haemangioblastoma is one of the commonest manifestations in vHL disease appearing in 25 up to 78% of all cases. The age of the patients by the time of clinical diagnosis of haemangioblastomas of retina range from 10 to 40 years and is uncommon in the first decade.

Around 35% of all haemangioblastomas of retina are part of vHL disease while the rest (65%) are sporadic. Approximately one third of the vHL patients have multiple haemangioblastomas of the retina and 50% of all patients have bilateral lesions<sup>10,15,18,27</sup>. The lesions tend to affect the periphery of the retina and appear as tangles of small capillary vessels sometimes dilated<sup>19</sup>, and lined by flat endothelial cells, separated by clear stromal cells packed with small vacuoles rich in lipids<sup>21</sup>.

The haemangioblastoma of the nervous system is a rare intracranial neoplasm representing around 1% of all CNS tumours and affects predominantly the cerebellum in 35 to 87% of vHL patients. Around 30% of all haemangioblastomas of the cerebellum belong to the vHL disease and

in around 20% of patients they are multiple, what happened in Patient 2, who had three tumors in the cerebellum. The age of diagnosis of the haemangioblastoma of cerebellum ranges from 20 to 60 years of age with a peak around 30 years<sup>10,15,23,24</sup>. Around 10-20% of these patients have erythrocytosis which disappears after excision of the tumour. Erythropoietin has been found in the fluid filling the cystic component of the tumour, if administered to mice it stimulates an increase in number of erythrocytes. These tumours are benign and local recurrence after excision is rare<sup>7,13,24</sup>.

There are speculations about the origin of stromal cells of haemangioblastomas. They might be of endothelial microglial, macrophagic, pial or neuroendocrine origin. The glial origin was suggested by the presence of intermediate filaments in the cytoplasm of stromal cells identified under electron microscopical examination but immunohistochemistry techniques in GFAP fail to confirm these hypothesis. The stromal cells fail to show macrophagic differentiation under electron microscopy such as lysosomes and are negative to immunohistochemistry to lysozyme and fibrinogen. The pial origin might be excluded by the lack of interdigitations characteristic of meningothelial cells. Recent observations by electron microscopy showed secretory granules in stromal cells suggesting a neuroendocrine origin. So far the origin of the stromal cells remain a mystery<sup>11,13,21</sup>.

Syringomyelia is found around 43% of cases of vHL disease and generally associated with cerebellum and spinal cord haemangioblastomas. One of our cases show hydromyelia probably due to obstruction of the central canal by the tumour<sup>6</sup>.

The clear cell carcinoma of the kidney affects 28 to 53% of patients with vHL disease and in 75% of cases is bilateral, in contrast to 1.8% of bilateral carcinoma in non-vHL patients. Two of our patients had this kind of tumour: in one of them it was bilateral and in other there were spread metastases to lung and subcutaneous tissue. The age of diagnosis of renal cell carcinoma in vHL disease is around 35 to 41 years contrasting to a peak of 55-60 years for the sporadic cases<sup>10,12,16</sup>. Recent molecular biology studies showed the presence of chromosomal abnormalities in cells of haemangioblastomas, pheochromocytomas and renal cell carcinoma in vHL. It has been proposed that a translocation of the short arm of chromosome 3 to the long arm of chromosome 8 would allow loss of a suppressor gene and the possibility of a recessive oncogene to be switched on contributing to the development of renal cell carcinoma in vHL<sup>3,4,9,25,26</sup>.

The incidence of pheochromocytoma varies according to the phenotypic expression in the families affected by vHL disease, what seems to be the case in the family we present. The age of diagnosis ranges from 11 to 58 years with a peak around 20 years<sup>10,19</sup>.

There are more than 26 different types of minor lesions described in vHL disease including astrocytomas, meningiomas, ependymomas, choroid plexus papillomas, neuroblastomas, cysts of liver, lung, pancreas, kidney and spleen, pituitary adenomas and angiomas of several different organs and aggressive papillary lesions of middle ear<sup>1,8,18,19,22</sup>.

Table 1. Criteria for diagnosis of vHL disease according to Lamiell et al., 1989.

Nº of lesions	Family history	Diagnosis
single	negative	sporadic
single	positive	vHL-fruste form
multiple	positive	vHL-full form
multiple	negative	vHL-new mutation

The clinical criteria for the diagnosis of vHL disease have been a matter of discussion for many years. One of the initial concepts was that vHL was a syndrome with haemangioblastoma of the nervous system associated with at least one intraabdominal lesion and could be sporadic or familial<sup>14</sup>. More recently Lamiell et al.<sup>18</sup> stated that for the diagnosis of vHL disease at least one of the following lesions must be present together with positive family history: 1) haemangioblastomas of the CNS; 2) haemangioblastomas of retina; 3) cysts and/or adenocarcinoma of kidneys; 4) cysts and/or adenocarcinoma of pancreas; 5) pheochromocytoma; 6) clear cell tumour of the epididymus (Table 1). Other clinical parameters used for the screening of vHL patients include total haemoglobin higher than 18g/dL and raised blood pressure. In suspected cases cranial NMR and CTscan of kidney are recommended<sup>2,10,17,19</sup>.

## REFERENCES

1. Böker DK, Wassmann H, Solymosi L. Multiple spinal hemangioblastomas in a case of Lindau's disease. *Surg Neurol* 1984, 22:439-443.
2. Choyke PL, Filling-Katz MR, Shawker TH et al. Von Hippel-Lindau disease: radiologic screening for visceral manifestations. *Radiology* 1990, 174: 815-820.
3. Choyke PL, Glenn GM, Walther MCM et al. The natural history of renal lesions in von Hippel-Lindau disease: a serial CT study in 28 patients. *Am J Roentgenol* 1992, 159:1229-1234.
4. Connor JM. Von Hippel-Lindau disease. *Q J Med* 1990, 183:1099-1100.
5. de Souza Andrade J, Bambirra EA, Bicalho OJ et al. Bilateral papillary cystadenoma of the epididymis as a component of von Hippel-Lindau's syndrome: report of a case presenting as infertility. *J Urol* 1985, 133:288-289.
6. Enomoto H, Shibata T, Ito A et al. Multiple hemangioblastoma accompanied by syringomyelia in the cerebellum and spinal cord. *Surg Neurol* 1984, 22:197-203.
7. Filling-Katz MR, Choyke PL, Oldfield E et al. Central nervous system involvement in von Hippel-Lindau disease. *Neurology* 1991, 41:41-46.
8. Gaffey MJ, Mills SE, Boyd JC. Aggressive papillary tumor of middle ear/temporal bone and adnexal papillary cystadenoma: manifestations of von Hippel-Lindau disease. *An J Surg Pathol* 1994, 18:1254-1260.
9. Goodman MD, Goodman BK, Lubin MB et al. Cytogenetic characterization of renal cell carcinoma in von Hippel-Lindau syndrome. *Cancer* 1990, 65:1150-1154.
10. Green JS, Bowmer MI, Johnson GJ. Von Hippel-Lindau disease in a Newfoundland kindred. *Can Med Assoc J* 1986, 134:133-138.
11. Horton JC, Harsh GR, Fisher JM et al. Von Hippel-Lindau disease and erythrocytosis: radioimmunoassay of erythropoietin in cyst fluid from a brainstem hemangioblastoma. *Neurology* 1991, 41: 753-754.
12. Horton WA, Wong V, Eldridge R. Von Hippel-Lindau disease: clinical and pathological manifestations in nine families with 50 affected members. *Arch Intern Med* 1976, 136:769-777.
13. Ismail SM, Jasani D, Cole G. Histogenesis of haemangioblastomas: an immunocytochemical and ultrastructural study in a case of von Hippel-Lindau syndrome. *J Clin Pathol* 1985, 38:417-421.
14. Jefferys R. Clinical and surgical aspects of posterior fossa haemangioblastomas. *J Neurol Neurosurg Psychiatry* 1975, 38:105-111.
15. Jennings AM, Smith C, Cole DR et al. Von Hippel-Lindau disease in a large British family: clinico pathological features and recommendations for screening follow-up. *Q J Med* 1988, 251:233-249.
16. Keeler LL, Klauber GT. Von Hippel-Lindau disease and renal cell carcinoma in a 16 year old boy. *J Urol* 1992, 147:1588-1591
17. Kounis MG, Karapanou E, Dimopoulos P et al. The von Hippel-Lindau syndrome: report of a case and review of the literature. *Br J Clin Pract* 1989, 43:37-41.
18. Lamiell JM, Salazar FG, Hsia YE. Von Hippel-Lindau disease affecting 43 members of a single kindred. *Medicine* 1989, 68:1-29.
19. Maher ER, Yates JRW, Harries R et al. Clinical features and natural history of von Hippel-Lindau disease. *Q J Med* 1990, 283:1151-1163.
20. Melmon KL, Rosen SW. Lindau's disease. *Am J Med* 1964, 36:595-617.
21. Mottow-Lippa L, Tso MOM, Peyman GA et al. Von Hippel angiomas: a light, electron microscopic and immunoperoxidase characterization. *Ophthalmology* 1983, 90:848-855.
22. Neumann HPH, Dinkel E, Brambs H et al. Pancreatic lesions in the von Hippel-Lindau syndrome. *Gastroenterology* 1991, 101:465-471.
23. Neumann HPH, Eggert HR, Scheremet R et al. Central nervous system lesions in von Hippel-Lindau syndrome. *J Neurol Neurosurg Psychiatry* 1992, 55:898-901.

24. Neumann HPH, Eggeert HR, Weigel K et al. Hemangioblastomas of the central nervous system. *J Neurosurg* 1989, 70:24-29.
25. Neumann HPH, Wiestler OD. Clustering of features of von Hippel-Lindau syndrome: evidence for a complex genetic locus. *Lancet* 1991, 337:1052-1054.
26. Tory K, Brauch H, Linchan M et al. Specific genetic change in tumours associated with von Hippel-Lindau disease. *J Natl Cancer Inst* 1989, 81:1097-1101.
27. Wing GL, Weiter JJ, Kelly PJ et al. Von Hippel-Lindau disease: angiomatosis of the retina and central nervous system. *Ophthalmology* 1981, 88:1311-1314.