

Localized Pigmented Villonodular Synovitis of the knee: an arthroscopic treatment

Arnaldo José Hernandez¹, Gilberto Luiz Camanho², Marcos Henrique Laraya³, Edimar Fávaro⁴, Maurício Martinelli Filho⁵

SUMMARY

The authors present a series of seven case reports of Localized Pigmented Villonodular Synovitis (LPVNS) treated by arthroscopy resection between June of 1994 and October of 2001.

At the baseline evaluation, symptoms ranged from diffuse pain to localized swelling of the knee, with or without mechanical blockage of the joint. Magnetic Resonance helped in localizing the lesion and in the follow up evaluation. Diagnosis was confirmed through anatomicopathological examination.

By the end point evaluation, none of the patients presented recurrence of the pre-operative symptoms referred before. Magnetic resonance imaging also showed absence of symptoms.

Despite of the small number of patients, typical of this affection, the authors believe that arthroscopic excision of the LPVNS is an effective method, with low morbidity, providing remission of the symptoms and a low recurrence potential.

Keywords: Knee; Pigmented villonodular synovitis; Arthroscopy.

INTRODUCTION

Pigmented Villonodular Synovitis (PVNS) is a rare proliferative, benign lesion, of unknown origin, typically monoarticular, especially affecting the knee during the third and fourth decades of life^(1,2), being uncommon in other joints, such as the ankle⁽³⁾. Its yearly incidence, according to Myers⁽⁴⁾ is 1.8/1000000 patients. Histological features of such lesions have first been unified by Jaffe et al.⁽⁵⁾ in 1941, but it is believed that a nodular lesion involving the synovial membrane of the flexor tendon, described by Chassaignac in 1852, was a PVNS⁽⁶⁾. In 1976, Granowitz e Mankin⁽⁷⁾ proposed a clinical classification of the PVNS according to the joint synovial membrane involvement, characterizing it as diffuse form and localized form. Both kinds can be found in the knee, with the diffuse form being the most common one.

The localized form is characterized by a nodular formation, which can be sessile or, more frequently, pedunculated. It is localized especially at the meniscus-capsular union, intercondylar region, tibial eminence, lateral recess and, occasionally, at the HOFFA fat^(1,5,8,9).

In this study, we present four case reports (four knees) with Localized Pigmented Villonodular Synovitis (LPVNS) treated with ar-

throscopic resection, intending to call the attention to its diagnosis and to check the results achieved with the treatment of this rare lesion.

MATERIALS AND METHODS

Seven patients (seven knees) presenting LPVNS have been submitted to surgery between June 1994 and October 2001, through arthroscopic section of the lesion. Ages ranged from 5 to 40 years old, with an average of 26.1 years. Four patients were males and three were females. Average follow-up time was 36.1 months (12 – 74 months). On Table 1, patients with their respective order numbers, ages, genders, follow-up periods and lesion sites are listed.

Symptoms ranged from diffuse pain, with or without significant swelling of the joint, to a localized volume increase, with or without mechanical blockage of the range of motion. Radiographs of all individuals showed no changes. Magnetic resonance imaging helped in localizing lesions (Figures 1A and 1B), which has also been used as a postoperative control. Surgical technique involved the use of marginal resection of the lesion through arthroscopy in all cases, with diagnosis confirmed by anatomicopathological examination postoperatively.

Study conducted at the Orthopaedics and Traumatology Department and Institute, Hospital das Clínicas, Medical School of the University of São Paulo, Brazil

Correspondences to: Rua Barata Ribeiro 414, Cj. 53, São Paulo-SP, BRASIL, CEP 01308-000.

- 1- Full Professor at the Medical School, University of São Paulo. Head of the Knee Surgery Group.
- 2- Full Professor at the Medical School, University of São Paulo. Head of the Discipline of Specialized Orthopaedics.
- 3- Master in Orthopaedics and Traumatology at the Federal University of São Paulo. Ex-fellow of the Knee Surgery Group.
- 4- Ex-fellow of the Knee Surgery Group
- 5- Ex-Resident

Received in: 08/11/04; approved in: 11/22/04

The outcomes have been evaluated according to clinical examination and magnetic resonance imaging.

RESULTS

By the clinical examination, no patient presented recurrence of signs and symptoms reported before surgery until the end-point follow-up visit. Magnetic resonance imaging (Figures 2 A and 2B) presented no evidences of lesion recurrence in all subjects.

DISCUSSION

In 1941, Jaffe⁽⁵⁾ was the first to unify the multiple manifestation of this disease and to describe its histological characteristics, proposing the name PVNS; however, many other names for such condition still exist in literature, such as, for example, giant-cell tumor of the tendon sheath and synovial xanthoma⁽¹⁰⁾.

Differently from literature reports, one of our cases was at the first decade of life. However, due to the small sample, conclusions towards this matter are not possible.

The etiopathogenesis of the PVNS remains unclear. Some authors suggest that the development of this disease can be a result of a lipid metabolism change, inflammation, or a benign neoplastic process⁽⁷⁾. The possibility of trauma-induced PVNS has also been reported^(4,10,11).

Clinical diagnosis of the PVNS is difficult, since symptoms are non-specific, and can include: diffuse pain, edema, palpable tumor, motion limitation, and knee joint restraint^(1,8). Joint swelling, whenever present, is usually hemorrhagic with a dark brown color⁽⁹⁾. We think that it's worthy to mention the study by Van Meter⁽¹²⁾, which emphasizes the importance of establishing a differential diagnosis for possible causes of knee mechanical blockage. The author reports a case where the patient presented with symptoms of joint blockage, clinically simulating a "bucket handle" lesion on the lateral meniscus. However, at the moment of arthroscopy, no meniscal lesions have been evidenced, with

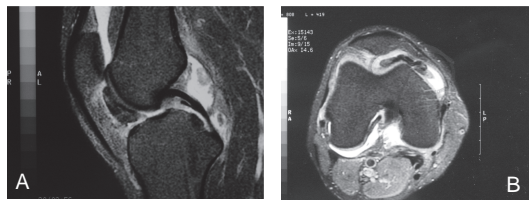


Figure 1 - Preoperative magnetic resonance imaging of the knee: axial section (A) and longitudinal section (B), showing the lesion.

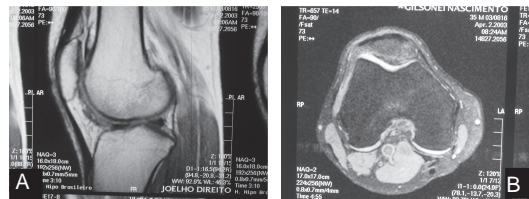


Figure 2 - Postoperative magnetic resonance imaging of the knee: axial section (A) and longitudinal section (B).

only one localized tumor found behind the posterior cornu of the lateral meniscus, with a free fragment located at the posterior lateral recess. After tumor removal, the patient didn't complain of blockage anymore, and the anatomicopathological diagnosis was PVNS. In our study, four of the seven patients presented with clinical joint blockage, similar to that described by Van Meter⁽¹²⁾. Magnetic resonance imaging was of great value for ruling out a potential meniscal lesion and for verifying the presence of a localized mass at the medial meniscus-capsular union. After resection, as in Van Meter's report⁽¹²⁾, patients no more complained of blockage.

The radiographic study on LPVNS usually does not present changes⁽¹⁰⁾. However, with the advent of magnetic resonance imaging (MRI), the diagnosis has been increasingly accurate. LPVNS presents with a heterogeneous mass at the soft parts, with low sign at T1 and T2 corresponding to a hemosiderin deposit. Despite these findings, MRI cannot be considered as a specific method, being part of a differential diagnosis, the synovial chondromatosis, the synovial hemangioma, the fibroxanthoma, rheumatoid arthritis, and even the synovial sarcoma^(8,13,14).

Some studies report that LPVNS has a lower recurrence rate and a more favorable response to surgical treatment when compared to the diffuse form of PVNS despite its histological similarity^(6,8). It can be found in literature that the recurrence of the diffuse form can range from 25% to 50%, while the localized form presents a recurrence rate below 5%^(4,10,11). In this study, the authors present patients with a minimum follow-up period of 12 months, with recurrences not being noted to date, consistent to the low recurrence rate of the localized form, as described in literature. Patient number one on Table 1 reported a clinical history of previous arthroscopic procedure, with recurrence of symptoms 3 months later. Magnetic resonance showed an image that was very similar to that evidenced preoperatively. An arthroscopic review was performed in our medical service, with lesion

Order number	Gender	Age (years)	Follow-up period (months)	Lesion site
1	Male	34	73	Medial suprapatellar recess
2	Female	23	64	Medial meniscus-capsular union
3	Female	22	42	Medial suprapatellar recess
4	Male	5	30	Lateral suprapatellar recess
5	Male	33	24	Medial meniscus-capsular union
6	Male	40	18	Medial suprapatellar recess
7	Female	26	12	Anteromedial adipose pad

Table 1: Patients' order number, gender, age (years), follow-up period (months), and lesion site.

resection. The patient has been submitted to surgery 30 months ago, with no evidences of recurrence to date. In our point of view, there was an incomplete resection of the lesion in the first procedure, and not a recurrence.

There is a consensus in literature stating that the marginal excision of the LPVNS results in satisfactory outcomes^(1,8,9,13). According to Kim et al.⁽⁸⁾, arthroscopy is a valuable method for LPVNS diagnosis and treatment. Those authors state that the arthroscopic technique is less invasive than the open technique, especially when the lesion is located at the posterior compartment. Eventual associated lesions can be treated by using the same procedure.

CONCLUSION

LPVNS is a rare disease, difficult to diagnose, and, upon clinical suspect, magnetic resonance imaging is the diagnostic method of choice, and it should be requested postoperatively whenever possible. Ultimate diagnosis should be confirmed by an anatomicopathological study.

Despite the small sample, typical of the low incidence of such lesion, the authors believe that the arthroscopic excision of the LPVNS is an efficient method, with a low morbidity rate, which provides the remission of symptoms and a low recurrence rate.

REFERENCES

1. Ogilvie-Harris DJ, McLean J, Zarnett ME. Pigmented villonodular synovitis of the knee. The results of total arthroscopic synovectomy, partial arthroscopic synovectomy, and arthroscopic local excision. *J Bone Joint Surg Am* 1992; 74:119-23.
2. Rezende MU, Hernandez AJ, Amatuzzi MM. Sinovite vilonodular pigmentada do joelho: revisão e atualização de conceitos. *Acta Ortop Bras* 1994; 2:23-7.
3. Campos JCP, Terreri JE, Cardoso SM, Lacerda FM. Sinovite vilonodular pigmentada do tornozelo: relato de um caso. *Rev Bras Ortop* 1991; 26:420-4.
4. Myers BW, Masi AT. Pigmented villonodular synovitis and tenosynovitis: A Clinical epidemiologic study of 166 cases and literature review. *Medicine* 1980; 19:223-38.
5. Jaffe HL, Liechtenstein L, Sutro CJ. Pigmented villonodular synovitis, bursitis and tenosynovitis. A discussion of the synovial and bursal equivalents of the tenosynovial lesion commonly denoted as xanthoma, xanthogranuloma, giant cell tumor or myeloplasma of the tendon sheath, with some consideration of this tendon sheath lesion itself. *Arch Pathol* 1941; 31:731-65.
6. Kramer DE, Frassica FJ, Cosgarea AJ. Total arthroscopic synovectomy for pigmented villonodular synovitis of the knee. *Tech Knee Surg* 2004; 3:36-45.
7. Granowitz SP, D'Antonio J, Mankin HJ. The pathogenesis and long-term results of pigmented villonodular synovitis. *Clin Orthop* 1976;114:335-51.
8. Kim SJ, Shin SJ, Choi NH, Choo ET. Treatment for localized pigmented villonodular synovitis of the knee. *Clin Orthop* 2000; 379:224-30.
9. Lee BI, Yoo JE, Lee SH, Min KD. Localized pigmented villonodular synovitis of the knee: Arthroscopic treatment. *Arthroscopy* 1998; 14:764-8.
10. Flandry F, Hughston JC. Pigmented villonodular synovitis. *J Bone Joint Surg Am* 1987; 69:942-9.
11. Young JM, Hudacek AG. Experimental production of pigmented synovitis in dogs. *Am J Pathol* 1954; 30:799-806.
12. Van Meter CD, Rowdon GA. Localized pigmented villonodular synovitis presenting as a locked lateral meniscal bucket handle tear: A case report and review of literature. *Arthroscopy* 1994; 10:309-12.
13. Calmet J, Hernández-Hermoso J, Giné J, Jimeno F. Localized pigmented villonodular synovitis in an unusual location in the knee. *Arthroscopy* 2003; 19:144-9.
14. Chin KR, Stephen JB, Winalski C, Zurakowski D, Brick GW. Treatment of advanced primary and recurrent diffuse pigmented villonodular synovitis of the knee. *J Bone Joint Surg Am* 2002; 84:2192-202.