

# EFFECTIVENESS OF HISTOLOGY AND CYTOLOGY ON MUSCULOSKELETAL TUMOR DIAGNOSIS

PABLO MOURA DE ANDRADE LIMA<sup>1</sup>, MARCELO PARENTE OLIVEIRA<sup>1</sup>, GEORGE ROCHA FERREIRA<sup>1</sup>, TÚLIO PAES DE MEDEIROS LIMA<sup>2</sup>, JAIRO DE ANDRADE LIMA<sup>1</sup>, ROBERTO JOSÉ VIEIRA DE MELLO<sup>1</sup>

## ABSTRACT

**Objective:** To compare cytology and histology on the diagnosis of musculoskeletal neoplasms. **Method:** Fifty eight cases available to evaluation were analyzed both by cytology and histology. The results of the biopsies studied by histology and cytology were compared to the results obtained on the surgical specimen or immunohistochemistry. We determined the percentage of correct results, sensitivity, specificity, positive and negative predictive values and accuracy of each method. **Results:** Twelve per cent of biopsies were inconclusive by cytology. The percentage of correct diagnosis was 70.7% and 81% ( $p=.179$ ), the ability to differentiate benign lesions from malignant ones was 84.5% and 93.1% ( $p=0.18$ )

respectively, for cytology and histology. Cytology showed sensitivity of 87.8%, specificity of 76.5%, positive predictive value of 90%, negative predictive value of 72% and accuracy 84.5%. Histology showed sensitivity of 90.2%, specificity of 100%, positive predictive value of 100%, negative predictive value of 81% and accuracy of 93.1%. The Youden index for cytology was 64.3% and for histology it was 90.2%. **Conclusion:** Despite promising, cytology obtained by thin needle aspiration is less accurate and reliable than the histological evaluation on musculoskeletal tumors diagnosis. **Level of Evidence II, Diagnostic Studies.**

**Keywords:** Bone neoplasms. Sarcoma. Biopsy, needle.

**Citation:** Lima PMA, Oliveira MP, Ferreira GR, Lima TPM, Lima JA, Mello RJV. Effectiveness of histology and cytology on musculoskeletal tumor diagnosis. *Acta Ortop Bras.* [online]. 2014;22(3):132-5. Available from URL: <http://www.scielo.br/aob>.

## INTRODUCTION

Biopsy is a key step in the diagnosis of musculoskeletal tumors, closing the triad clinics, radiology and histology.<sup>1-3</sup>

Biopsies have been performed by open surgical incision, allowing obtaining a large tumor sample, being, however, more invasive and spreading more lesion.<sup>1,4</sup>

With improved prognosis of patients affected by musculoskeletal neoplastic lesions and the possibility of conservative, less invasive surgical technique, a less invasive technique is needed, and to date the "gold" standard is percutaneous biopsy with trephine, caliber or "tru-cut" type needles, obtaining small tissue fragments that are studied by histopathology, which allows a high rate of correct diagnosis.<sup>1,3,4</sup>

Histopathological examination requires a variable period of some days to fixation and tissue preparation, especially long in bone tumors that require decalcification.

Cytopathology of the tissue by fine needle puncture allows diagnosis in the shortest time. This test makes it possible analysis of cellular and nuclear characteristics in more detail than the

histopathological test, being faster, less invasive and less expensive than the percutaneous or open biopsy.<sup>5-11</sup>

However, the cytological study continues contradictory in the evaluation of musculoskeletal lesions,<sup>12,13</sup> because the analysis of tissue architecture, of the relationships of tumor cells with structures such as blood vessels and host tissue<sup>14</sup>, differentiation of fusocellular lesions<sup>15-17</sup> and tumor matrix are more difficult.<sup>3,9,13,18,19</sup> Another difficulty on the use of cytopathological screening in these lesions is that since they are very consistent tumors or bone tumors, there can be no sufficient detachment of cells to make the diagnosis, making the rate of undiagnosed punctures quite high.<sup>8,13,17,18</sup>

The aim of this study is to compare the accuracy rate of cytological and histological methods in the diagnosis of musculoskeletal injuries, as well as their capabilities to determine the presence of tissue malignancy.

## MATERIALS AND METHODS

Medical records of patients requiring biopsy for diagnosis that were studied separately by cytology and histology from January

All the authors declare that there is no potential conflict of interest referring to this article.

1. Orthopedic and Traumatology Service, Hospital das Clínicas, UFPE, Recife, PE, Brazil.  
2. Hospitais Agamenon Magalhães e IMIP, Recife, PE, Brazil.

Work developed at Graduate Program on Pathology, Centro de Ciências da Saúde, Universidade Federal de Pernambuco (CCS-UFPE), Recife, PE, Brazil.

Correspondence: Av. Prof. Moraes Rego, 1235, Prédio da Pós-Graduação do Centro de Ciências da Saúde (CCS) térreo. Cidade Universitária, Recife, PE, Brazil. 50670-901. [pablodeandradelima@gmail.com](mailto:pablodeandradelima@gmail.com)

Article received in 02/23/2011, approved in 04/16/2012.

to December 2010, totalizing 63 cases were reviewed. Five (7.9%) cases were excluded, in which both methods showed no neoplasm were considered puncture errors, i.e. the lesion was not sampled at biopsy.

Thus, 58 cases, 39 bone tumors and 19 soft tissue tumors were evaluated. (Table 1) The masculine gender represented 48.5% and the female, 51.5%.

The patient's age at biopsy time ranged from 3 to 74 years old, dispersion measures were not obtained, because this variable was not the target of our study.

The standard for comparison of methods was histopathology of the surgical specimen or immunohistochemistry, when resection of the lesion was not required.

Data were analyzed using the software Statistical Package for the Social Sciences for Windows version 12.0.

The percentage of correct diagnoses and the percentage of correct answers on the presence of malignancy were evaluated by McNemar test for paired samples ( $p$  value < 0.05).

Sensitivity, specificity, positive and negative predictive values and accuracy of each method and its confidence interval

(95% CI) were also determined, besides the Youden index (probability of correct classification) and determining the area under the ROC curve.

## RESULTS

Among the cases studied, seven had an inadequate sample for cytological diagnosis (insufficient sample, presence or absence of atypical neoplasia cells), representing 12% of cases.

The percentage of accuracy of cytology to the histologic type of tumor was 70.7%, while histology's was 81% ( $p = 0.179$ ). (Figure 1) When assessing separately the cases of bone tumors, the diagnostic capability of cytology was 74.4% and histology's was 76.9% with  $p > 0.999$ . (Figure 1) Regarding soft parts lesions, the accuracy was 63.2% for cytology and 89.5% for histology with  $p = 0.063$ . (Figure 1)

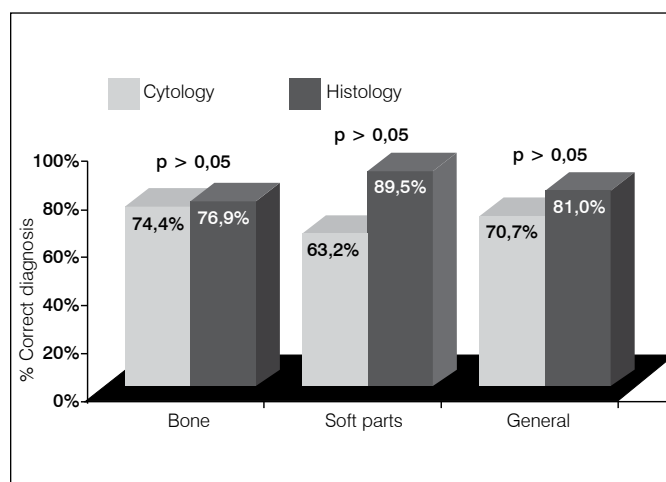
Evaluating only the ability to differentiate a malignant lesion from a benign one, cytology achieved 84.5% accuracy, while histology 93.1% ( $p = 0.18$ , Figure 2). Analyzing separately soft parts and bone lesions, cytology achieved 78.9% and 87.3%, respectively, while histology 89.5% and 94.6%, respectively, with  $p = 0.625$  and 0.375, respectively. (Figure 2)

**Table 1.** Quality measurements in diagnosis tests.

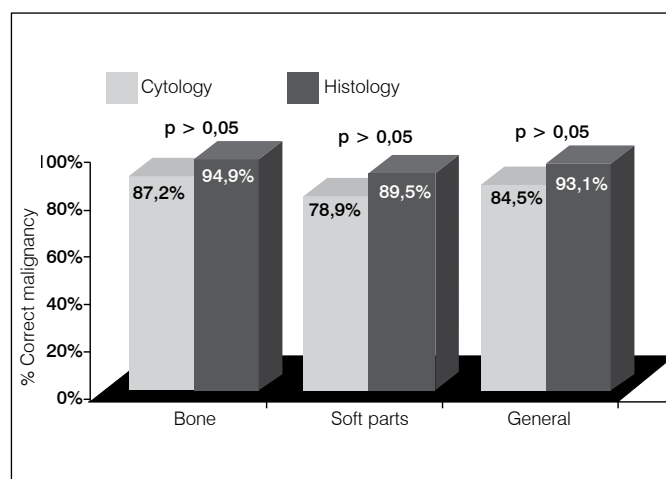
Measurements	Cytology (CI = 95%)	Histology (CI = 95%)
Sensitivity (%)	87,8 (82,7; 98,5)	90,2 (86,9; 96,1)
Specificity (%)	76,5 (68,5; 98,7)	100 ---
VPP (%)	90,0 (86,2; 99,5)	100 ---
VPN (%)	72,2 (62,1; 96,2)	81,0 (60,0; 92,3)
Accuracy (%)	84,5 (81,3; 98,1)	93,1 (81,4; 96,3)
Youden Index (%)	64,3 (59,7; 87,1)	90,2 (84,9; 96,7)
Area under the curve ROC (%)	89,3	92,2

CI: Confidence Interval

Acta Ortop Bras. 2014;22(3):132-5



**Figure 1.** Percentage of correct diagnosis on cytological and histological tests.



**Figure 2.** Percentage of correct malignancy determinations.

The sensitivity of cytological and histological method for determining the presence of malignancy in the tissue sample was, respectively, 87.8% (confidence interval 82.7 to 98.5) and 90.2% (confidence interval 86.9 to 96.1). The specificity of the methods was 76.5% (confidence interval 68.5 to 98.7) and 100%, respectively. The positive predictive values were 90% (confidence interval 86.2 to 99.5), and 100%, respectively for cytology and histology. The negative predictive value was 72% (confidence interval 62.1 to 96.2) and 81% (confidence interval 60 to 96.3) for the respective methods. The accuracy of cytological and histological methods was 84.5% (confidence interval 81.3 to 98.1) and 93.1% (81.4 to 96.3), respectively. (Table 1)

The Youden cytology index was 64.3% (confidence interval 59.7 to 87.1) and histology's was 90.2% (confidence interval 84.9 to 96.7). (Table 1) However, the area under the ROC curve was 89.3 to 92.2 for cytology and 92.2 for histology. (Table 1)

There was one false positive case for malignancy for cytology, representing 2.17% of the cytology sample and two false negative cases, accounting for 2.34%.

Regarding histology, there were no false positive cases, but there were four false negative cases, totalizing 6.8% of the sample.

## DISCUSSION

To date, the gold standard is still percutaneous biopsy with trephine or "core" biopsy for histological evaluation of musculoskeletal lesions, obtaining high accuracy rates, such as 73.9%,<sup>2</sup> to 96%,<sup>20</sup> as observed in our study received similar success rate with 92.19%.

The fine needle biopsy and cytological examination is still contradictory in the evaluation of musculoskeletal lesions<sup>12,13,21</sup> but it is gaining supporters, due to faster results, lower cost and lower invasiveness.<sup>5</sup>

Its results, however, are not yet as accurate as those of the traditional technique, being mentioned various reasons such as differentiating difficulty of the intercellular matrix,<sup>3,9,13,18</sup> sample scarcity<sup>8</sup> and cytological similarity between different lesions as various fusocellular lesions,<sup>6-12,15,16,18,20-23</sup> also leading to difficulties in differentiating between benign and malignant lesions. The histological resemblance and particularly cytological between lesions is most pronounced in soft tissue lesions, corroborating the results obtained in our study, in which the ability to determine the specific cytology diagnosis was 63.2% compared with 89.5% from histology, while indices for bone lesions were 74.4% and 76.9%, respectively.

Several authors have underlined the need for close integration with pathologists<sup>21</sup> and the presence of this professional at the time of puncture, in order to decrease the chance of a puncture with little or insufficient sample,<sup>13,18</sup> since the index of sample scarcity of 0.005% in known metastatic lesions<sup>6</sup> to 31%<sup>24</sup> are reported in the literature, the index of the sample under study being 10.72% In order to improve cytology's diagnostic ability, overcoming the poorest sample, several authors emphasize the use of ancillary techniques such as histochemistry, immunohistochemistry, electron microscopy and citogenetics.<sup>5,6,9,12,15</sup>

Besides the diagnosis itself, the need to histological grading subclassing by cytopathology is more difficult and may in many types of cancer hinder the treatment decision,<sup>11,12,14,20,25</sup> this aspect was not evaluated in our work.

For the reasons discussed above, there are very few authors who would, like Akerman, use cytopathology alone to determine the patients' treatment,<sup>22</sup> but this author uses the technique since the early 70s, in a referral center with all auxiliary techniques, optimizing the information obtained by the cytological sample.<sup>5</sup>

False positive frequencies for malignancy of 0.27%<sup>23</sup> to 5%<sup>16,17</sup> were also cited, as observed in our study in case #26. (Table 1) False negative cases showed similarly high incidences of 1.17%<sup>24</sup> to 8.5%<sup>14</sup> in the literature, such as the frequency found in our study, 2.34% and 6.8% for cytology and histology, respectively. The clinical consequences of the interpreting a benign lesion as malignant or vice versa would be catastrophic if the treatment was based on that diagnosis.

Some cancers are notoriously difficult to diagnose through biopsy samples, such as chondral lesions, as pointed Etchebehere, and it is even questionable the indication for biopsy of these lesions before resection.<sup>26</sup>

In our study, there was no statistically significant difference between the histological and cytological methods in the ability to determine the diagnosis of lesions, as well as as in differentiating benign from malignant lesions, but it is observed a statistical trend in favor of the histological analysis. As our study was not bulky, an increased sample may in the future show a more reliable result.

However, the analysis of sensitivity, specificity, positive and negative predictive values, and accuracy show that the histological method was more efficient in the diagnosis of musculoskeletal lesions in our sample, as shown by the smaller confidence intervals of tests for quality of methods and larger areas above the ROC curve in favor of histology

Few studies in the literature have directly compared the two diagnostic methods in the same cases.

Dalén obtained the diagnosis of a desmoid tumor in 50.72% of biopsies by fine needle puncture and in 92.3% of samples by core biopsies. However Yang, who studied musculoskeletal tumors, obtained 88% accuracy for determination of malignancy and 64% for specific diagnosis using cytopathology, and 93% and 83% with histopathology, respectively. These studies, like ours, show a clear superiority of histological analysis in this type of lesion.

## CONCLUSION

In this sample, there was no statistically significant difference between the cytological and histological methods in the ability to diagnose bone lesions or soft tissue tumors, or the ability to differentiate benign from malignant lesions in these tumors. It was, however, perceived a statistical trend in favor of histology, suggesting that it is the most accurate method to evaluate these lesions.

The sensitivity and specificity, positive and negative predictive values, and accuracy, however, were higher in the histological method.

We thus still do not recommend using the cytological method alone for diagnosis and decision of conduct of musculoskeletal lesions, since it is worse than the histological method.

Increased experience and routine auxiliary methods make cytopathology very promising in assessment of musculoskeletal tumors.

## REFERENCES

1. David A, Rios AR, Tarragô RP, Dalmina V. Biópsia com agulha nos tumores ósseos. *Rev Bras Ortop.* 1996;31(1):89-92.
2. Siqueira KL, Viola DCM, Jesus-Garcia R, Gracitelli GC. Correlação do tipo de biópsia e sua validade diagnóstica nos tumores musculoesqueléticos em distintas topografias. *Rev Bras Ortop.* 2008;43(1-2):7-14.
3. Pramesh CS, Deshpande MS, Pardiwala DN, Agarwal MG, Puri A. Core needle biopsy for bone tumors. *Eur J Surg Oncol.* 2001;27(7):668-71.
4. Cassone AE, Barbi Gonçalves JC, Aguiar S. Eficácia da biópsia com agulha nos tumores ósseos. *Rev Bras Ortop.* 1996;31(11): 891-4
5. Akerman M, Domanski A. Fine needle aspiration (FNA) of bone tumours: with special emphasis on definitive treatment of primary malignant bone tumour based on FNA. *Curr Diagn Pathol.* 1998; 5: 82-92.
6. Kljanienco J, Caillaud JM, Orbach D, Brisse H, Lagacé R, Vielh P et al. Cyto-histological correlations in primary, recurrent and metastatic rhabdomyosarcoma: the Institut Curie's experience. *Diagn Cytopathol.* 2007;35(8):482-7.
7. Kljanienco J, Caillaud JM, Lagacé R, Vielh P. Cytohistologic correlations in angiosarcoma including classic and epithelioid variants: Institut Curie's experience. *Diagn Cytopathol.* 2003;29(3):140-5.
8. Kljanienco J, Caillaud JM, Lagacé R, Vielh P. Fine-needle aspiration of leiomyosarcoma: a correlative cytohistopathological study of 96 tumors in 68 patients. *Diagn Cytopathol.* 2003;28(3):119-25.
9. Kljanienco J, Caillaud JM, Orbach D, Brisse H, Lagacé R, Sastre-Gareau X. Cyto-histological correlations in primary, recurrent, and metastatic bone and soft tissue osteosarcoma. Institut Curie's experience. *Diagn Cytopathol.* 2007;35(5):270-5.
10. Kljanienco J, Caillaud JM, Lagacé R. Fine-needle aspiration of primary and recurrent benign fibrous histiocytoma: classic, aneurysmal, and myxoid variants. *Diagn Cytopathol.* 2004;31(6):387-91.
11. Kljanienco J, Caillaud JM, Lagacé R, Vielh P. Comparative fine-needle aspiration and pathologic study of malignant fibrous histiocytoma: cytodiagnostic features of 95 tumors in 71 patients. *Diagn Cytopathol.* 2003;29(6):320-6.
12. Kilpatrick SE, Cappellari JO, Bos GD, Gold SH, Ward WG. Is fine-needle aspiration biopsy a practical alternative to open biopsy for the primary diagnosis of sarcoma? Experience with 140 patients. *Am J Clin Pathol.* 2001;115(1):59-68.
13. Dodd LG, Scully SP, Cothran RL, Harrelson JM. Utility of fine-needle aspiration in the diagnosis of primary osteosarcoma. *Diagn Cytopathol.* 2002;27(6):350-3.
14. Dey P, Mallik MK, Gupta SK, Vasishta RK. Role of fine needle aspiration cytology in the diagnosis of soft tissue tumours and tumour-like lesions. *Cytopathology.* 2004;15(1):32-7.
15. Domanski HA, Akerman M, Rissler P, Gustafson P. Fine-needle aspiration of soft tissue leiomyosarcoma: an analysis of the most common cytologic findings and the value of ancillary techniques. *Diagn Cytopathol.* 2006;34(9):597-604.
16. Domanski HA, Akerman M, Engellau J, Gustafson P, Mertens F, Rydholm A. Fine-needle aspiration of neurilemoma (schwannoma). A clinicocytopathologic study of 116 patients. *Diagn Cytopathol.* 2006;34(6):403-12.
17. Dalén BP, Meis-Kindblom JM, Sumathi VP, Ryd W, Kindblom LG. Fine-needle aspiration cytology and core needle biopsy in the preoperative diagnosis of desmoid tumors. *Acta Orthop.* 2006;77(6):926-31.
18. Domanski HA, Akerman M. Fine-needle aspiration of primary osteosarcoma: a cytological-histological study. *Diagn Cytopathol.* 2005;32(5):269-75.
19. Handa U, Bal A, Mohan H, Bhardwaj S. Fine needle aspiration cytology in the diagnosis of bone lesions. *Cytopathology.* 2005;16(2):59-64.
20. Yang YJ, Damron TA. Comparison of needle core biopsy and fine-needle aspiration for diagnostic accuracy in musculoskeletal lesions. *Arch Pathol Lab Med.* 2004;128(7):759-64.
21. Ng VY, Thomas K, Crist M, Wakely PE Jr, Mayerson J. Fine needle aspiration for clinical triage of extremity soft tissue masses. *Clin Orthop Relat Res.* 2010; 468(4):1120-8.
22. Fleshman R, Mayerson J, Wakely PE Jr. Fine-needle aspiration biopsy of high-grade sarcoma: a report of 107 cases. *Cancer.* 2007;111(6):491-8.
23. Khalbuss WE, Teot LA, Monaco SE. Diagnostic accuracy and limitations of fine-needle aspiration cytology of bone and soft tissue lesions: a review of 1114 cases with cytological-histological correlation. *Cancer Cytopathol.* 2010;118(1):24-32.
24. Jorda M, Rey L, Hanly A, Ganjei-Azar P. Fine-needle aspiration cytology of bone: accuracy and pitfalls of cytodiagnosis. *Cancer.* 2000;90(1):47-54.
25. Kilpatrick SE, Ward WG, Bos GD. The value of fine-needle aspiration biopsy in the differential diagnosis of adult myxoid sarcoma. *Cancer.* 2000;90(3):167-77.
26. Etchebehere M, Camargo OP, Croci AT, Oliveira CRCM, Baptista AM. O papel da biópsia percutânea prévia no diagnóstico histológico definitivo na suspeita de lesões cartilaginosas malignas do esqueleto. *Rev Bras Ortop.* 1999; 34(1):77-80.