

# LIGAMENT PRESERVING TOTAL HIP ARTHROPLASTY PREVENTS DIFFERENT LEG LENGTH AND FEMORAL OFFSET

## ARTROPLASTIA TOTAL DO QUADRIL COM PRESERVAÇÃO DE LIGAMENTOS PREVINE COMPRIMENTOS DIFERENTES DA PERNA E OFFSET FEMORAL

MASAHIRO FUJITA<sup>1,2</sup> , SHINYA HAYASHI<sup>2</sup> , TOMOYUKI KAMENAGA<sup>2</sup> , TAKAAKI FUJISHIRO<sup>1</sup> , TOMOYUKI MATSUMOTO<sup>2</sup> , RYOSUKE KURODA<sup>2</sup> 

1. Centre Takatsuki General Hospital, Department of Orthopaedic Surgery and Joint Surgery, Kosobe-Chou, Takatsuki, Osaka, Japan.  
2. Kobe University Graduate School of Medicine, Kusunoki-Cho, Chuo-Ku, Kobe, Hyogo, Japan.

### ABSTRACT

**Objectives:** The leg length (LL) and femoral offset (FO) discrepancy following total hip arthroplasty (THA) are important factors for postoperative outcomes and restoring native hip biomechanics is essential for THA. Hip capsular ligament contributes to joint stability; however, there are few studies about the influence of ligament preservation on LLD and FO following THA. **Methods:** We conducted a retrospective study involving 60 patients who underwent primary THA using a short stem through the anterolateral approach between June 2016 and August 2018. From August 2017, we preserved the vertical band of iliofemoral ligament and the pubofemoral ligament in THA, and the compared pre- and postoperative radiographic LLD and FO difference between the ligament preservation (n = 30) and ligament excision (n = 30) groups. **Results:** Postoperative LLD was significantly smaller in the ligament preservation than in the ligament excision group. The ratio of excessive LLD and FO difference was lower in the ligament preservation group than the ligament excision one. **Conclusion:** The preservation of the hip capsular ligament suppressed the increased LLD and FO difference. **Level of Evidence II; Prognostic Study - Investigation of the Effect of a Patient Characteristic on the Outcome of a Disease.**

**Keywords:** Arthroplasty, Arthroplasty, Replacement, Hip, Ligaments, Leg Length Inequality.

### RESUMO

**Objetivos:** A discrepância do comprimento da perna (CP) e do offset femoral (OF) após a artroplastia total do quadril (ATQ) são fatores importantes para os resultados pós-operatórios, e a restauração da biomecânica original do quadril é essencial para a ATQ. O ligamento capsular do quadril contribui para a estabilidade articular; entretanto, existem poucos estudos sobre a influência da preservação ligamentar no LLD e FO após ATQ. **Métodos:** Realizamos um estudo retrospectivo envolvendo 60 pacientes submetidos à ATQ primária com haste curta por via anterolateral entre junho de 2016 e agosto de 2018. A partir de agosto de 2017, a banda vertical do ligamento iliofemoral e do ligamento pubofemoral na ATQ foram preservadas e comparadas à diferença de LLD e FO radiográficas pré- e pós-operatórias entre os grupos de preservação ligamentar (n = 30) e excisão ligamentar (n = 30). **Resultados:** O LLD pós-operatório foi significativamente menor no grupo de preservação do ligamento que no grupo de excisão do ligamento. A razão de diferença de LLD e FO excessivas foi menor no grupo de preservação do ligamento do que no grupo de excisão do ligamento. **Conclusão:** A preservação do ligamento capsular do quadril suprimiu o aumento da diferença de LLD e FO. **Nível de evidência II; Estudo Prognóstico - investigação do Efeito da Característica de um Paciente no Desfecho da Doença.**

**Descritores:** Artroplastia, Artroplastia de Quadril, Ligamentos, Desigualdade de Membros Inferiores.

**Citation:** Fujita M, Hayashi S, Kamenaga T, Fujishiro T, Matsumoto T, Kuroda R. Ligament preserving total hip arthroplasty prevents different leg length and femoral offset. *Acta Ortop Bras.* [online]. 2022;30(1)Esp.: Page 1 of 4. Available from URL: <http://www.scielo.br/aob>.

### INTRODUCTION

Total hip arthroplasty (THA) is an effective treatment for hip osteoarthritis (OA) in long-term studies;<sup>1,2</sup> however, hip dislocation is a major complication which severely decreases patient satisfaction following THA.<sup>3</sup> Lower leg length and offset decrease the soft tissue tension and increase risk of dislocation;<sup>4</sup> thus, surgeons have to be careful

not to reduce leg length and offset after THA. In previous studies, the leg length of the operative side tends to be longer than that of the contralateral side after THA.<sup>5</sup> However, more than 10 mm leg length discrepancy (LLD) decreases patient satisfaction following THA, and excessive LLD is associated with many postoperative complaints such as lower back pain, abnormal gait, decreased

All authors declare no potential conflict of interest related to this article.

The study was conducted at Kobe University Graduate School of Medicine, Department of Orthopedic Surgery, Kusunoki-Cho, Chuo-Ku, Kobe, Hyogo, Japan. 650-0017. Correspondence: Shinya Hayashi. Kobe University Graduate School of Medicine, Department of Orthopedic Surgery, Kusunoki-Cho, Chuo-Ku, Kobe, Hyogo, Japan. 650-0017. s11793290@yahoo.co.jp

Article received on 08/31/2020, approved in 01/21/2021.



walking distance, and nerve palsies.<sup>6,7</sup> An increased femoral offset (FO) showed positive effect on abductor muscle force in several studies;<sup>8</sup> however, excessive FO leads negative effect such as thigh pain.<sup>9</sup> Finally, the proper leg length and offset is an important factor for proper soft tissue tension and joint stability, and restoring normal hip biomechanics seems to be one of the most important goals of THA.<sup>10</sup> Joint instability leads to the risk of postoperative dislocation and increased revision rate.<sup>11</sup> The joint capsular ligament is an important factor for hip joint stability, and some authors reported that the excision of capsular ligament increased joint instability in cadaveric studies.<sup>12,13</sup> Previous studies reported that restoring native leg length and offset was improved by using navigation systems,<sup>14</sup> intraoperative radiographic fluoroscopy.<sup>15</sup> However, there are no studies regarding the relationship between the preservation of hip capsular ligament and limb length discrepancy and hip offset differences.

The present study aims to investigate the relationship between hip capsular ligament and postoperative leg length and hip offset between patients after THA with a ligament excision procedure and those after THA with a ligament preservation procedure. We hypothesized that the patients who underwent THA with ligament preservation had suppressed postoperative LLD and FO difference compared to those who had THA with ligament excision.

## MATERIAL AND METHODS

### Patients

The study protocol was approved by the ethics committee of our institution, and informed consent was obtained from all participants. The Institutional Review Board number of the published article was 2018-26. This retrospective cohort study enrolled 164 consecutive patients with hip OA who underwent primary unilateral THA at our institutions between June 2016 and August 2018. Our inclusion criteria were patients who had substantial pain and difficulty in daily activities with hip OA and understood primary unilateral THA using a cement-less cup, G7 (Zimmer-Biomet, Warsaw, IN) cement-less short stem; Minima (Lima Corporate, Villanova, Italia), or Fitmore (Zimmer Biomet, Warsaw, IN, USA) through the anterolateral approach in the supine position. The exclusion criteria were active infection, revision THA, and operative history on the contralateral side. Of 164 patients, 4 patients underwent THA through the direct lateral approach because of severe OA with joint collapse, 10 patients underwent revision THA, 3 patients had rheumatoid arthritis, 2 patients had osteonecrosis, 4 patients had the history of hip fracture, 15 patients had the history of contralateral THA, 6 patients underwent bilateral THA, and 62 patients underwent THA using other types of implants. Finally, 60 patients who met the criteria were included in this study (54 women and 6 men; age:  $69.1 \pm 10.4$  years, body mass index (BMI):  $24.3 \pm 4.8$  kg/m<sup>2</sup>). From August 2017, we changed the surgical procedure from the ligament excision technique to the ligament preservation technique. Therefore, patients were divided into two groups: underwent THA with ligament excision procedure from June 2016 to July 2017 (excision group;  $n = 30$ ) or underwent THA with ligament preservation procedure from August 2017 to August 2018 (preservation group;  $n = 30$ ). There was no significant difference in patient characteristics between the two groups (Table 1).

**Table 1.** Patients' characteristics.

Characteristic	Preservation group	Excision group	P-value
Number of cases	30	30	
Sex, female / male	28 / 2	26 / 4	0.39
Age, years	$68.4 \pm 11.3$	$69.8 \pm 9.5$	0.61
Height, cm	$152.4 \pm 7.7$	$152.8 \pm 8.2$	0.88
Weight, kg	$54.2 \pm 11.9$	$58.8 \pm 11.7$	0.14
Body mass index, kg/m <sup>2</sup>	$23.3 \pm 4.7$	$25.2 \pm 4.4$	0.12

### Operative procedures

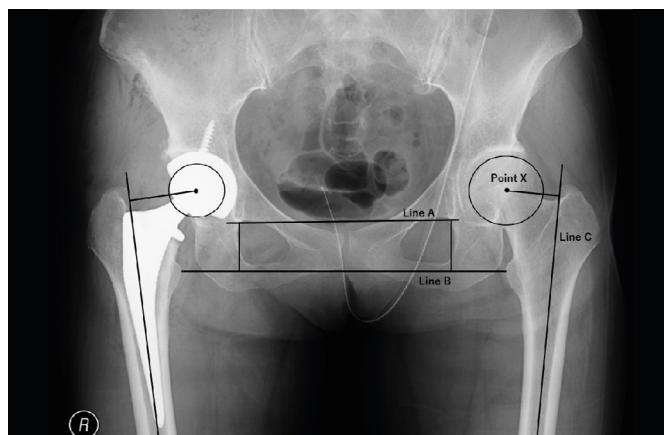
One senior surgeon (T.F.) performed all surgeries. The patients were placed on a horizontal operative table in the spine position, and the anterolateral approach was performed. An approximately 12-cm straight incision starting distally and behind the anterior superior iliac spine and proceeding to the greater trochanter and femur was made. The incision was deepened to the deep fascia, and the iliotibial muscle was incised along the skin incision and retracted anteriorly and posteriorly. The interval between the gluteus medius and vastus lateralis was spread using retractors that were placed under the gluteus medius superior to the capsule ligament, inferior to the femoral neck and anterior to the acetabulum.

In the ligament preservation group, the vertical band of the iliofemoral ligament and the pubofemoral ligament were completely preserved, and only the horizontal band of the iliofemoral ligament was excised to open a minimum window for visualization of the femoral head and acetabular roof. In the ligament excision group, all of the iliofemoral ligaments and pubofemoral ligaments were removed in the traditional procedure.

According to preoperative templating, the femoral neck was cut upon acetabular exposure, and the acetabulum was reamed and the cup was implanted. Reaming and implantation of the femoral stem was performed according to preoperative templating. After trial reduction, a senior surgeon (T.F.) evaluated the joint stability using manual extension, internal rotation, and external rotation. When the dislocation was easily performed, the stem neck size was enlarged while checking limb length discrepancy and offset using intraoperative fluoroscopic imaging. After final implantation, the interval of muscles was directly sutured, and soft tissue and skin were closed in layers.

### Radiographic measurement

Preoperative and postoperative antero-posterior radiographs of the pelvis were obtained in a supine position with 15° internal limb rotation. Measurements on the radiographs were performed using a PACS client (IMPAX EE, AGFA HealthCare GmbH, Bonn, Germany). The distance between the trans-teardrop line and the most prominent aspect of the lesser trochanter line was measured, and the difference between operative side and non-operative side was obtained as LLD. The femoral offset was measured as the distance between the centre of femoral head and the anatomic axis of the femur line (Figure 1). All radiographies were assessed by two investigators (MF, TF), and all measurements were performed twice one month apart to evaluate the intra-observer and inter-observer variability. The intraclass correlation coefficient was 0.84–0.91 (intra-observer) and 0.81–0.88 (inter-observer).



**Figure 1.** Measurement of leg length and offset discrepancy. Line A is the trans-teardrop line. Line B is the lesser trochanter line. Line C is the anatomic axis of the femur. Point X is the centre of the femoral head.

## Statistical analysis

Outcomes were reported as mean  $\pm$  standard deviation (SD). Statistical analysis was performed using StatView 5.0 (Abacus Concepts Inc., Berkeley, CA, USA). The Student t-test was used to compare LLD and FO between the ligament preservation group and the ligament excision group following THA. Mann-Whitney's U test was used to compare the ratio of postoperative excessive LLD and FO difference between two groups. Post-hoc power analysis was performed using G\*Power 3. The present study had 0.86 power ( $1-\beta$ ) to detect a difference in 0.80 effect size at the  $p < 0.05$  level.

## RESULTS

(Table 2) shows the summary of LLD. Postoperative LLD was significantly smaller in the ligament preservation group than in the ligament excision group ( $0.6 \pm 3.4$  mm in preservation group and  $3.6 \pm 7.3$  mm in excision group). The rate of excessive LLD following THA was significantly smaller in the preservation group than in the excision group; more than 5mm and 10mm were 6.7% (2/30 cases) and 0% (0/30 cases) in preservation group, and 30.0% (9/30 cases) and 16.7% (5/30 cases) in excision group. The rate of excessive LLD following THA was significantly smaller in preservation group than excision group. The absolute LLD and ratio of excessive absolute LLD following THA were also significantly smaller in the preservation group than in the excision group.

(Table 3) shows the summary of FO. Postoperative FO overlengthening was suppressed in the ligament preservation group ( $-1.1 \pm 4.9$  mm

in preservation group and  $1.4 \pm 5.6$  mm in excision group), but not significantly. However, the rate of more than 5mm FO difference following THA was significantly smaller in the preservation group than in the excision group. Postoperative FO difference of more than 5mm and 10mm were 20.0% (6/30 cases) and 3.3% (1/30 cases) in the preservation group, and 40.0% (12/30 cases) and 6.7% (2/30 cases) in the excision group. The absolute FO difference and ratio of excessive absolute FO difference following THA was also smaller in the preservation group than in the excision group, but not significantly.

## DISCUSSION

The main finding of the present study is that patients who underwent THA with ligament preservation showed significantly smaller postoperative LLD compared with those after THA with the ligament excision procedure. In addition, the rate of excessive LLD and FO difference following THA was significantly smaller in the preservation group than in the excision group. The absolute LLD also showed significant suppression in the ligament preservation group. These results confirmed our prior hypothesis. This study is the first to assess the effect of preservation of hip capsular ligament on the postoperative LLD and FO in THA in the supine position. Our result suggested that the preservation of hip capsular ligaments improves the LLD and FO difference and contributes to patient satisfaction following THA.

Slightly increased leg length and offset contain the proper soft tissue tension and decrease the risk of dislocation.<sup>4,16</sup> However, excessive LLD leads to various complaints such as lower back pain, abnormal gait, decreased walking distance and nerve palsies,<sup>6,7</sup> and more than 10 mm LLD decreases patient satisfaction.<sup>17</sup> In addition, more than 5mm FO increases soft tissue tension, diminished pain relief<sup>9</sup> and linear wear.<sup>18</sup> Therefore, restoring normal leg length and offset without overlengthening is important to obtain adequate soft tissue tension and patient satisfaction.<sup>19,20</sup> In the present study, the rate of more than 5mm and 10mm LLD was significantly smaller in the preservation group than in the excision group, and the rate of more than 5mm FO difference was smaller in ligament preservation group.

The hip capsular ligaments were important components for stability of the joint, and iliofemoral ligament and pubofemoral ligament especially control the external rotation mobility.<sup>21</sup> Van Arkel et al. suggested that the anterior ligament with its straight line of action directly contributes to restraining hip laxity following THA, compared to the posterior ligament which requires wrapping tightly around the surface of the femoral head.<sup>22</sup> Myers et al. showed that excision of the iliofemoral ligament resulted in increased external rotation and anterior translation of femoral head in all flexion angles compared to the intact state.<sup>23</sup> In the present study, the preserved iliofemoral ligament and pubofemoral ligament seemed to improve joint stability, positively influence intraoperative evaluation of joint laxity, and contribute to restoring native hip biomechanics.

Our study has some limitations. First, intraoperative joint laxity was evaluated by 1 senior surgeon. The evaluation of intraoperative joint stability require the high experience of joint surgery,<sup>3</sup> thus senior surgeon is required for proper procedure. Second, we only measured leg length and offset radiographically. The slight difference of hip position can cause substantial errors in the radiographic measurement of leg length and offset, so further study using Computed Tomography scans is desired. Third, our study did not evaluate clinical outcomes. The evaluation of clinical scores and patient satisfaction is required in the future.

**Table 2.** Comparison of leg length discrepancy and excessive discrepancy ratio between ligament preservation group and ligament excision group.

	Preservation group	Excision group	
<b>LLD, mm</b>	<b>Mean <math>\pm</math> SD</b>	<b>Mean <math>\pm</math> SD</b>	<b>p-value</b>
Preoperative	-5.1 $\pm$ 3.8	-5.2 $\pm$ 6.2	0.92
Postoperative	0.6 $\pm$ 3.4	3.6 $\pm$ 7.3	< 0.05
<b>Excessive LLD ratio</b>	<b>Mean <math>\pm</math> SD</b>	<b>Mean <math>\pm</math> SD</b>	<b>p-value</b>
More than 5mm	2 / 30 (6.7 %)	9 / 30 (30.0 %)	< 0.05
More than 10mm	0 / 30 (0.0 %)	5 / 30 (16.7 %)	< 0.05
<b>Absolute LLD, mm</b>	<b>Mean <math>\pm</math> SD</b>	<b>Mean <math>\pm</math> SD</b>	<b>p-value</b>
Preoperative	5.2 $\pm$ 3.7	6.3 $\pm$ 5.0	0.32
Postoperative	2.9 $\pm$ 1.8	5.4 $\pm$ 6.0	< 0.05
<b>Excessive absolute LLD ratio</b>	<b>Mean <math>\pm</math> SD</b>	<b>Mean <math>\pm</math> SD</b>	<b>p-value</b>
More than 5mm	3 / 30 (10.0 %)	10 / 30 (33.3 %)	< 0.05
More than 10mm	0 / 30(0.0 %)	5 / 30 (16.7 %)	< 0.05

LLD: leg length discrepancy; SD: standard deviation.

**Table 3.** Comparison of femoral offset difference and excessive difference ratio between ligament preservation group and ligament excision group.

	Preservation group	Excision group	
<b>FO difference, mm</b>	<b>Mean <math>\pm</math> SD</b>	<b>Mean <math>\pm</math> SD</b>	<b>p-value</b>
Preoperative	0.7 $\pm$ 4.2	0.3 $\pm$ 5.5	0.70
Postoperative	-1.1 $\pm$ 4.9	1.4 $\pm$ 5.6	0.07
<b>Excessive FO difference ratio</b>	<b>Mean <math>\pm</math> SD</b>	<b>Mean <math>\pm</math> SD</b>	<b>p-value</b>
More than 5mm	2 / 30 (6.7 %)	8 / 30 (26.7 %)	< 0.05
More than 10mm	0 / 30 (0.0 %)	2 / 30 (6.7 %)	0.15
<b>Absolute FO difference, mm</b>	<b>Mean <math>\pm</math> SD</b>	<b>Mean <math>\pm</math> SD</b>	<b>p-value</b>
Preoperative	3.5 $\pm$ 2.4	4.1 $\pm$ 3.7	0.48
Postoperative	4.1 $\pm$ 2.8	4.6 $\pm$ 3.4	0.52
<b>Excessive absolute FO difference ratio</b>	<b>Mean <math>\pm</math> SD</b>	<b>Mean <math>\pm</math> SD</b>	<b>p-value</b>
More than 5mm	6 / 30 (20.0 %)	12 / 30 (40.0 %)	0.09
More than 10mm	1 / 30 (3.3 %)	2 / 30 (6.7 %)	0.56

FO: femoral offset; SD: standard deviation.

## CONCLUSION

In conclusion, the preservation of the vertical band of the iliofemoral ligament and pubofemoral ligament contribute to restoring the native leg length and offset following THA.

## ACKNOWLEDGMENTS

We would like to thank Editage ([www.editage.com](http://www.editage.com)) for English language editing

---

**AUTHORS' CONTRIBUTION:** Each author contributed individually and significantly to the development of this article. MF: writing, data analysis and performing surgeries; SH: final approval of the version of the manuscript to be published; TK: data analysis and performing surgeries; TF: Substantial contribute to the concept of the work, data analysis and performing surgeries; TM: review of the article and intellectual concept of the article; RK: review of the article and intellectual concept of the article.

---

## REFERENCES

1. Streit MR, Innmann MM, Merle C, Bruckner T, Aldinger PR, Gotterbarm T. Long-term (20- to 25-year) results of an uncemented tapered titanium femoral component and factors affecting survivorship. *Clin Orthop Relat Res.* 2013; 471(10): 3262-9.
2. Schmitz PP, van Susante JLC, Hol A, Brokelman R, van Loon CJM. No decline in high patient satisfaction after total hip arthroplasty at long-term follow-up. *Eur J Orthop Surg Traumatol.* 2019; 29(1): 91-5.
3. Rowan FE, Benjamin B, Pietrak JR, Haddad FS. Prevention of Dislocation After Total Hip Arthroplasty. *J Arthroplasty.* 2018; 33(5): 1316-24.
4. Charissoux JL, Asloum Y, Marcheix PS. Surgical management of recurrent dislocation after total hip arthroplasty. *Orthop Traumatol Surg Res.* 2014; 100(1 Suppl): S25-34.
5. Ranawat CS, Rodriguez JA. Functional leg-length inequality following total hip arthroplasty. *J Arthroplasty.* 1997; 12(4): 359-64.
6. Pakpianpairoj C. Perception of leg length discrepancy after total hip replacement and its impact on quality of life. *J Med Assoc Thai.* 2012; 95(Suppl 10): S105-8.
7. Röder C, Vogel R, Burri L, Dietrich D, Staub LP. Total hip arthroplasty: leg length inequality impairs functional outcomes and patient satisfaction. *BMC musculoskeletal disorders.* 2012; 13: 95.
8. Lenaerts G, De Groote F, Demeulenaere B, et al. Subject-specific hip geometry affects predicted hip joint contact forces during gait. *J Biomech.* 2008; 41(6): 1243-52.
9. Liebs TR, Nasser L, Herzberg W, Rütger W, Hassenpflug J. The influence of femoral offset on health-related quality of life after total hip replacement. *Bone Joint J.* 2014; 96-B(1): 36-42.
10. Sayed-Noor AS, Hugo A, Sjöden GO, Wretenberg P. Leg length discrepancy in total hip arthroplasty: comparison of two methods of measurement. *Int Orthop.* 2009; 33(5): 1189-93.
11. Sculco PK, Cottino U, Abdel MP, Sierra RJ. Avoiding Hip Instability and Limb Length Discrepancy After Total Hip Arthroplasty. *Orthop Clin North Am.* 2016; 47(2): 327-34.
12. Wagner FV, Negrão JR, Campos J, et al. Capsular ligaments of the hip: anatomic, histologic, and positional study in cadaveric specimens with MR arthrography. *Radiology.* 2012; 263(1): 189-98.
13. Martin HD, Khoury AN, Schröder R, et al. Contribution of the Pubofemoral Ligament to Hip Stability: A Biomechanical Study. *Arthroscopy.* 2017; 33(2): 305-13.
14. Ellapparadja P, Mahajan V, Atiya S, Sankar B, Deep K. Leg length discrepancy in computer navigated total hip arthroplasty - how accurate are we? *Hip Int.* 2016; 26(5): 438-43.
15. Hasegawa I, Wright AR, Andrews SN, Unebasmami E, Nakasone CK. Hip Offset and Leg Length Equalization in Direct Anterior Approach Total Hip Arthroplasty without Preoperative Templating. *Hawaii J Health Soc Welf.* 2019; 78(11 Suppl 2): 26-8.
16. Forde B, Engeln K, Bedair H, Bene N, Talmo C, Nandi S. Restoring femoral offset is the most important technical factor in preventing total hip arthroplasty dislocation. *J Orthop.* 2018; 15(1): 131-3.
17. Desai AS, Dramis A, Board TN. Leg length discrepancy after total hip arthroplasty: a review of literature. *Curr Rev Musculoskelet Med.* 2013; 6(4): 336-41.
18. Little NJ, Busch CA, Gallagher JA, Rorabeck CH, Bourne RB. Acetabular polyethylene wear and acetabular inclination and femoral offset. *Clin Orthop Relat Res.* 2009; 467(11): 2895-900.
19. Takao M, Nishii T, Sakai T, Sugano N. Postoperative Limb-Offset Discrepancy Notably Affects Soft-Tissue Tension in Total Hip Arthroplasty. *J Bone Joint Surg Am.* 2016; 98(18): 1548-54.
20. Plaass C, Clauss M, Ochsner PE, Ilchmann T. Influence of leg length discrepancy on clinical results after total hip arthroplasty--a prospective clinical trial. *Hip Int.* 2011; 21(4): 441-9.
21. Martin HD, Savage A, Braly BA, Palmer IJ, Beall DP, Kelly B. The function of the hip capsular ligaments: a quantitative report. *Arthroscopy.* 2008; 24(2): 188-95.
22. van Arkel RJ, Ng KCG, Muirhead-Allwood SK, Jeffers JRT. Capsular Ligament Function After Total Hip Arthroplasty. *J Bone Joint Surg Am.* 2018; 100(14): e94.
23. Myers CA, Register BC, Lertwanich P, et al. Role of the acetabular labrum and the iliofemoral ligament in hip stability: an in vitro biplane fluoroscopy study. *Am J Sports Med.* 2011; 39(Suppl): 85S-91S.