

TREATMENT OF INFECTIONS FOLLOWING TOTAL KNEE ARTHROPLASTY: 2-YEAR FOLLOW-UP OUTCOMES

CAIO OLIVEIRA D'ELIA¹, ALEXANDRE LEME GODOY DOS SANTOS², MARCOS DE CAMARGO LEONHARDT³,
ANA LÚCIA LEI MUNHOZ DE LIMA⁴, JOSÉ RICARDO PÉCORÁ⁵, GILBERTO LUÍS CAMANHO⁶

SUMMARY

Objective: The objective of this study is to analyze and standardize the treatment protocol of infections following total knee arthroplasty proposed by the Knee Group and the Infectology Group of IOT-HC-FMUSP. **Materials and Methods:** Between 2003 and 2004, twenty-nine patients (19 women and 10 men, mean age: 67 years) diagnosed with infection after total primary knee arthroplasty were hospitalized at IOT-HC FMUSP (Institute of Orthopedics and Traumatology of Hospital das Clínicas, Medical College, University of Sao Paulo, SP, Brazil) and subjected to a treatment protocol. The mean follow-up time was 20 months. Nine cases had superficial infections, three had acute deep

infections and eighteen had chronic deep infections. The classification is based on local clinical criteria and on the time of symptoms onset. **Results:** Eight patients with superficial infection and three patients with acute deep infection were treated, showing good outcomes and no recurrence cases. Eighteen patients with chronic deep infection were treated and cured, 14 of whom with no recurrence during the follow-up period. **Conclusion:** We regard our outcomes and treatment protocol as appropriate and consistent with literature.

Keywords: Knee. Arthroplasty. Prosthesis. Infection. Antibiotics.

Citation: D'Elia CO, Santos ALG, Leonhardt MC, Lima ALLM, Pécora JR, Camanho GL. Treatment of infections following total knee arthroplasty: 2-year follow-up outcomes. *Acta Ortop Bras.* [serial on the Internet]. 2007; 15(3): 158-162. Available from URL: <http://www.scielo.br/aob>.

INTRODUCTION

The concept of replacing the knee joint surface for treating serious pathologies of this joint has been discussed since the 19th Century. In 1860, Verneuil⁽¹⁾ suggested interposing soft parts in order to reconstruct knee's joint.

In 1940's and 1950's, total knee arthroplasty (TKA) showed a significant evolution due to the development of inorganic materials appropriate to joint interposition and due to surgical techniques improvement, especially levered by Campbell⁽²⁾, MacIntosh⁽³⁾ and McKeever⁽⁴⁾.

Currently, knee prosthesis with different designs and high-technology materials are available, which, associated to the increased life expectancy in worldwide population and to more accurate diagnoses of orthopaedic diseases, has strongly increased indication and duration of knee arthroplasties.

TKA is a major surgery, subjected to postoperative complications, with infection being one of the worst and most feared, representing a real challenge for orthopaedic surgeons, because of the difficult and long-term treatment⁽⁵⁾. Infections

post-total knee arthroplasty represent an economical impact of three hundred million dollars a year in the United States alone⁽⁶⁾.

The key for a successful treatment for infections following total knee arthroplasty is the early and precise diagnosis, providing immediate therapy. Therefore, it is crucial that every patient with local pain after a total knee arthroplasty is assessed for infection potential⁽⁷⁾. The clinical picture most frequently seen in cases of infection is constant pain, local heat and joint swelling. A thorough history detailing risk factors (Chart 1), an appropriate physical examination, X-ray studies and laboratory tests are employed to confirm a diagnosis.

Some blood tests must always be requested, as well as the hemosedimentation speed and reactive C-protein levels. The correlation of physical examination, X-ray images and laboratory tests is essential for the assessment of a potential infection.

Usually, treating an infection after total knee arthroplasty takes time, and the patient must understand the objectives of the therapy, its limitations and risks. Thus, treatment can

Study conducted at the Orthopaedics and Traumatology Institute.

Correspondences to: Rua Dr. Ovídio Pires de Campos, 333 - 3º andar - sala B-305 - Cerqueira César - SP - CEP: 05403-010 - Fone: 83816542 - E-mail: caiodelia@terra.com.br

1 - Assistant Doctor, Knee Group, Orthopaedics and Traumatology Institute, Hospital das Clínicas, Medical College, University of São Paulo.

2 - Preceptor Doctor, Orthopaedics and Traumatology Institute, Hospital das Clínicas, USP Medical College.

3 - Resident Doctor, Orthopaedics and Traumatology Institute, Hospital das Clínicas, USP Medical College.

4 - Head of the Hospital Infection Control Group, Orthopaedics and Traumatology Institute, Hospital das Clínicas, USP Medical College.

5 - Head of the Knee Group, Orthopaedics and Traumatology Institute, Hospital das Clínicas, USP Medical College.

6 - Associate Professor, Department of Orthopaedics and Traumatology, USP Medical College.

Received in: 05/18/06, approved in: 07/21/06

be adjusted to patient's expectations. The objective in treating infections should be infection eradication and restoring painless function of the joint. Other patients, due to local and/or systemic conditions, are not able to control their infectious picture, thus requiring procedures such as arthrodesis, amputation or resection arthroplasty. According to the international literature, its incidence ranges from 1% to 5%⁽¹⁹⁾. In excellence centers, counting on expert teams and a large volume of TKA procedures, this rate can reach less than 1%.

- Previous knee surgery
- Long surgical time (above 2.5 h)
- Co-morbidities:
 - Compromised immune system
 - Immunosuppressive therapy
 - Malnutrition
 - Hypokalemia
 - Diabetes mellitus
 - Obesity
 - Tobacco use

Chart 1 - Risk factors for infection

In the Orthopaedics and Traumatology Institute of the University of São Paulo's Medical College, the incidence of infections after TKA (according to data provided by the Committee on Hospital Infection Control) has remained around 3% in the last 3 years.

The infection paths described are as follows

1. Direct implant during surgical procedure due to a failure on operating room or implant material, inappropriate sterilization technique and long surgical time.
2. Infection secondary to intraoperative dissemination as a result of hematoma formation and inappropriate care with dressings.
3. Hematogenically, from remote focus dissemination such as urinary or pulmonary tract infection, skin ulcers and dental infection.

Classification is based on local clinical criteria and on time of symptoms onset (Chart 2).

In most infection cases, surgical procedures are required for providing an optimal treatment, except for superficial infection, which, many times, can be treated with antibiotic agents only.

In cases of deep infection, a surgical procedure is warranted for providing débridement of infected tissue. The most important question in cases of deep infection is whether prosthesis must be removed or maintained. In chronic infections, meaning the ones where patients present with symptoms for more than four weeks, or when surgery was

1. Acute infection:
 - superficial
 - deep
2. Chronic infection

Chart 2 - Classification

performed more than four weeks previously, prosthesis must be removed⁽⁸⁻¹⁰⁾.

In deep acute infection, either operative or hematogenic, trying to save the prosthesis is reasonable¹¹. In general, literature shows that prosthesis can be saved until 1 month after insertion, and that multiple débridements can enhance success rates^(8,12). However, the success rate of this kind of treatment (60% - 80%) is lower than for two-steps review, in which implants are removed⁽¹²⁾.

In deep chronic infection, meaning the one in which the patient has showed symptoms for over four weeks, or when surgery was performed more than four weeks before, the implants must be removed. The approach of keeping a prosthesis shows a low success rate^(8,9), while the two-step treatment with prosthesis removal, placement of a retractor with antibiotics, antibiotic therapy, and insertion of a review prosthesis in a second step, show success rates of approximately 90%⁽¹⁰⁾.

There are cases of advanced infection in which patients cannot afford, due to local or systemic issues, to be submitted to repeated surgical procedures, which are sometimes required to treat infection and maintain prosthesis or re-implant it. In these cases, the patients are submitted to salvage procedures (arthrodesis, amputation, resection arthroplasty), which are intended to save lives or preserve limbs^(13,14).

The objective of this study is to assess the results of our treatment protocol, in what concerns to infectious process cure.

MATERIALS AND METHODS

In the period of 2003 and 2004, twenty nine patients diagnosed with primary infection after total knee arthroplasty were hospitalized for treatment at the Orthopaedics and Traumatology Institute (IOT), Hospital das Clínicas, University of São Paulo's Medical College, and submitted to a treatment protocol. Among these, nine cases had superficial infection, three cases of deep acute infection, and eighteen deep chronic infections.

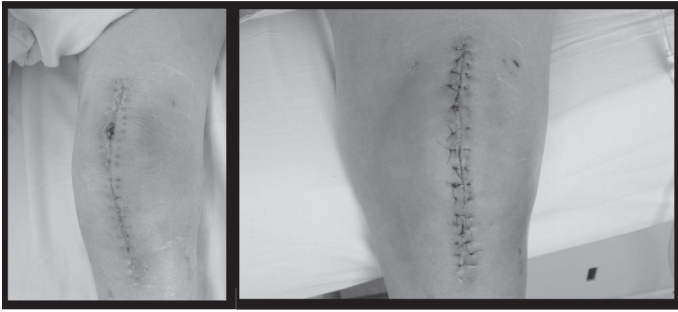
Of the 29 patients assessed in this study, 19 were women and 10 were men; the mean follow-up period was 20 months, and the mean age was 67 years.

All patients with superficial infection and deep acute infection have been treated from baseline in our service. Regarding patients with deep chronic infection, sixteen were treated since onset in our service, and two were referred to our institution.

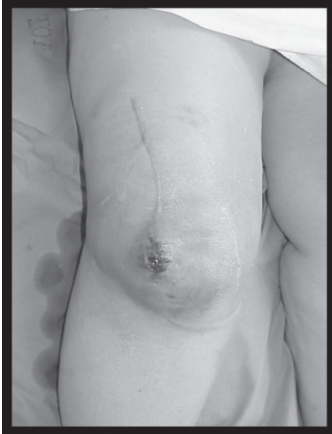Patients diagnosed with superficial infection were treated with endovenous antibiotic therapy for 4-6 weeks, and, whenever necessary, surgical débridement of the site was performed, making an ellipsoidal incision on the margins and inserting subcutaneous fat up to capsule level (Photograph 1).

The cases of deep acute infection (Photograph 2) were treated by careful débridement by means of arthrotomy and replacing polyethylene, thus allowing for a better access to posterior recess of the knee, endovenous antibiotic therapy for 4-6 weeks, being clinically and laboratorially followed up by means of hemogram with leukocytes counts, hemocritation speed and reactive C-protein measurements.

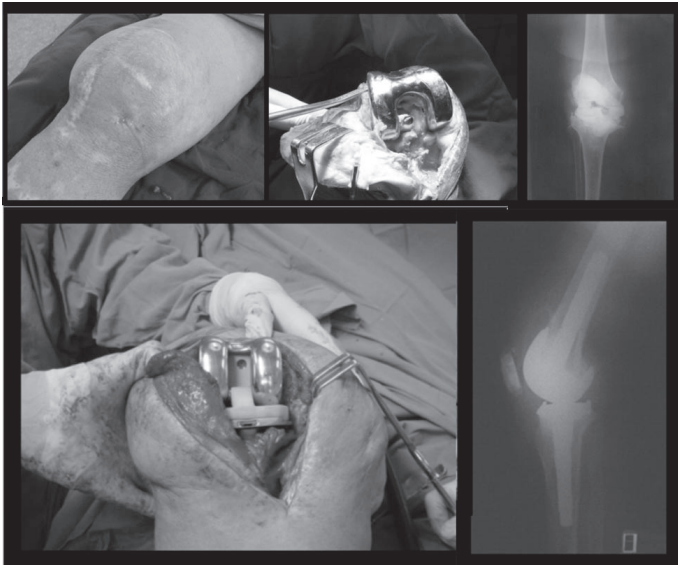
Patients diagnosed with deep chronic infection were treated by removing femoral and tibial implants; careful débridement including synovectomy, removal of all cement and unviable



Photograph 1 - Superficial infection: patient submitted to endovenous antibiotic therapy for 4 weeks and surgical débridement of the site, and ellipsoidal removal of incision margins, and insertion of subcutaneous fat up to capsule level.



Photograph 2 - Deep acute infection



Photograph 3 - Deep chronic infection: primary prosthesis removal, débridement, insertion of retractor and implantation of a review prosthesis after 6 weeks.

tissues, and; insertion of a cement + antibiotics retractor (1g vancomycin was used for each pack of orthopaedic cement), designed to maintain soft parts tension and a high local release of antibiotic agent. Then, a period of antibiotic therapy, initially endovenous, followed, which was supplemented by antibiotics administrated via oral, whenever possible, and collecting material for laboratory tests (hemogram with

leukocytes count, hemosedimentation speed and reactive C-protein measurements). Upon normal tests, the patients were submitted to review, removing the retractor and implanting a new prosthesis. After the insertion of a review prosthesis, antibiotic therapy was maintained according to the results of the cultures, for 4-6 months.

Patients with deep chronic infection presenting two-step treatment failure and who could not clinically or systemically afford repeated surgeries were submitted to salvage procedures (arthrodesis, transfemoral amputation).

RESULTS

- Eight patients with superficial infection were treated, showing good outcomes, and cure of the infectious process in all cases.

- Three patients with deep acute infection were treated, with 100% cure rate, and no recurrences during follow-up period.

- Eighteen cases of deep chronic infection were treated, 14 of which resulting in cure without recurrence during follow-up period. Four patients didn't achieve cure with the therapy, two of them presented infection recurrence after review prosthesis insertion, although intraoperative cultures did not show bacterial growth. The remaining 2 patients were submitted to salvage procedures, one to amputation and the other to arthrodesis.

The time interval between suspected infection and treatment onset showed some variation. In cases of superficial infection, the interval was always as short as one day. In patients with deep acute infection, this interval was as short as a month for 12 patients, between one and three months for two patients, between three and six months for two patients, and more than six months for two patients. Both patients with late treatment start are those submitted to salvage procedures. The remaining two patients presenting treatment failure were included in the group whose treatment started between three and six months.

DISCUSSION

Infection after total knee arthroplasty is certainly a serious complication, and must always be appropriately diagnosed and treated. An incorrect or late diagnosis can significantly change a patient's prognosis.

Superficial infections must be aggressively treated, avoiding progression to deep infection, which would put the prosthesis, the limb, or even the life of a patient at risk. Attention should be given to the fact that infections can be more extensive than it apparently is, and the threshold to recommend thorough surgical débridement should be low (Chart 3).

In deep acute infection, wither of operative or hematogenic nature, trying to save the prosthesis is reasonable¹¹. Infections of operative nature are those where the onset of symptoms occur within up to four weeks after prosthesis implantation. The hematogenic infection is the one where the onset of joint symptoms occurs within up to four weeks after a remote infectious picture (whether urinary, dental, respiratory or cutaneous). In both kinds of acute infection, surgical treatment is recommended, and the faster it is provided, the better the success rate^(15,16). A study showed that

after two weeks of symptoms complaints, prosthesis salvage is unlikely ⁽¹⁷⁾. In general, literature shows that a prosthesis can be saved as long as one month after implantation, and that multiple débridement procedures can increase success rates ^(9,16). However, the success rate for this kind of treatment (60% - 80%) is lower when compared to that of the two-step review, in which the implant is removed ⁽¹²⁾. (Chart 4)

The major objective when treating an infection after total knee arthroplasty is cure, and, obviously, the functional outcome is also important. Several treatment alternatives are provided by literature for treating deep chronic infection by means of the one-step review, being this approach justifiable due to the better functional outcomes it may present ⁽¹⁸⁾. Our option towards performing the two-step review is grounded on the higher rates of cure and because we consider that the functional damage caused by the two-step review does not justify the higher risk imposed by the one-step review ^(10,17,19-21).

In chronic infections, meaning those where patients present with symptoms for more than four weeks, or when time elapsed since surgery is above four weeks, the implants should be removed. Keeping a prosthesis shows low success rates ^(6,9), while the two-step review including prosthesis removal and placement of a retractor with antibiotics, antibiotic therapy

and insertion of a review prosthesis as a second step, shows success rates around 90% ⁽¹⁰⁾.

In chronic infections, the protocol adopted is the one suggested by Insall et al. ⁽²⁰⁾ and Windsor et al. ⁽²¹⁾, which consists of removing the femoral and tibial implant; careful débridement including synovectomy, removal of all cement and unviable tissues, and; insertion of cement + antibiotics retractor, designed to maintain soft parts tension and a high local antibiotic release ⁽¹⁸⁾. Then, a period of antibiotic therapy, initially endovenous, follows for two weeks, supplemented by antibiotics administrated via oral, totaling 6 weeks of therapy. After that period, patients are clinically reassessed, material for laboratory tests is collected (hemogram with leukocytes count, hemosedimentation speed and reactive C-protein measurements). Upon normal tests, patients are submitted to review, removing the retractor and implanting a new prosthesis. (Chart 5)

A characteristic of our institution, for being a reference for other services, is to receive and treat patients with serious conditions, sometimes not optimally treated, constituting cases of difficult solution, where keeping a prosthesis or an attempt to re-implant it would put patients' lives or limbs at risk. In our case series, two patients had been initially treated

Diagnosis	Treatment	Source of infection	Result of the Institution
-Less than 4 weeks -Fever -Local inflammation -Absence of fistulas -Does not exceed capsule	-Antibiotic therapy EV 4 - 6 weeks -Surgical débridement	-intraoperative contamination	8/8

Chart 3 - Superficial infection

Diagnosis	Treatment	Source of Infection	Result of the Institution
-Less than 4 weeks -Fever -Local inflammation -Absence of fistulas -Exceeds capsule	-Antibiotic therapy EV 4 - 6 weeks -Surgical débridement with polyethylene replacement.	-intraoperative contamination - hematogenic	3/3

Chart 4 - Deep acute infection

Diagnosis	Treatment	Source of Infection	Result of the Institution
-More than 4 weeks -Fever -Local inflammation or not -May have fistulas -Fluids/ /pus -Exceeds capsule	-Antibiotic therapy EV 4 - 6 months -Surgical débridement with prosthesis replacement in two steps	-intraoperative contamination -hematogenic	14/18

Chart 5 - Deep chronic infection

somewhere else, with both presenting multiple fistulas and being treated with withdrawal antibiotic therapy for more than a year. One of these developed renal failure during treatment, in whom amputation was recommended, and the other showed no local skin conditions and an insufficient extensor mechanism, thus being submitted to arthrodesis.

Advancements in the treatment of infections after total knee arthroplasty include the emergence of new antibiotic drugs that can be administered via oral or intramuscular, reducing hospitalization time and, therefore, treatment costs and the

psychological impact caused by long-term hospitalization on patients. New hinged retractors are also being used, perhaps improving functional outcomes in two-steps reviews.

CONCLUSION

We regard our results and our treatment protocols as appropriate and consistent with literature in what concerns to infection control. We believe that a higher number of patients and a longer follow-up period are required for us to be able to present definite conclusions.

REFERENCES

- 1- Verneviul A. De lá création d'une fausse articulation par section ou ressection partielle de l'os maxillaire inférieur, comme moyen de rémédier a l'ankylose vraie ou fausse de la machoire inférieure. Arch Gen Med. 1860; 15:174.
- 2- Campbell WC. Interposition of vitallium plates in arthroplasties of knee: preliminary report. Am J Surg. 1940; 47:639.
- 3- MacIntosh DL. Hemiarthroplasty of the knee using a space occupying prosthesis for painful varus deformities. J Bone Joint Surg Am. 1958; 40:1431.
- 4- McKeever DC. Tibial plateau prosthesis. Clin Orthop Relat Res. 1960; (18):86-95.
- 5- Mulvey TJ, Thornhill TS. Infected total knee arthroplasty. In: Insall JN. Surgery of the knee. New York: Churchill Livingstone; 2001. p. 1875-913.
- 6- Morrey BF, Westholm F, Schoifet S, Rand JA, Bryan RS. Long-term results of various treatment options for infected total knee arthroplasty. Clin Orthop Relat Res. 1989; (248):120-8.
- 7- Ayers DC, Dennis DA, Johanson NA, Pellegrini VD Jr. Common complications of total knee arthroplasty. J Bone Joint Surg Am. 1977; 79:278-311.
- 8- Segawa H, Tsukayama DT, Kyle RF, Becker DA, Gustilo RB. Infection after total knee arthroplasty. A retrospective study of the treatment of eighty-one infections. J Bone Joint Surg Am. 1999; 81:1434-45.
- 9- Schoifet SD, Morrey BF. Treatment of infection after total knee arthroplasty by débridement with retention of the components. J Bone Joint Surg Am. 1990; 72:1383-90.
- 10- Windsor RE, Insall JN, Urs WK, Miller DV, Brause BD. Two-stage reimplantation for the salvage of total knee arthroplasty complicated by infection. Further follow-up and refinement of indications. J Bone Joint Surg Am. 1990; 72:272-8.
- 11- Segreti J, Nelson JA, Trenholme GM. Prolonged suppressive antibiotic therapy for infected orthopedic prostheses. Clin Infect Dis. 1998; 27:711-3.
- 12- Mont MA, Waldman B, Banerjee C, Pacheco IH, Hungerford DS. Multiple irrigation, débridement, and retention of components in infected total knee arthroplasty. J Arthroplasty. 1997; 12:426-33.
- 13- VanRyn JS, Verebelyi DM. One-Stage débridement and knee fusion for infected total knee arthroplasty using the hybrid frame. J Arthroplasty. 2002; 17:129-34.
- 14- Waldman BJ, Mont MA, Payman KR, Windsor RE, Hungerford DS. Infected total knee arthroplasty treated with arthrodesis using a modular nail. Clin Orthop Relat Res. 1999; (367):230-7.
- 15- Brandt CM, Sistrunk WW, Duffy MC, Hanssen AD, Steckelberg JM, Ilstrup DM, et al. Staphylococcus aureus prosthetic joint infection treated with débridement and prosthesis retention. Clin Infect Dis. 1997; 24:914-9.
- 16- Tattévin P, Cremieux AC, Pottier P, Hutten D, Carbon C. Prosthetic joint infection: when can prosthesis salvage be considered? Clin Infect Dis. 1999; 29:292-5.
- 17- Teeny SM, Dorr L, Murata G, Conaty P. Treatment of infected total knee arthroplasty. Irrigation and débridement versus two-stage reimplantation. J Arthroplasty. 1990; 5:35-9.
- 18- Goksan SB, Freeman MAR. One-Stage reimplantation for infected total knee Arthroplasty. J Bone Joint Surg Br. 1992; 74:78-82.
- 19- Peersman G, Laskin R, Davis J, Peterson M. Infection in total knee replacement: a retrospective review of 6489 total knee replacements. Clin Orthop Relat Res. 2001; (392):15-23.
- 20- Insall JN, Thompson FM, Brause BD. Two-staged reimplantation for salvage of infected total knee arthroplasty. J Bone Joint Surg Am. 1983; 65:1087-98.
- 21- Windsor RE, Insall JN, Urs WK, Miller DV, Brause BD. Two-staged reimplantation for the salvage of total knee arthroplasty complicated by infection. J Bone Joint Surg Am. 1990; 72:272-8.