

Article - Human and Animal Health

Assessment of the Toxicological Effects of Pesticides and Detergent Mixtures on Zebrafish Gills: a Histological Study

Thamyris Santos-Silva¹

<https://orcid.org/0000-0001-5129-5695>

Rosy Iara Maciel de Azambuja Ribeiro²

<https://orcid.org/0000-0002-7374-4743>

Stênio Nunes Alves (*In Memoriam*)³

<https://orcid.org/0000-0002-4103-2266>

Ralph Gruppi Thomé¹

<https://orcid.org/0000-0002-1779-5036>

Hélio Batista dos Santos^{1*}

<https://orcid.org/0000-0001-6813-8522>

¹Federal University of São João Del Rei, Campus Centro Oeste, Tissue Processing Laboratory - LAPROTEC, Divinópolis, Minas Gerais, Brazil; ²Federal University of São João Del Rei, Campus Centro Oeste, Laboratory of Experimental Pathology - LAPATEX, Divinópolis, Minas Gerais, Brazil. ³Federal University of São João Del Rei, Campus Centro Oeste. Laboratory of Insect Vectors of Disease, Divinópolis, Minas Gerais, Brazil.

Editor-in-Chief: Alexandre Rasi Aoki
Associate Editor: Marcelo Vicari

Received: 2021.03.30; Accepted: 2021.05.25.

*Correspondence: hbsantos@ufsj.edu.br (H.B.S.).

HIGHLIGHTS

- Adaptive changes found in gills are caused by Temephos, Roundup and SDS.
- Cellular and vascular changes in gills exposed to Roundup.
- Hyperplasia of secondary lamellae was observed in all exposed groups.

Abstract: Pesticides, as Temephos and Roundup, and surfactants, like Sodium Dodecyl Sulfate (SDS), when discharged into the environment, are harmful to non-target wildlife, especially fish. To evaluate the effects of those chemicals alone and their binary combinations, we assessed the histological alterations in *Danio rerio* gills after 15 days of exposure to Temephos (1ppm), Roundup (10ppm), SDS (2ppm), SDS plus Temephos (2ppm+1ppm), SDS plus Roundup (2ppm+10ppm) and Temephos plus Roundup (1ppm+10ppm). Hyperplasia, a regressive change, was significant in all exposed groups. The progressive change, complete fusion of lamellae, was significantly intensive in Roundup plus Temephos group. Regarding circulatory disturbances, vascular congestion was significant intensive in SDS group, while severe aneurysm was observed in Roundup group. Although xenobiotics in the blend are biologically complex, mainly for long periods, combinatorial exposure incremented only complete fusion of lamellae. Our results reinforce the rationalization of indiscriminate use of those compounds alone or in combination.

Keywords: fish gills; lamellar fusion; pesticides; circulatory disturbances; surfactants.

INTRODUCTION

Pesticides are chemicals widely used in agriculture for the control of pests, such as insects and weeds. Despite their impact on productivity and economy, when misused, these agents can contaminate soil and water [1-2]. Since most formulations still applied in crops are not specific for pests, their compounds can directly or indirectly affect the structure and biological function of non-target organisms, such as amphibians and fish [3-4].

Among the most reported pesticides worldwide are organophosphate insecticides and herbicides. Within the first group, Temephos is classified as a slight toxic product by the United States Environmental Protection Agency (US EPA). It is absorbed by inhalation, ingestion or skin contact [5]. Temephos inhibits the enzyme acetylcholinesterase (AChE) in central and peripheral nervous systems, leading to accumulation of acetylcholine, causing death by respiratory depression [6]. The relatively low cost, easy manipulation and safe storage in tropical climates make Temephos an attractive pesticide for programs of insect control [8]. In Brazil, the agrochemical still has been used to control disease vectors, such as *Aedes aegypti* [9].

Regarding the herbicides, Roundup is water-soluble glyphosate and has been used in agriculture to control plagues. It is classified by the US EPA as a moderate acute toxic compound [10]. Roundup is a competitive inhibitor of the enzyme 5-enolpyruvyl-shikimate-3-phosphate synthase, which participates in the synthesis of essential aromatic amino acids in plants [11]. Contrary to this classification, there are several non-targets for glyphosates, notably marine species [12-14].

Anionic surfactants are the most important surfactant used in cleaning products and commercial formulation of pesticide to reduce surface tension and improve surface spreading. They are commonly released in the environment, polluting sewage, and presenting potential toxicity to water, soil and biota [15]. Sodium Dodecyl Sulfate (SDS) is an anionic detergent applied for industrial purposes to household cleaning products [16]. Considered safe for humans, SDS has equally important toxic effects in aquatic organisms [17-20].

Fish represent a population commonly affected by these agents, which are found as residues contaminating domestic and industrial sewage, inadequately discharged in aquatic ecosystems [21]. Aquatic organisms are exposed simultaneously to a mixture of pesticides since in agriculture practices it is common the application of more than one pesticide and subsequently, they are discharged into the environment at the same time [22-23]. Therefore, Temephos, Roundup and SDS may interact among themselves and lead to different reactions, which can include additive, synergistic or antagonistic effects. *Danio rerio*, also known as zebrafish, is a freshwater fish widely used to evaluate toxicity since it is sensitive to pollutants. Morphological and behavioral alterations found in zebrafish exposed to pesticides are good biomarkers for evaluating environmental conditions and water quality [13, 24-25].

Gills are organs exposed to these contaminants and are responsible for hematosmosis, osmoregulation and nutrient uptake [26]. These organs are extensively vascularized, with a large surface area covered by squamous epithelium in direct contact with water [27]. The morphological adaptive modifications in gills follow exposure to these agents represents a set of pathological alterations, which are commonly used as parameters to evaluate toxicological studies, water quality and environmental impacts related to human activities [21, 28-30]. Histological alterations may be classified according to their reaction patterns, which include different types of morphological changes. A typical progressive change is a hyperplasia, consisting of tissue enlargement caused by cell growth, but without variations in cellular volume. Regressive changes (epithelial lifting atrophy and necrosis) are more severe and can impair the proper function of organs. Circulatory disturbances consist of blood and interstitial fluid imbalances, including blood congestion, aneurysm and hemorrhage [21, 26].

Temephos, Roundup and SDS have been evaluated separately, but aquatic organisms are exposed to diverse xenobiotics at the same time. Superficial and subaquatic contaminants reach the environment concomitantly and hence their effects upon non-target organisms could superimpose [23]. Thus, this study was investigating and quantifying the histological progressive, regressive changes and circulatory disturbances in gills of *D. rerio* exposed to Temephos, Roundup, SDS and their binary combinations.

MATERIAL AND METHODS

Zebrafish care

The 28 adult *D. rerio* specimens were purchased locally from a commercial fish store. Animals were acclimated for one week, distributed in seven 3 L glass aquaria filled with tap water from COPASA (Sanitation

Department of the State of Minas Gerais) ($n = 4$ fish per tank). The low density per aquarium had as the goal provide the welfare to animals during the experiment as described for the zebrafish maintaining [31]. Water dechlorinated was previously treated with a conditioner called the Prime® from Seachem Laboratories that was used to eliminate the chlorine, chloramine, and ammonia. During the experiment, water was maintained at 26 °C, constant oxygenation, pH = 6.8, controlled photoperiod (14/10 h) and fish were fed twice a day with commercial food from Alcon Basic®. All procedures were performed following the ethical principles established by Animal Use Ethics Committee, Federal University of São João del-Rei, protocol 23/2012. Animal handling and laboratory procedures were conducted according to the Guidance on the housing and care of zebrafish [31].

Experimental design

Temephos 1G® concentration used was based on the guidelines of the National Dengue Control Program in Brazil [5]. Roundup Original® (Monsanto) the concentration was chosen due to the upper limit of glyphosate (3.7 ppm) accepted for water bodies with no intercepting vegetation [32]. SDS (High purity) concentration used was based on average values found in industrial and domestic sewage from Southeast and South regions from Brazil [33-34].

After acclimation, each group was exposed to: Temephos 1 ppm; Roundup 10 ppm; SDS 2 ppm; SDS plus Temephos (2 ppm + 1 ppm); SDS plus Roundup (2 ppm + 10 ppm); Temephos plus Roundup (1 ppm + 10 ppm); control group. The experiment was carried out for 15 days in the static system according to Toledo-Ibarra and coauthors, (2018) [35]. During the experiment, there was no dead fish.

Histology

After treatments, all animals were euthanized with a lethal dose of benzocaine (50 mg L⁻¹). Gills were collected and fixed in Bouin's liquid for 24 h. Samples were submitted to routine histological techniques, embedded in paraffin, and sections 6 µm thickness were stained with hematoxylin-eosin (H&E) as described in Sales and coauthors (2017) [21].

Morphometry

Morphometry was performed for all slides, counting 12 gill filaments per sample. Filaments were photographed using light microscopy (Zeiss Primo Star) (20X magnification) that was coupled with Axiovision 4.8 software. After histological analyses, an occurrence score was established to rank the lesions that were identified in gills from treatment groups, according to Albinati and coauthors (2009) [36]: 0 - alteration not observed; 1 - discrete (up to two occurrences); 2 - moderate (three to five occurrences); 3 - severe (more than five occurrences). These occurrence scores were used to calculate the median score of histological changes for each group, which were classified as discrete (0 to 1.0), moderate (1.1 to 2.0) or severe (2.1 to 3.0).

Statistical analysis

The Kolmogorov–Smirnov test was used to assess the normality of data and then, the data were analyzed by non-parametric Kruskal-Wallis test followed by the Dunn's post-hoc test. Values were expressed as median and (interquartile range). Statistical significance was assumed for $p < 0.05$. Graphs were plotted in a box and whisker chart with min and max values. All tests were performed using Graph Pad Prisma, version 5.00 (Graph Pad Software, San Diego, CA, USA).

RESULTS

Histological changes in exposed gills

Gills from the control group displayed a typical histological architecture (Figure 1A). The primary lamellae (PL) presented normal squamous epithelium with several cell types, such as mucous cells and mitochondria-rich cells. Hyaline cartilage sustaining PL and a central venous sinus were recorded. Secondary lamellae (SL) were supported by pillar cells and covered with simple squamous epithelium and supported by pillar cells.

Progressive, regressive changes and circulatory disturbances were observed in all gills exposed to treatments (Figure 1B – F). Progressive changes as hyperplasia of secondary lamellae (HSL) were found on SL in all treated groups. Epithelial lifting (EL), a regressive change was also detected (Fig. 1B), as well

incomplete fusion of secondary lamellae (IFL) and complete fusion of secondary lamellae (CFL) (Figure 1F). Circulatory disturbances characterized by vascular congestion (VC) in the central venous sinus (Figure 1E and F) and aneurysm (AN) (Figure 1D) were also present in all exposed groups. In addition, regions of necrosis mainly in secondary lamellae (Figure 1C) and hemorrhage (Figure 1D) were also identified for all treatments, at least in one animal. Table 1 summarizes the classification of histological changes in gills of *D. rerio* exposed to Temephos, Roundup, SDS alone and their combinations.

Morphometric analysis

After histological analysis exploratory from gills, the following parameters were chosen and measured in the experimental groups: epithelial lifting (EL), hyperplasia of secondary lamellae (HSL), incomplete fusion of secondary lamellae (IFL), complete fusion of secondary lamellae (CFL), vascular congestion (VC), and aneurysm (AN).

Progressive changes

All exposed gills displayed HSL (Figure 2), with a median of 0.5 (1.0). Animals exposed to Temephos, Roundup, SDS, Temephos plus SDS and Roundup plus SDS presented maxima median scores of 3.0 (0.0), indicating severe alterations. For Temephos plus Roundup, the observed score was 2.5 (1.0). When compared to control, all median scores for treatments were significantly higher, indicating an association between HSL and exposure to tested xenobiotics.

Regressive changes

For all exposed groups, no differences between mean scores of EL and IFL were found, when compared to control (data not shown). Only animals exposed to Temephos + Roundup presented a significant higher median score for CFL (3.0 (2.0)), when compared to control (0.0 (1.0)) (Figure 3). Temephos and Roundup groups had median CFL scores of 1.0 (1.0) and 2.5 (2.0), respectively. In those groups, CFL was classified as severe. Gills exposed to the SDS presented a discrete CFL (1.5 (1.0)). SDS + Temephos also displayed discrete median CFL score (1.0 (1.0)), whereas SDS + Roundup group had a moderate median score for CFL (2.0 (0.0)). Despite this trend, the combination of SDS with pesticides showed no significant differences in CFL mean scores when compared to control.

Circulatory disturbances

Moderate VC was visualized in gills exposed to Temephos, Roundup, SDS plus Temephos and SDS plus Roundup (1.5 (1.0); 2.0 (2.0); 2.0 (0.0); 2.0 (0.0), respectively). Temephos plus Roundup group also displayed moderate VC (2.0 (0.0)). Severe VC was observed only for SDS (2.0 (1.0)), a median score significantly higher than control (1.0 (1.0)) (Figure 4A). AN in control had a median score of 0.0 (1.0) (Figure 4B). Roundup displayed a median score (3.0 (1.0)) classified as severe, significantly higher than control. Despite the moderate-to-discrete mean AN scores for all other groups (Temephos, 1.0 (3.0); SDS, 1.0 (0.0); SDS plus Temephos, 2.0 (0.0); SDS + Roundup, 2.0 (0.0)); Temephos plus Roundup, 1.0 (1.0)), no statistical differences were found when comparing them to control.

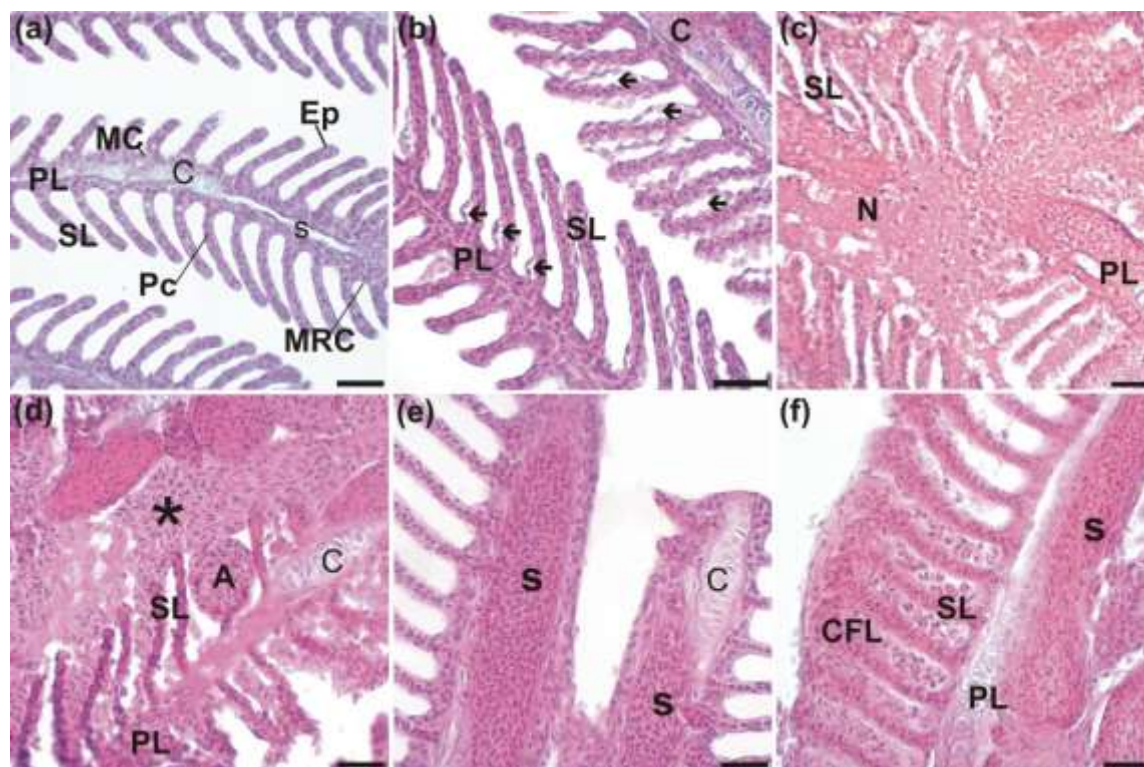


Figure 1. Histological sections of gills from zebrafish stained with Hematoxylin and Eosin (H&E). (a) control group showed gills with normal histological architecture. PL primary lamellae; SL = secondary lamellae; C = hyaline cartilage; S = central venous sinus; MC = mucous cell; Pc = pillar cell; Ep = squamous epithelial cell; MRC = mitochondria-rich cell. (b) in all treated groups epithelial lifting = arrow was observed. (c) necrotic area = N in at least one fish from the treated groups; (d) fish treated with SDS plus Roundup showed hemorrhagic area = (*) and aneurysm = A. (e) fish submitted to Roundup with vascular congestion in central venous sinus = S. (f) fish treated with Temephos plus Roundup showed complete fusion of lamellae = CFL. Bars = 50µm.

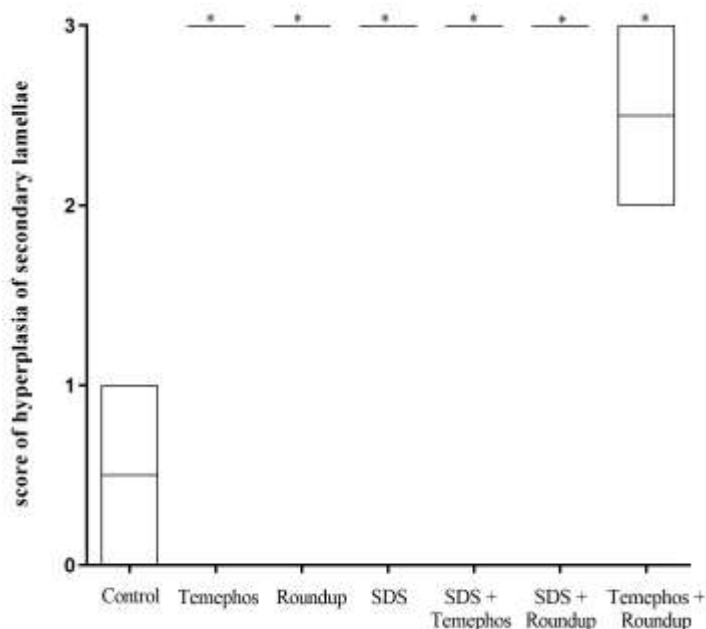


Figure 2. Score of hyperplasia in zebrafish gills. Median score of secondary lamellae hyperplasia observed in gills of zebrafish exposed to Temephos, Roundup, SDS and their combinations. Box represents the median and interquartile range. Bars represent min and max values (n=4). * indicated significant differences compared with control group (Kruskal-Wallis test followed by Dunn's test; $p < 0.05$).

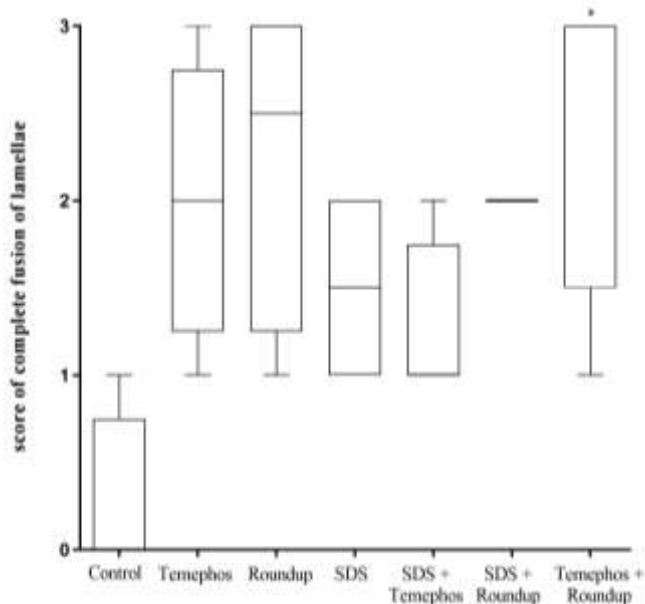


Figure 3. Score of complete fusion of lamellae in zebrafish gills. Median score of complete fusion of some lamellae means score observed in zebrafish gills exposed to Temephos, Roundup, SDS and their combinations. Box represents the median and interquartile range. Bars represent min and max values (n=4). * indicated significant differences compared with control group (Kruskal-Wallis test followed by Dunn's test; $p < 0.05$).

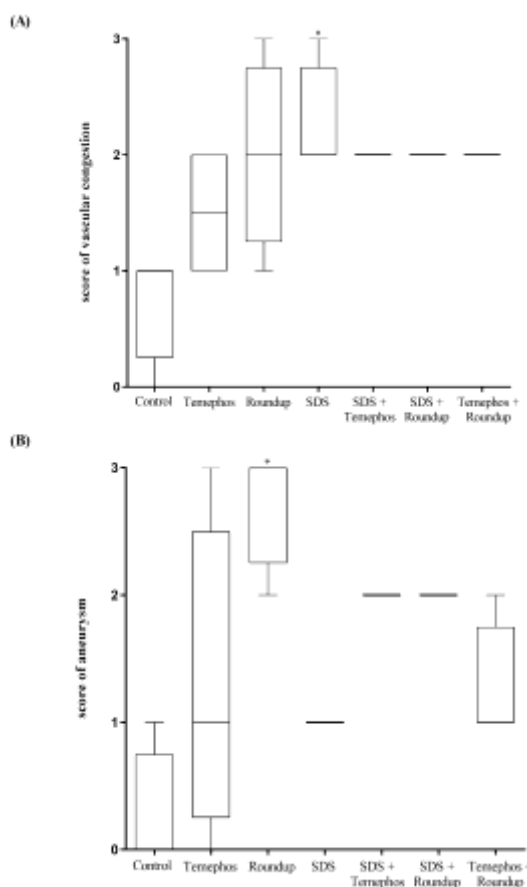


Figure 4. Score of circulatory disturbances in zebrafish gills. Median score of vascular congestion (a) and aneurysm (b) observed in zebrafish gills exposed to Temephos, Roundup, SDS and their combinations. Box represents the median and interquartile range. Bars represent min and max values (n=4). * indicated significant differences compared with control group (Kruskal-Wallis test followed by Dunn's test; $p < 0.05$).

Table 1. Classification of histological changes in zebrafish gills exposed to Temephos, Roundup, SDS and their combinations. HSL = hyperplasia of secondary lamellae; CFL = complete fusion of secondary lamellae; VC = vascular congestion; AN = Aneurysm.

Group	Progressive	Regressive	Circulatory disturbances	
	HSL	CFL	VC	AN
Control	Discrete	Discrete	Discrete	Discrete
Temephos	Severe	Moderate	Moderate	Moderate
Roundup	Severe	Severe	Moderate	Severe
SDS	Severe	Moderate	Severe	Discrete
SDS + Temephos	Severe	Moderate	Moderate	Moderate
SDS + Roundup	Severe	Moderate	Moderate	Moderate
Temephos + Roundup	Severe	Severe	Moderate	Moderate

DISCUSSION

Histological changes in gills have been described in wild fish [21] or during acute exposure to pesticides under controlled conditions since these organs are extremely exposed to the environment and serve as an entrance for contaminants [25]. Organophosphates, such as Temephos, were developed to kill target parasites, without any damage to the host and other non-target organisms in the environment, where the insecticide is dispersed. However, undesirable effects on non-target organisms have been reported in varying degrees for Temephos [37]. Pathological findings associated with Temephos exposure are not exclusive to gills but also found in the liver, muscles, and nerve tissue [7, 19, 38-39]. Moreover, organophosphates also can induce morphological and biochemical abnormalities in exposed amphibians [40-41].

In this study, hyperplasia of secondary lamellae (HSL) was the most striking alteration found in zebrafish gills exposed to Temephos. Moderate occurrences of complete fusion of lamellae (CFL) and circulatory disturbances were visualized, but no significant differences were observed when compared to control group. Epithelium lifting (EPL), HSL and lamellar fusion are defence responses induced by Temephos. Probably, to prevent the diffusion of Temephos through gills, HSL led to lamellar fusion. As result of stress response, reduction of gill surface area decreases the oxygen availability and increases the diffusion distance of external environment and vascular system [7]. Indeed, the teleost *Anphanius dispar*, when exposed to Temephos, also developed degeneration of gill tissues, such as supporting cartilage, epithelial hypertrophy, decrease of mitochondria-rich cells and EPL [7]. The same histological alterations also were found in *Oreochromis niloticus* when exposed to other organophosphates as trichlorfon and fention [38-39].

Temephos inhibits the enzymatic activity of acetylcholinesterase (AChE), a key enzyme involved in hydrolysis of the neurotransmitter acetylcholine. In gills, the physiological role of AChE includes cell mechanisms to control the epithelium gills activity and the filtration capacity [42]. Inhibition of AChE by xenobiotics results in accumulation of acetylcholine and leads to paralysis of respiratory muscles, and subsequently compromises gill functions [43]. Interestingly, histopathological alterations found in gills were directly correlated with the inhibition of AChE follow exposure to pesticides [38, 44-46]. In addition, a continuous production of reactive oxygen species (ROS) and hence oxidative stress was reported in gills of fish exposed to different brands of organophosphates [47-48].

Cellular and vascular changes in zebrafish gills exposed to Roundup confirmed those toxic effects. A higher frequency of HSL and CFL were found in gills exposed to Roundup. Circulatory disturbances were also present, and a significantly higher occurrence of aneurysm (AN) was found in comparison with control group, but vascular congestion (VC) was classified as moderate, without significant difference when compared to control group. The AN have pathological importance, considering that they are usually irreversible and can progress to hemorrhage if the environmental conditions are not altered [21]. Acute exposure to Roundup (96 h) also causes oxidative stress and DNA damage in gills of *Corbicula fluminea* [23]. The toxic effects of Roundup on gill cells were also demonstrated for different fish species and diverse concentrations of the xenobiotic [36, 4-50]. Moreover, Roundup can also lead to histopathological alterations in distinct fish organs, such as brain, skin, liver and kidney [14, 36, 49]. Among the wide variety of non-target species, amphibians are particularly sensitive to environmental exposure of glyphosates [3].

Glyphosates, as Roundup, target the enzyme EPSP, which interrupts the synthesis of aromatic amino acids in plants. Although this pathway is not present in animals, several studies have shown that aquatic organisms are susceptible to glyphosate effects, mainly by oxidative stress and AChE alterations. When biotransformed, the compound alters the oxidative balance of zebrafish gills. In this sense, Temephos and Roundup induce production of ROS and reduces gill redox buffering capacity and tissue damage [23, 51-53].

Furthermore, genotoxic effects of glyphosates have already reported in fish [23, 54]. Interestingly, inhibition of AChE is also a possible mechanism of action observed in herbicides [12, 53-54].

Here, treatment with SDS appeared to cause HSL and VC in zebrafish gills. Regarding the latter, intravenous sinus congestion is an injury that leads to functional damage, being classified as reversible, in case of improvement in water quality, or progressive, in cases of persistent exposure [21, 36]. Similar results were reported in gills from *Scophthalmus maximus L* exposed to SDS [15] and in *Astyanax altiparanae* and *Prochilodus lineatus* submitted to biodegradable detergents [45].

The toxic effects of SDS in fish are correlated with the reduction of surface tension, leading to less oxygen dissolved in water and gas absorption by gills [15]. Moreover, anionic surfactant can bind into proteins, DNA or into cell fragments, which led to disturbances in cell function. This capability of SDS to enter in cell membranes and to bind in cell fragments can also increase generation of reactive species of oxygen, which cause tissue damage [17]. Regarding AChE inhibition, evidence suggests that SDS have not significantly effect on the *in vivo* enzymatic activity of exposed fish [55-58], whereas SDS exposure was responsible for *in vitro* inhibitory effects in exposed fish organs and in sensitive aquatic organisms [55, 59-60].

Anionic surfactants, such as SDS, are added to commercial formulation of pesticides to enhance their diffusion through plants. Cuhra and cols (2013) suggested that the toxic effects of Roundup may be derived from synergistic effects of glyphosate and adjuvants [61]. In contrast, Bridi and cols (2017) demonstrated that there are small differences in morphological and behavioral parameters of zebrafish exposed to glyphosate and Roundup formulation [13]. Indeed, active ingredients of pesticides, commercial formulation of pesticides and detergents are extremely harmful to aquatic organisms. Since fish are exposed to diverse xenobiotics at the same time, we aimed to evaluate the combinatorial effects of Temephos, Roundup and SDS, based on concentrations observed in the natural environment. Therefore, the binary combinations of these agents represent the superficial and subaquatic contaminants that reach the environment concomitantly.

Considering the combinatorial effects of Temephos plus SDS, Roundup plus SDS and Temephos plus Roundup, the most common alteration observed were HSL. Although moderate circulatory disturbances were observed in all associations, this parameter was not significantly different when compared to control group. Associated groups displayed widespread areas of hemorrhage with necrosis that was observed in at least one animal per exposed group. Hemorrhage is the blood escaping from the circulatory system from damaged blood vessels, whereas necrosis has been characterized by disruption of plasma membrane, release of cytoplasmic material and intense inflammatory reaction [62]. In agreement with these results, necrosis, hemorrhage, and inflammatory infiltrate were also observed in gills exposed to SDS or Roundup [15, 49]. Necrosis epithelial was also observed in secondary lamellae from *Cirrhinus mrigala* exposed to 0.91 ppm and 1.82 ppm concentrations of dichlorvos, an organophosphate pesticide, for 10 days treatment [63].

These histopathological parameters describe in *D. rerio* gills after exposure to Temephos Roundup, SDS and their combination have been used widely in several research fields as biomarker tools in environmental monitoring [21, 45]. In this study, we aimed to identify individual alterations in the gills of exposed fish since animals were acquired from the same cohort and share strong similarity among themselves. We observed a strong effect of our treatments and low variability since severe effects were found in gills exposed to pesticides, detergent, and their combinations.

All substances used in this study are stable in aqueous solution longer than the time taken to complete the experiment. For example, Temephos is stable for 28 days at pH = 7.0 (without hydrolysis), whereas 50 % of glyphosate degrades between 14 and 22 days [64-66]. Regarding the SDS stability, it has been analyzed for up to 10 days and remained stable for this period [67 - 71]. Interestingly, Pettersson and cols (2000) showed that detergents were detoxified to some extent 16 days in *Daphia magna* [70], i.e., the physiological removal of toxic detergents from a living organism was longer than the time taken to complete this study. It is also important to mention that very lower SDS concentration (0.0025 ± 300 mg/l) leads to toxic effects in aquatic organisms [70]. Therefore, even with a low rate of SDS degradation, the remaining amount of SDS concentration is enough to cause toxic effects in *D. rerio* gills during 15 days of exposition.

Maybe the reduction of the exposure period could be necessary for a better assessment of combinatorial effects of tested compounds, as well the use of lower concentrations, to adequately identify synergistic interaction of pesticides and surfactants in mixture. In fact, the big current issue is that the behavior of chemicals in a mixture may not correspond to that predicted from data on pure compounds. This occurs due to interactions between the components, which can cause complex and substantial changes in the properties of their constituents [72]. The contaminants with a similar or different mode of action can influence each other's toxicity; resulting in an almost unlimited number of possible additive, synergistic or antagonistic

combinations [73]. This phenomenon is known as the cocktail effect. Notably, Santos and Martinez (2014) observed antagonistic effects for the co-administration of atrazine, an herbicide, and Roundup, when evaluating biotransformation and oxidative stress [23]. On the other hand, a more in-dept analysis must be performed for better identification of potential antagonist effects in gills exposed to combinations of Temephos, Roundup and SDS.

CONCLUSION

In conclusion, adaptive changes found in zebrafish gills that are caused by Temephos, Roundup and SDS, alone or in combination, reflect the toxic effects of these agents. Considering that interactions between xenobiotics present in a given mixture are biologically complex, especially for long exposure periods, no significant increment in the incidence of histological alterations was observed when comparing associations to single treatments. However, it is important to note that concentrations of Temephos, Roundup and SDS used here were based on environmental findings. Our results reinforce the need for a more rational and controlled use and disposal of herbicides and surfactants since their persistent presence as environmental contaminants appears to be deleterious to non-target organisms such as fish.

Funding: This research was funded by FAPEMIG, grant number CVZ-APQ-03548- 16 and by CNPq, grant number (process 405822/2016-2).

Acknowledgments: We would also like to thank the Tissue Processing Laboratory (LAPROTEC) for the equipment, materials and support for research.

Conflicts of Interest: The authors declare no conflict of interest.

REFERENCES

- Li Z. A health-based regulatory chain framework to evaluate international pesticide groundwater regulations integrating soil and drinking water standards. *Environ Int.* 2018; 121(2):1–26.
- Woodrow JE, Gibson KA, Seiber JN. Pesticides and Related Toxicants in the Atmosphere. *Rev Environ Contam Toxicol.* 2019;247:147-96.
- Annett R, Habibi HR, Hontela A. Impact of glyphosate and glyphosate-based herbicides on the freshwater environment. *J Appl Toxicol.* 2014; 34(5):458–79.
- Corbett PA, King CK, Stark JS, Mondon JA. Direct evidence of histopathological impacts of wastewater discharge on resident Antarctic fish (*Trematomus bernacchii*) at Davis Station, East Antarctica. *Mar Pollut Bull.* 2014;87(1):48–56.
- Fersol. Temefós 1G - Ficha de Informações de Segurança de Produto Químico. 2010; (2):1–9.
- Aiub CAF, Coelho ECA, Sodr e E, Pinto LFR, Felzenszwalb. Genotoxic evaluation of the organophosphorous pesticide temephos. *Genet Mol Res.* 2002; 1(2):159–66.
- Ba-Omar TA, Al-Jardani S, Victor R. Effects of pesticide temephos on the gills of *Aphanius dispar* (Pisces: Cyprinodontidae). *Tissue Cell.* 2011; 43(1):29–38.
- Edward JB, Sogbesan OA. Toxicity Effect of Temephos on *Bulinus globosus* and *Lymnaea natalensis*. *Adv Biol Res (Rennes).* 2007; 1(3–4):130–3.
- Valle D, Bellinato DF, Viana-Medeiros PF, Lima JBP, Martins Junior ADJ. Resistance to temephos and deltamethrin in *Aedes aegypti* from Brazil between 1985 and 2017. *Mem Inst Oswaldo Cruz.* 2019; 114(3):1–17.
- MONSANTO. Roundup. Ficha de Informações de Segurança de Produto Químico. 2014; 1–17.
- Steinrücken HC, Amrhein N. The herbicide glyphosate is a potent inhibitor of 5-enolpyruvylshikimic acid-3-phosphate synthase. *Biochem Biophys Res Commun.* 1980; 94(4):1207–12.
- 12-Sancho E, Cerón JJ, Ferrando MD. Cholinesterase activity and hematological parameters as biomarkers of sublethal molinate exposure in *Anguilla anguilla*. *Ecotoxicol Environ Saf.* 2000; 46(1):81–6.
- Bridi D, Altenhofen S, Gonzalez JB, Reolon GK, Bonan CD. Glyphosate and Roundup® alter morphology and behavior in zebrafish. *Toxicology.* 2017; 392(October):32–9.
- Rodrigues L de B, de Oliveira R, Abe FR, Brito LB, Moura DS, Valadares MC, et al. Ecotoxicological assessment of glyphosate-based herbicides: Effects on different organisms. *Environ Toxicol Chem.* 2017; 36(7):1755–63.
- Rosety-Rodríguez M, Ordoñez FJ, Rosety M, Rosety JM, Rosety I, Ribelles A, et al. Morpho-histochemical changes in the gills of turbot, *Scophthalmus maximus* L., induced by Sodium Dodecyl Sulfate. *Ecotoxicol Environ Saf.* 2002; 51(3):223–8.
- Rowe R, Sheskey P, Quinn M. Handbook of Pharmaceutical Excipients. *Handb Pharm excipients, Sixth Ed.:*2009; 549–53.

17. Messina CM, Faggio C, Laudicella VA, Sanfilippo M, Trischitta F, Santulli A. Effect of sodium dodecyl sulfate (SDS) on stress response in the Mediterranean mussel (*Mytilus Galloprovincialis*): Regulatory volume decrease (Rvd) and modulation of biochemical markers related to oxidative stress. *Aquat Toxicol.* 2014; 157:94–100.
18. Rodrigues S, Correia AT, Antunes SC, Nunes B. Alterations in gills of *Lepomis gibbosus*, after acute exposure to several xenobiotics (pesticide, detergent and pharmaceuticals): Morphometric and biochemical evaluation. *Drug Chem Toxicol.* 2015; 38(2):126–32.
19. Dos Santos HB, Vieira L, Alves SN, Thomé RG. Análise do intestino delgado de *Danio rerio* exposto a organofosforado e detergente: um estudo histológico e morfométrico. *Rev Conex Ciência.* 2016; 11(2):51–8.
20. Sayed AEH, Authman MMN. Ecotoxicology and Environmental Safety Modulatory effects of green tea extract against the hepatotoxic effects of 4-nonylphenol in cat fish *Clarias gariepinus* (Burchell, 1822). *Ecotoxicol Environ Saf.* 2018; 149(October):136–44.
21. Sales CF, dos Santos KPE, Rizzo E, de Azambuja Ribeiro RLM, dos Santos HB, Thomé RG. Proliferation, survival and cell death in fish gills remodeling: From injury to recovery. *Fish Shellfish Immunol.* 2017; 68:10–8.
22. Van den Brink PJ, Hartgers EM, Gylstra R, Bransen F, Brock TCM. Effects of a mixture of two insecticides in freshwater microcosms: II. Responses of plankton and ecological risk assessment. *Ecotoxicology.* 2002; 11(3):181–97.
23. Dos Santos KC, Martinez CBR. Genotoxic and biochemical effects of atrazine and Roundup®, alone and in combination, on the Asian clam *Corbicula fluminea*. *Ecotoxicol Environ Saf.* 2014;100(1):7–14.
24. Schmidel AJ, Assmann KL, Werlang CC, Bertocello KT, Francescon F, Rambo CL, et al. Subchronic atrazine exposure changes defensive behaviour profile and disrupts brain acetylcholinesterase activity of zebrafish. *Neurotoxicol Teratol.* 2014; 44:62–9.
25. Macirella R, Brunelli E. Morphofunctional alterations in zebrafish (*Danio rerio*) gills after exposure to mercury chloride. *Int J Mol Sci.* 2017; 18(4):1–19.
26. Bernet D, Schmidt H, Meier W, Burkhardt-Holm P, Wahli T. Histopathology in fish: proposal for a protocol to assess aquatic pollution. *J Fish Dis.* 1999; 22(1):25–34.
27. Winkaler EU, Silva ADG, Galindo HC, Martinez CBR. Biomarcadores histológicos e fisiológicos para o monitoramento da saúde de peixes de ribeirões de Londrina, Estado do Paraná. *Acta Sci Biol Sci.* 2008;23(2):507–14.
28. Oliveira SE, Costa PM, Nascimento SB, Castro WV, de Azambuja Ribeiro RIM, Santos HB, et al. Atrazine promotes immunomodulation by melanomacrophage centre alterations in spleen and vascular disorders in gills from *Oreochromis niloticus*. *Aquatic toxicology.* 2018; 202, 57-64.
29. Macêdo AKS, Dos Santos KPE, Brighenti LS, Windmüller CC, Barbosa FAR, Ribeiro RIMA, et al. Histological and molecular changes in gill and liver of fish (*Astyanax lacustris* Lütken, 1875) exposed to water from the Doce basin after the rupture of a mining tailings dam in Mariana, MG, Brazil. 2020; *Sci Total Environ*, 139505.
30. Muthukumaravel K, Vasanthi N, Stalin A, Alam L, Santhanabharathi B, Musthafa MS. Sublethal effects of phenol on histology of selected organs of freshwater fish *Mystus vittatus*. *Environ Sci Pollut Res.* 2020; 1-9.
31. Reed B, Jennings M. Guidance on the housing and care of Zebrafish *Danio rerio*. *Res Anim Dep Sci Group, RSPCA.* 2011; (May):1–27.
32. Do Carmo Langiano V, Martinez CBR. Toxicity and effects of a glyphosate-based herbicide on the Neotropical fish *Prochilodus lineatus*. *Comp Biochem Physiol - C Toxicol Pharmacol.* 2008; 147(2):222–31.
33. Vicente J. Determinação de surfactantes aniônicos em efluentes de postos revendedores de combustíveis da região da Grande Florianópolis. Universidade Federal de Santa Catarina. 2004.
34. Bohn FP. Tratamento do efluente gerado na lavagem de veículos.: Universidade Regional do Noroeste do Estado do Rio Grande do Sul.2014.
35. Toledo-Ibarra GA, Rodríguez-Sánchez EJ, Ventura-Ramón HG, Díaz-Resendiz KJG, Girón-Pérez MI. Cholinergic alterations by exposure to pesticides used in control vector: Guppies fish (*Poecilia reticulata*) as biological model. *Int J Environ Health Res.* 2018; 28(1): 79-89.
36. Albinati ACL, Moreira ELT, Albinati RCB, Carvalho JV, de Lira AD, Santos GB, Vidal LVO. Biomarcadores histológicos: toxicidade crônica pelo Roundup em piauçu (*Leporinus macrocephalus*). *Arq Bras Med Veterinária e Zootec.* 2009; 61(3):621–7.
37. Sarikaya R, Yilmaz M. Investigation of acute toxicity and the effect of 2,4-D (2,4-dichlorophenoxyacetic acid) herbicide on the behavior of the common carp (*Cyprinus carpio* L., 1758; Pisces, Cyprinidae). *Chemosphere.* 2003; 52(1):195–201.
38. Guimarães ATB, Silva de Assis HC, Boeger W. The effect of trichlorfon on acetylcholinesterase activity and histopathology of cultivated fish *Oreochromis niloticus*. *Ecotoxicol Environ Saf.* 2007; 68(1):57–62.

39. Jayasundara VK, Pathiratne A. Effect of repeated application of fenthion as a mosquito larvicide on Nile tilapia (*Oreochromis niloticus*) inhabiting selected water canals in Sri Lanka. *Bull Environ Contam Toxicol*. 2008;80(4):374–7.
40. Ma Y, Li B, Ke Y, Zhang YH. Effects of low doses Trichlorfon exposure on *Rana chensinensis* tadpoles. *Environ Toxicol*. 2019; 34(1):30–6.
41. Rutkoski CF, Macagnan N, Folador A, Skovronski VJ, do Amaral AMB, Leitemperger J, et al. Morphological and biochemical traits and mortality in *Physalaemus gracilis* (Anura: Leptodactylidae) tadpoles exposed to the insecticide chlorpyrifos. *Chemosphere*. 2020; 250:126162.
42. Corsi I, Pastore AM, Lodde A, Palmerini E, Castagnolo L, Focardi S. Potential role of cholinesterases in the invasive capacity of the freshwater bivalve, *Anodonta woodiana* (Bivalvia: Unionacea): A comparative study with the indigenous species of the genus, *Anodonta* sp. *Comp Biochem Physiol-C Toxicol Pharmacol*. 2007;145(3):413–9.
43. Cappello T, Maisano M, Giannetto A, Parrino V, Mauceri A, Fasulo S. Neurotoxicological effects on marine mussel *Mytilus galloprovincialis* caged at petrochemical contaminated areas (eastern Sicily, Italy): 1H NMR and immunohistochemical assays. *Comp Biochem Physiol Part - C Toxicol Pharmacol*. 2015; 169:7–15.
44. Jindal R, Kaur M. Acetylcholinesterase inhibition and assessment of its recovery response in some organs of *Ctenopharyngodon idellus* induced by chlorpyrifos. *Int J Sci Environ Technol*. 2014; 3(2):473–80.
45. Pereira BB, De Campos EO. Enzymatic Alterations and Genotoxic Effects Produced by Sublethal Concentrations of Organophosphorous Temephos in *Poecilia reticulata*. *J Toxicol Environ Heal - Part A Curr Issues*. 2015; 78(16):1033–7.
46. Doherty VF, Ladipo MK, Aneyo IA, Adeola A, Odulele WY. Histopathological alterations, biochemical responses and acetylcholinesterase levels in *Clarias gariepinus* as biomarkers of exposure to organophosphates pesticides. *Environ Monit Assess*. 2016; 188(5):312–22.
47. Pham B, Miranda A, Allinson G, Nugegoda D. Evaluating the non-lethal effects of organophosphorous and carbamate insecticides on the yabby (*Cherax destructor*) using cholinesterase (AChE, BChE), Glutathione S-Transferase and ATPase as biomarkers. *Ecotoxicol Environ Saf*. 2017;143(January):283–8.
48. Marigoudar SR, Mohan D, Nagarjuna A, Karthikeyan P. Biomarker and histopathological responses of *Lates calcarifer* on exposure to sub lethal concentrations of chlorpyrifos. *Ecotoxicol Environ Saf*. 2018;148(June):327–35.
49. Ramírez-Duarte WF, Rondón-Barragán IS, Eslava-Mocha PR. Toxicidade aguda e alterações histopatológicas induzidas pelo herbicida Roundup® em pirapitinga (*Piaractus brachypomus*). *Pesqui Vet Bras*. 2008; 28(11):547–54.
50. Hued AC, Oberhofer S, De Los Angeles Bistoni M. Exposure to a commercial glyphosate formulation (Roundup) alters normal gill and liver histology and affects male sexual activity of *Jenynsia multidentata* (Anablepidae, cyprinodontiformes). *Arch Environ Contam Toxicol*. 2012; 62(1):107–17.
51. Menezes CC, Da Fonseca MB, Loro VL, Santi A, Cattaneo R, Clasen B, Pretto A, Morsch VM. Roundup effects on oxidative stress parameters and recovery pattern of *Rhamdia quelen*. *Arch Environ Contam Toxicol*. 2011; 60(4):665–71.
52. Velasques RR, Sandrini JZ, Da Rosa CE. Roundup® in Zebrafish: Effects on Oxidative Status and Gene Expression. *Zebrafish*. 2016; 13(5):432–41.
53. Lopes FM, Caldas SS, Primel EG, da Rosa CE. Glyphosate Adversely Affects *Danio rerio* Males: Acetylcholinesterase Modulation and Oxidative Stress. *Zebrafish*. 2017; 14(2):97–105.
54. Modesto KA, Martinez CBR. Roundup® causes oxidative stress in liver and inhibits acetylcholinesterase in muscle and brain of the fish *Prochilodus lineatus*. *Chemosphere*. 2010; 78(3):294–9.
55. Nunes B, Carvalho F, Guilhermino L. Characterization and use of the total head soluble cholinesterases from mosquitofish (*Gambusia holbrooki*) for screening of anticholinesterase activity. *J Enzyme Inhib Med Chem*. 2005; 20(4):369–76.
56. Rodrigues SR, Caldeira C, Castro BB, Gonçalves F, Nunes B, Antunes SC. Cholinesterase (ChE) inhibition in pumpkinseed (*Lepomis gibbosus*) as environmental biomarker: ChE characterization and potential neurotoxic effects of xenobiotics. *Pestic Biochem Physiol*. 2011; 99(2):181–8.
57. Ramos AS, Gonçalves F, Antunes SC, Nunes B. Cholinesterase characterization in *Corbicula fluminea* and effects of relevant environmental contaminants: A pesticide (chlorfenvinphos) and a detergent (SDS). *J Environ Sci Heal - Part B Pestic Food Contam Agric Wastes*. 2012; 47(6):512–9.
58. Nunes B, Miranda MT, Correia AT. Absence of effects of different types of detergents on the cholinesterasic activity and histological markers of mosquitofish (*Gambusia holbrooki*) after a sub-lethal chronic exposure. *Environ Sci Pollut Res*. 2016; 23(15):14937–44.

59. Guilhermino L, Lacerda MN, Nogueira AJA, Soares AMVM. In vitro and in vivo inhibition of *Daphnia magna* acetylcholinesterase by surfactant agents: Possible implications for contamination biomonitoring. *Sci Total Environ.* 2000; 247(2–3):137–41.
60. Feng T, Li ZB, Guo XQ, Guo JP. Effects of trichlorfon and sodium dodecyl sulphate on antioxidant defense system and acetylcholinesterase of *Tilapia nilotica* in vitro. *Pestic Biochem Physiol.* 2008; 92(3):107–13.
61. Cuhra M, Traavik T, Bøhn T. Clone- and age-dependent toxicity of a glyphosate commercial formulation and its active ingredient in *Daphnia magna*. *Ecotoxicology.* 2013; 22(2):251–62.
62. Rock, Kenneth L; Kono H. The Inflammatory Response to Cell Death. *Annu Rev Pathol Dis.* 2008; 3:67–97.
63. Velmurugan B, Selvanayagam M, Cengiz EI, Unlu E. Histopathological changes in the gill and liver tissues of freshwater fish, *Cirrhinus mrigala* exposed to dichlorvos. *Braz Arch Biol Technol.* 2009; 52(5):1291–6.
64. WHO, Temephos - Who Specifications And Evaluations For Public Health Pesticides. 2011, 1–44.
65. MONSANTO. Solubility, volatility, adsorption, and partition coefficients, leaching, and aquatic metabolism of MON 0573 and MON 0101. St. Louis, Missouri, Monsanto Ltd (Unpublished report No. MSL-0207), 1978.
66. PTRL Inc. Degradation study: photodegradation of [¹⁴C] glyphosate in a buffered aqueous solution at pH 5, 7, and 9 by natural sunlight. Richmond, Kentucky, Pharmacology and Toxicology Research Laboratory, Inc. (Unpublished report No. 233W-1 submitted by Monsanto Ltd), 1990.
67. Backer BP, Grant JA. Sodium Sulfate Profile Active Ingredient Eligible for Minimum Risk Pesticide Use. New York State IPM Program, 2019, 1–12.
68. Adekanmbi, AO, Usinola IM. Biodegradation of Sodium Dodecyl Sulphate (SDS) by two Bacteria Isolated from Wastewater Generated by a Detergent-Manufacturing Plant in Nigeria. *Jordan J Biol Sci.* 2017, 10(4), 251 – 5.
69. Halmi MIE, Hussin WSW, Aqlima A, Syed MA, Ruberto LAM, MacCormack WP, et al. Characterization of a sodium dodecyl sulphate-degrading *Pseudomonas* sp. strain DRY15 from Antarctic soil. 2013, 34, 1077-82.
70. Hosseini F, Malekzadeh F, Amirmozafari N, Ghaemi N. Biodegradation of anionic surfactants by isolated bacteria from activated sludge. *Int. J. Environ. Sci. Technol.* 2007, 4(1), 127-32.
71. Pettersson A, Adamsson M, Dave G. Toxicity and detoxification of Swedish detergents and softener products. *Chemosphere.* 2000, 41(10),1611-20.
72. Altenburger R, Nendza M, Schüürmann G. Mixture toxicity and its modeling by quantitative structure-activity relationships. *Environ. Toxicol. Chem: An International Journal.* 2003, 22(8), 1900-15.
73. Beyer J, Petersen K, Song Y, Ruus A, Grung M, Bakke T, et al. Environmental risk assessment of combined effects in aquatic ecotoxicology: A discussion paper. *Mar. Environ. Res.* 2014, 96, 81-91.



© 2021 by the authors. Submitted for possible open access publication under the terms and conditions of the Creative Commons Attribution (CC BY NC) license (<https://creativecommons.org/licenses/by-nc/4.0/>).